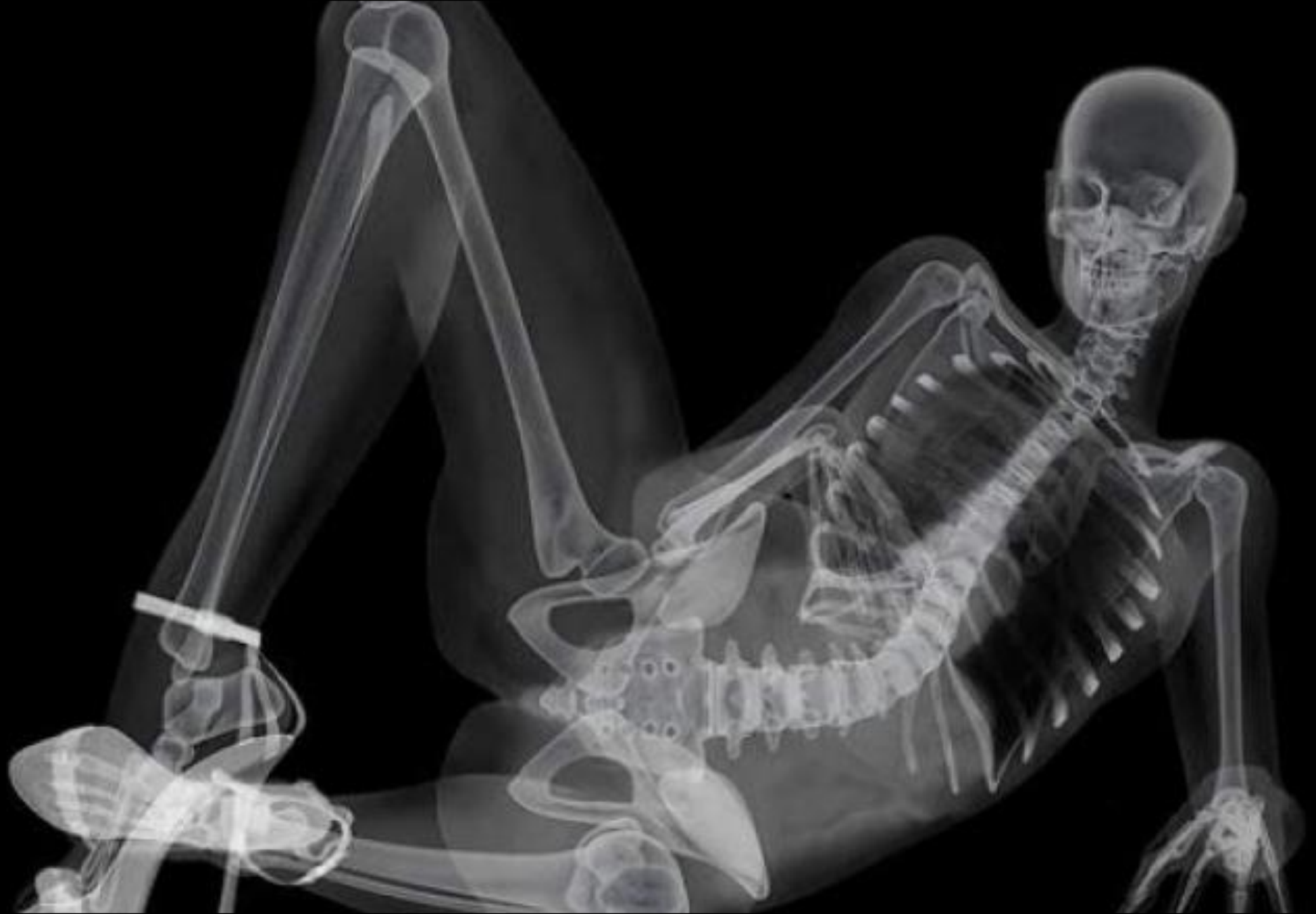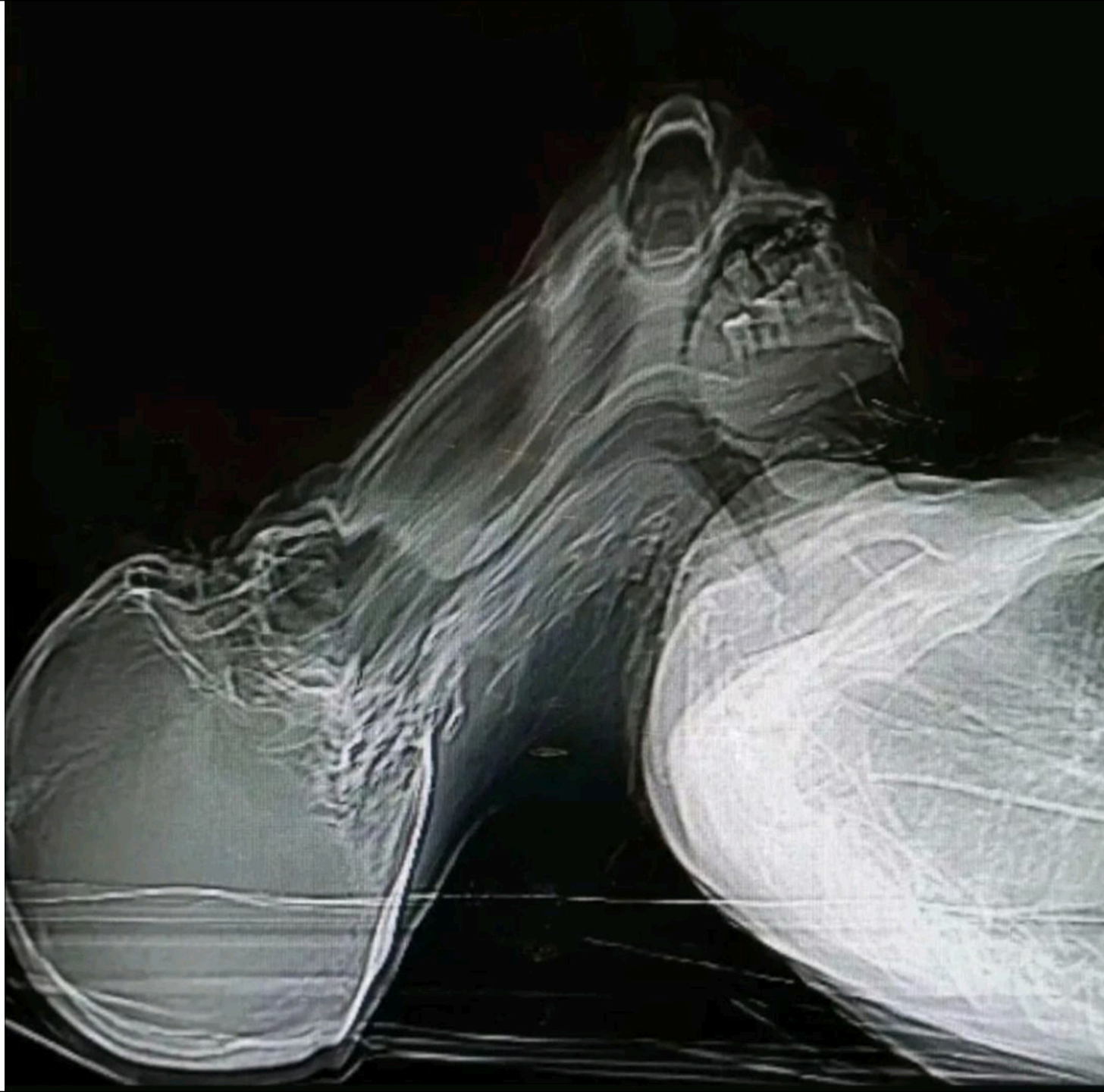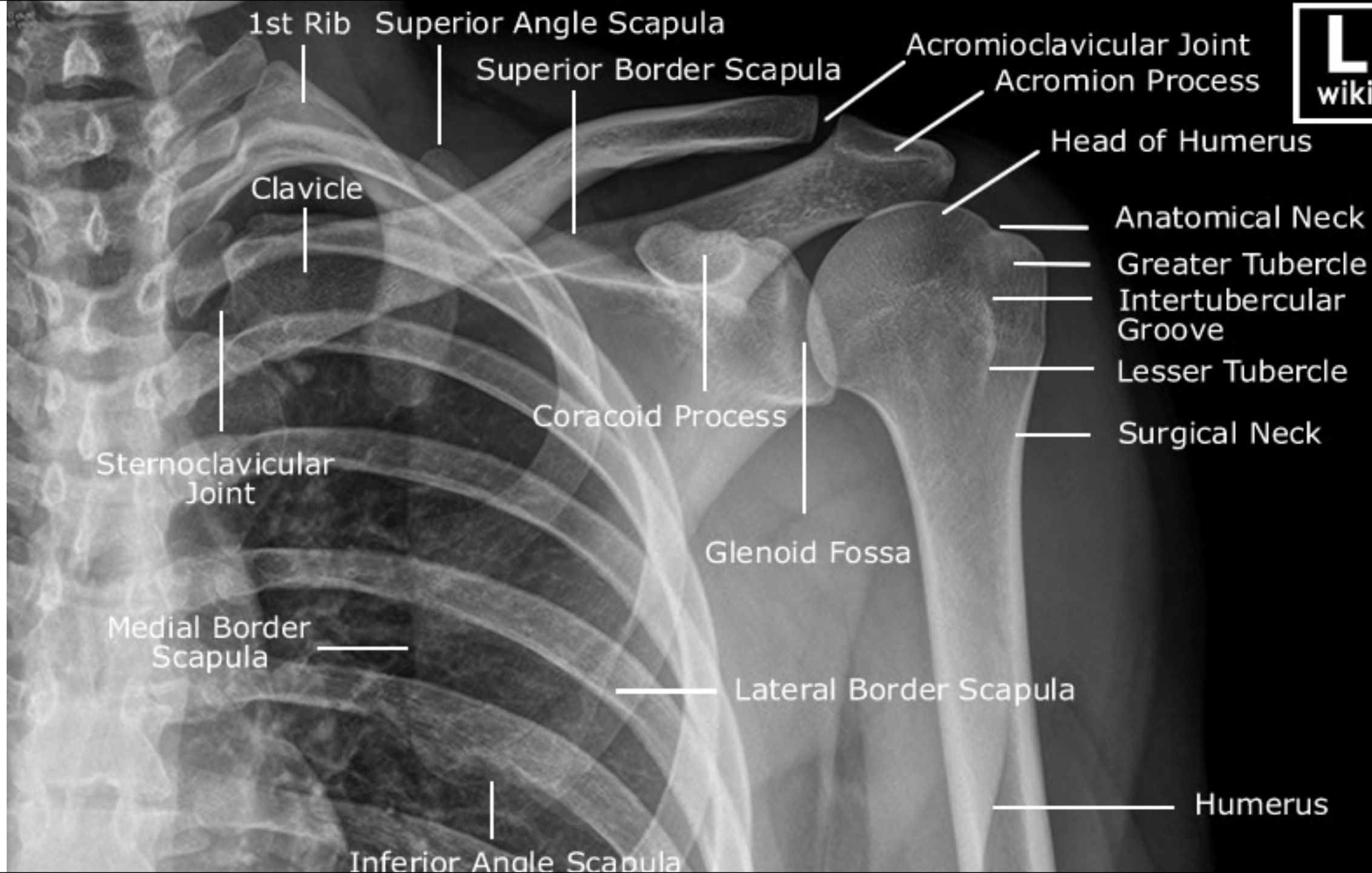
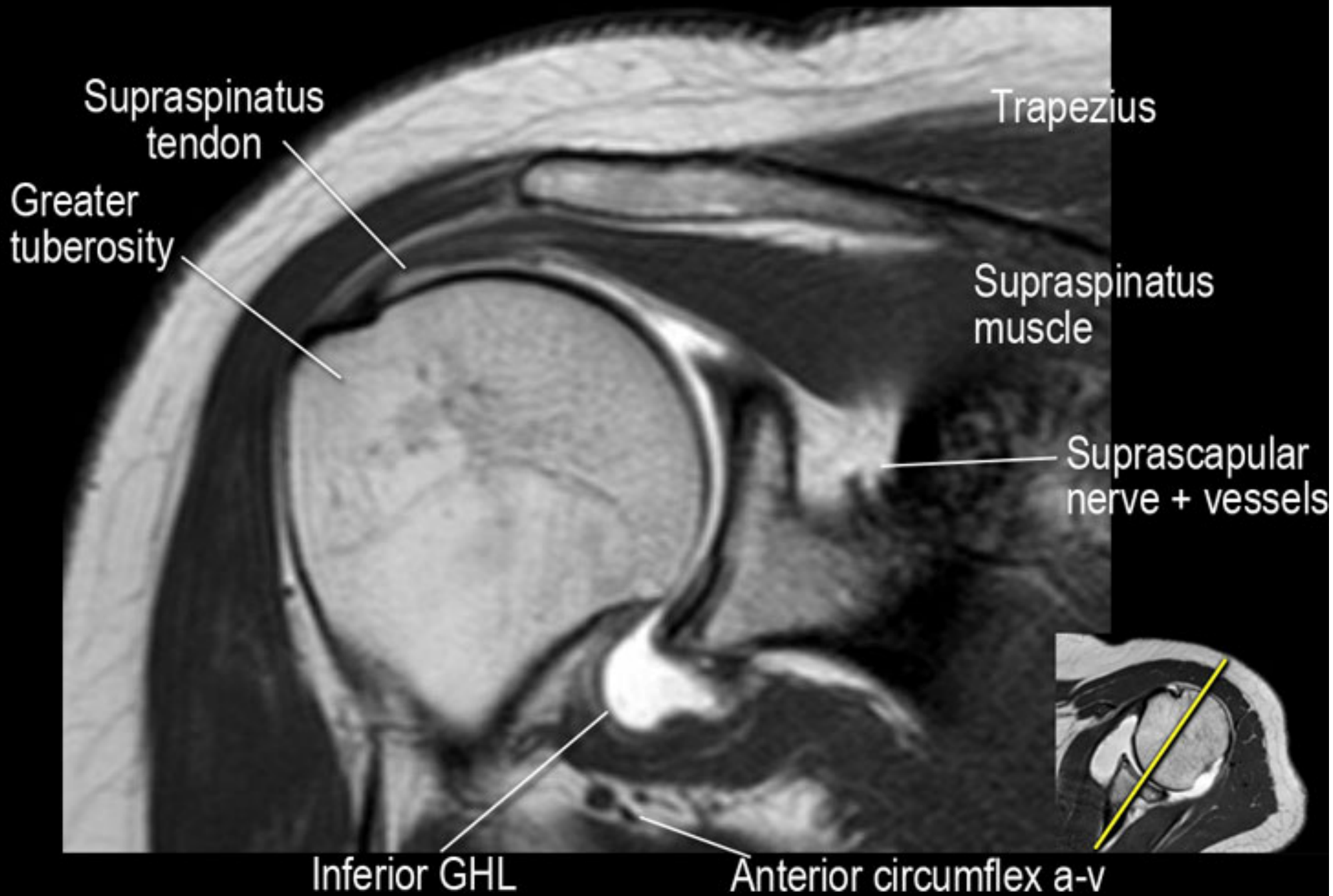


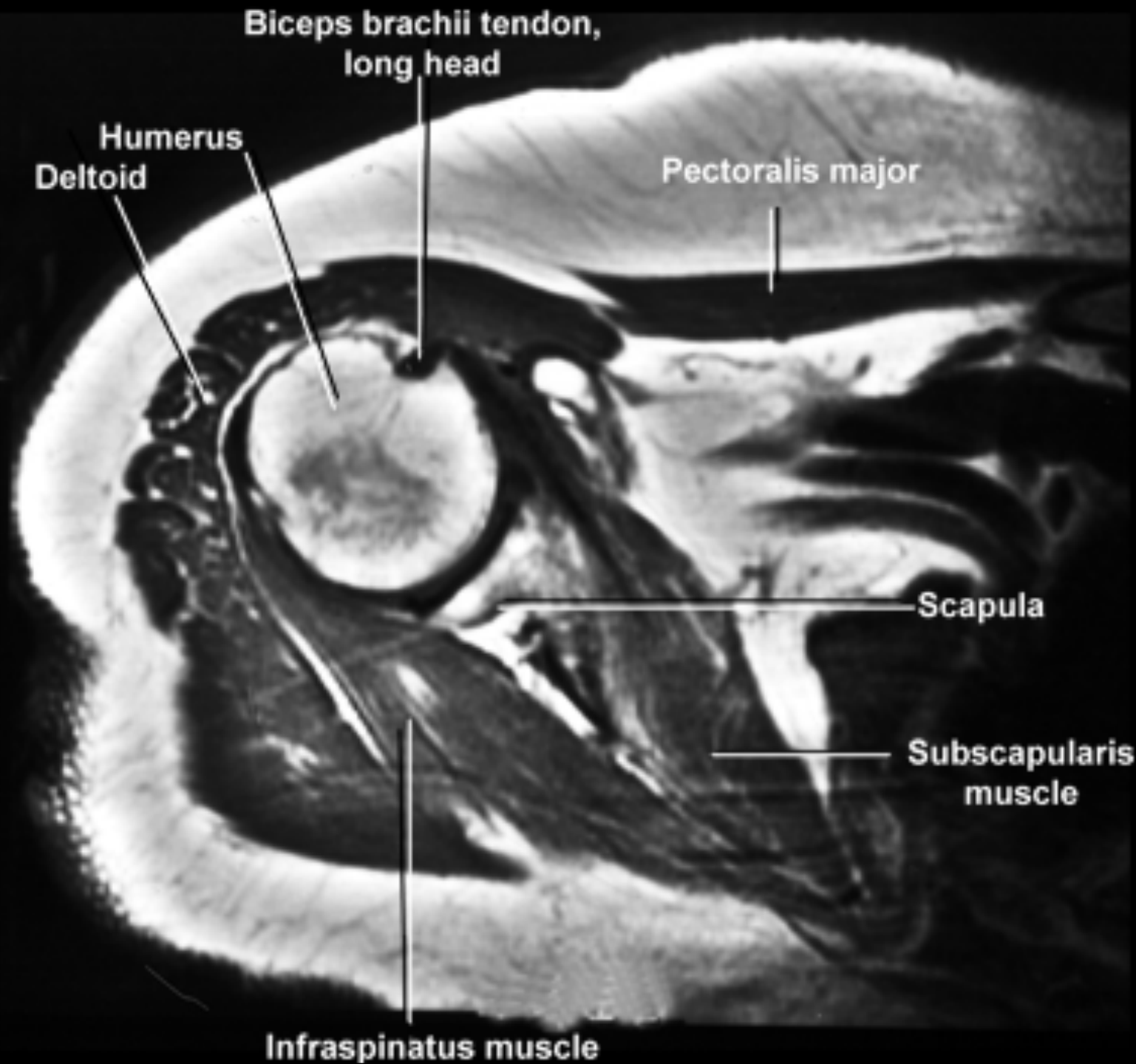
X-rays:











Biceps brachii tendon,
long head

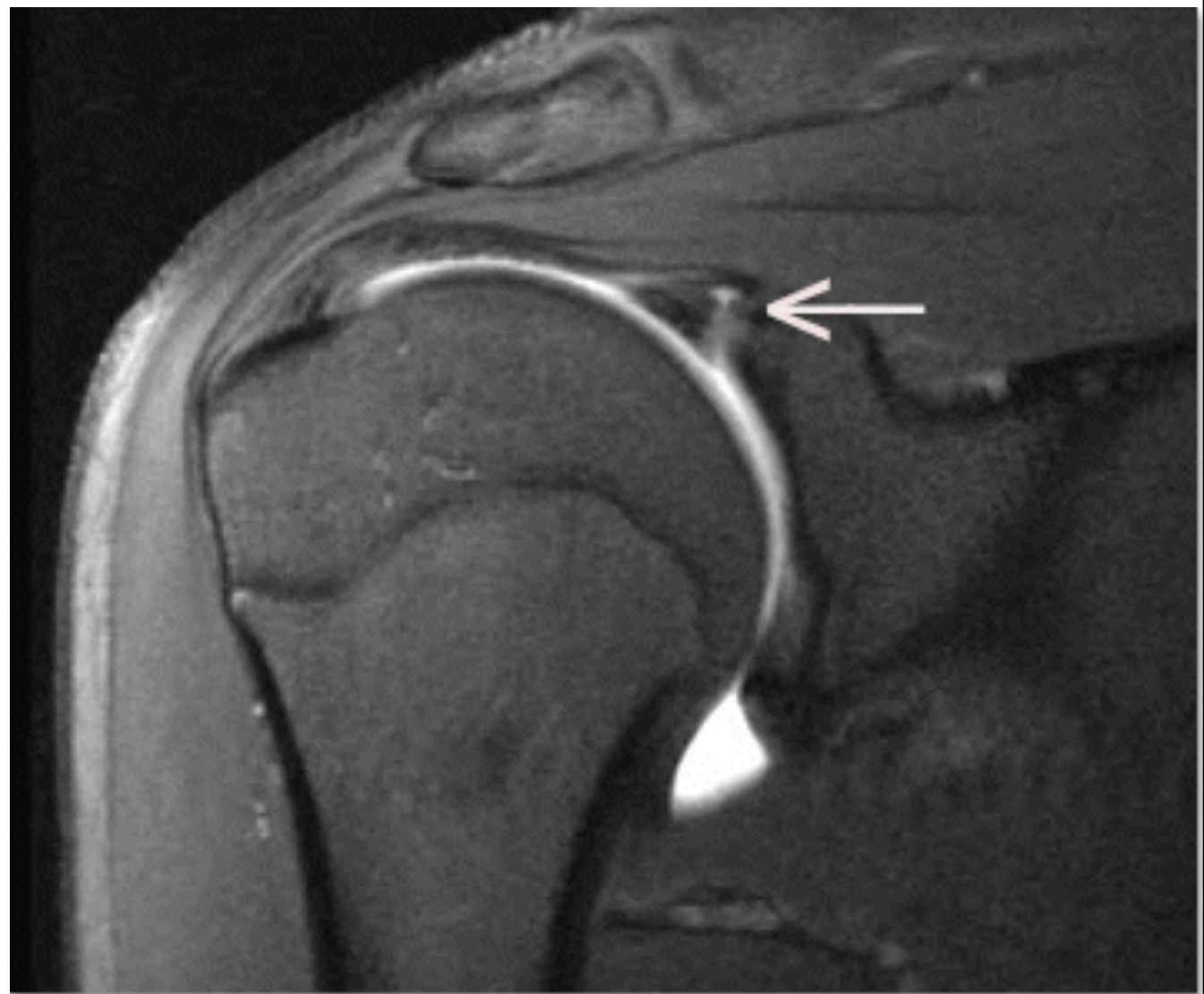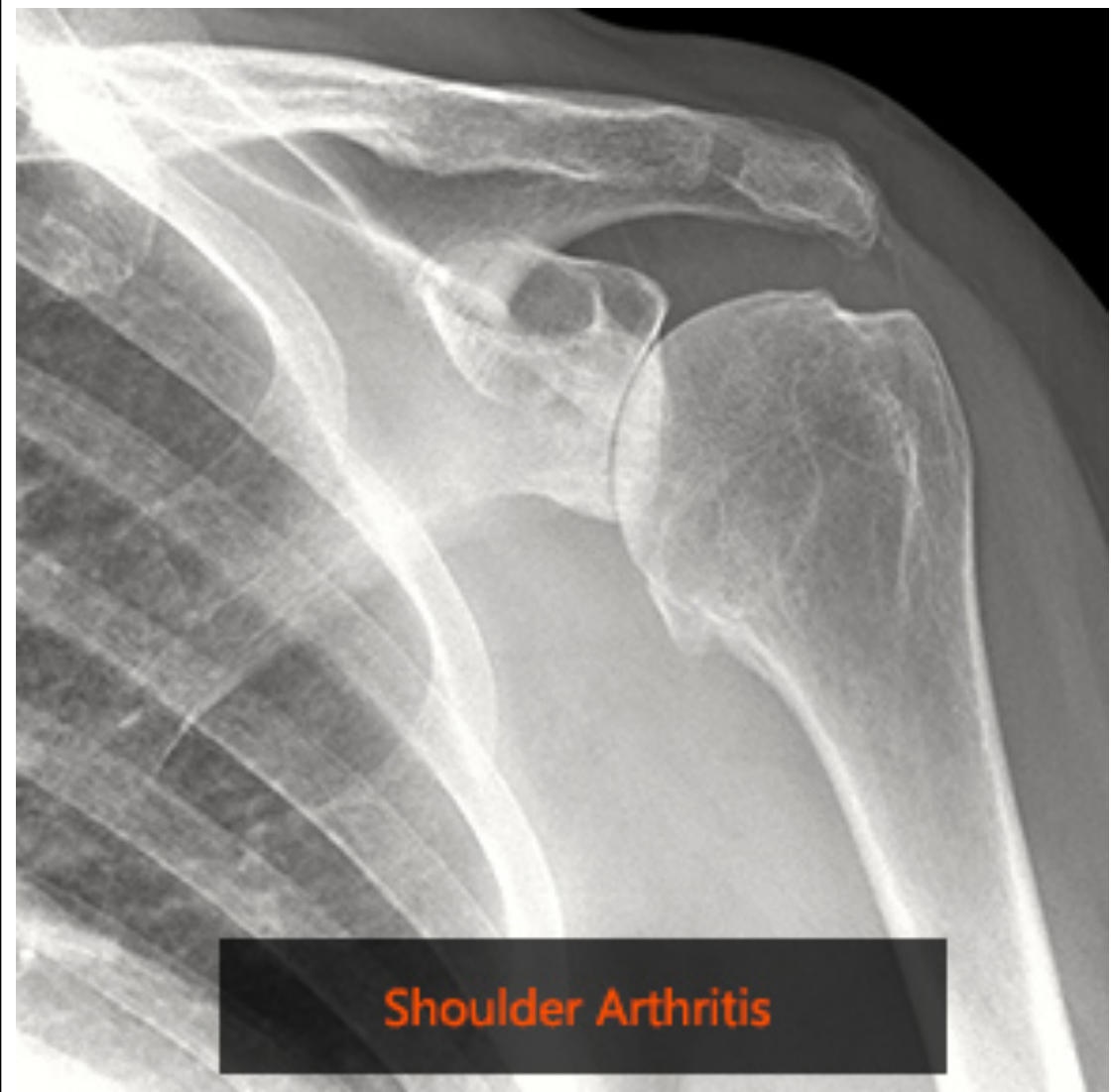Humerus
Deltoid

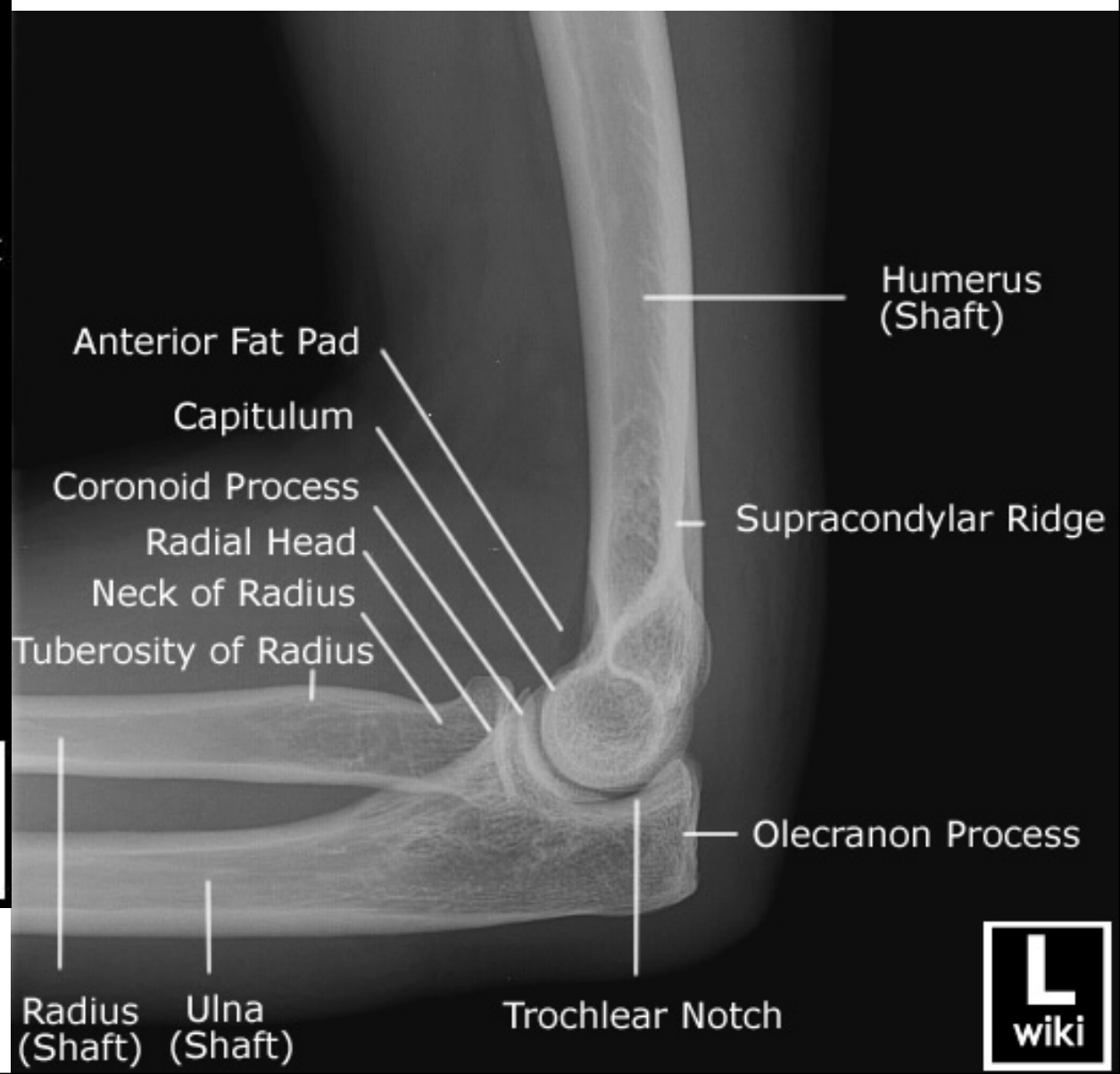
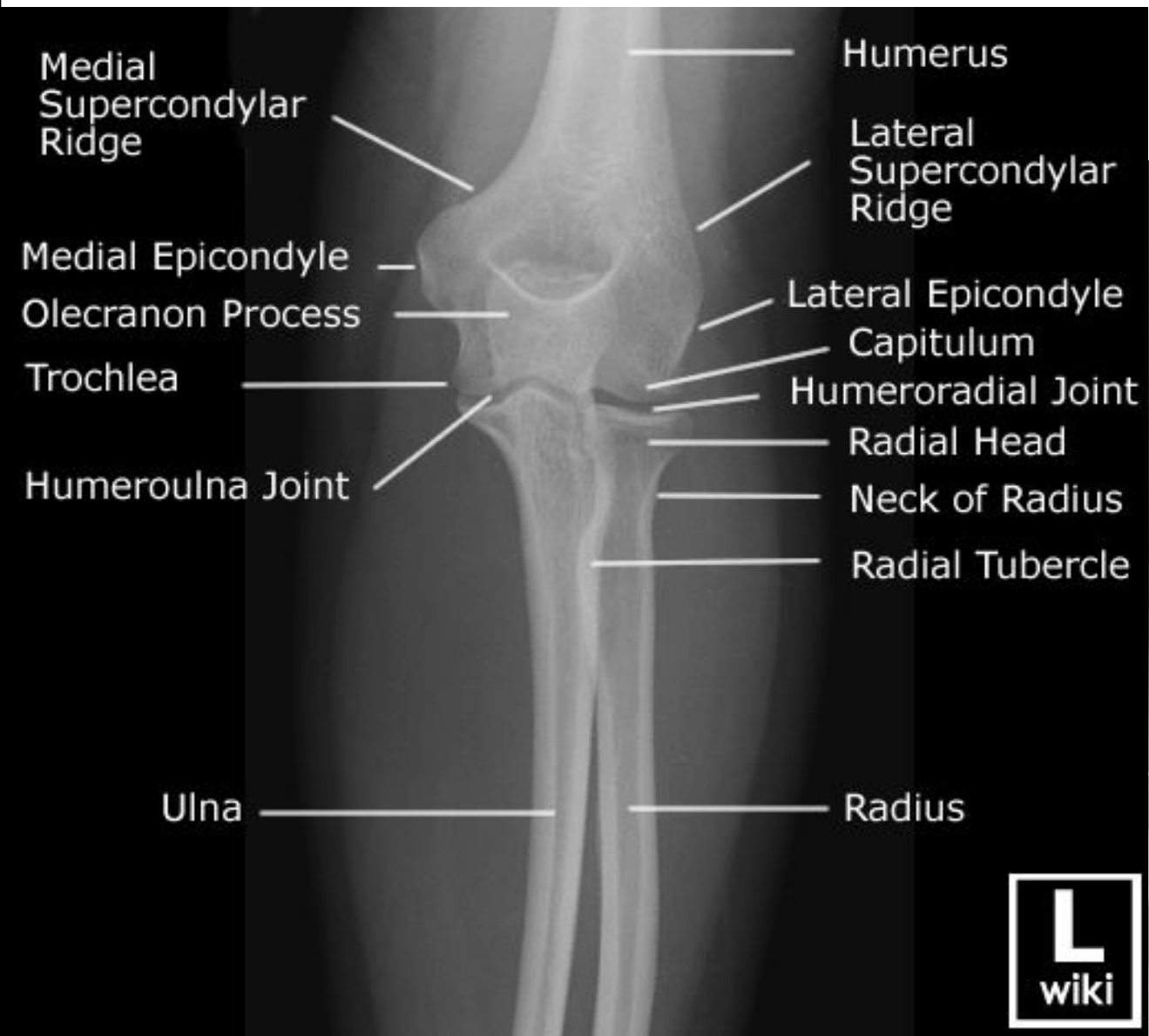
Pectoralis major

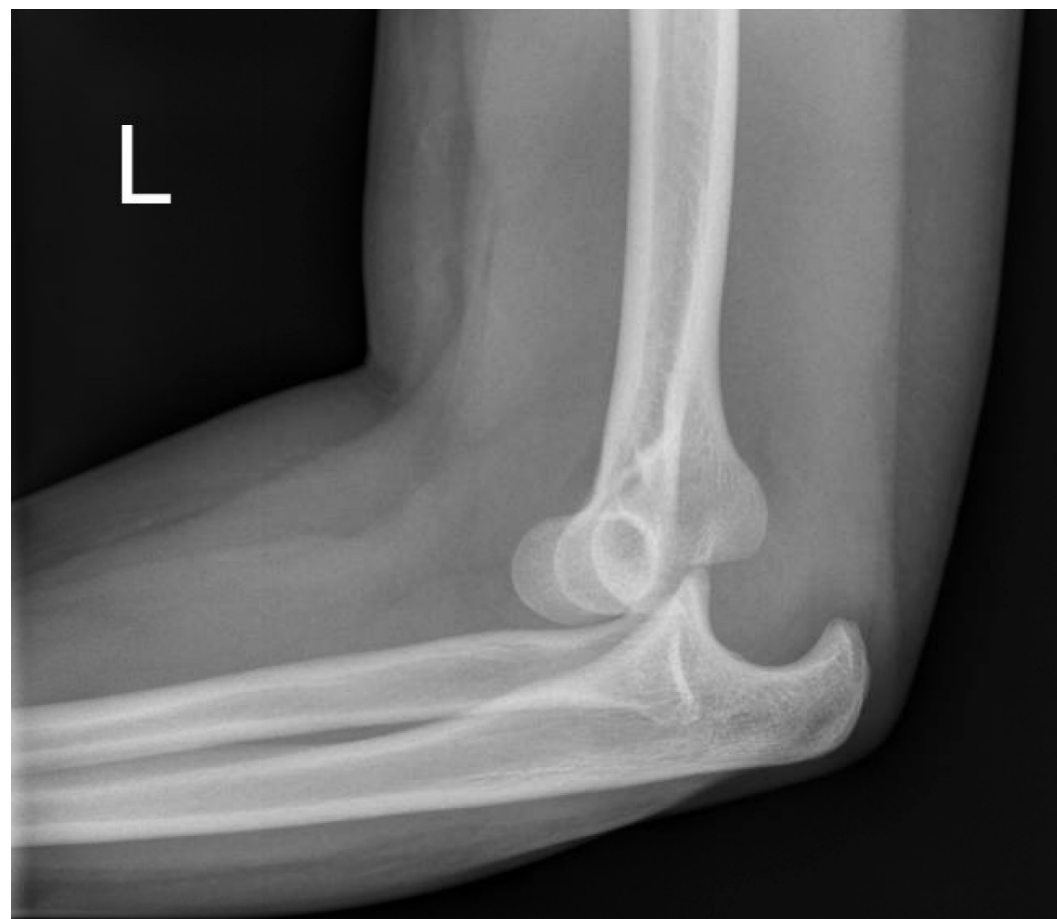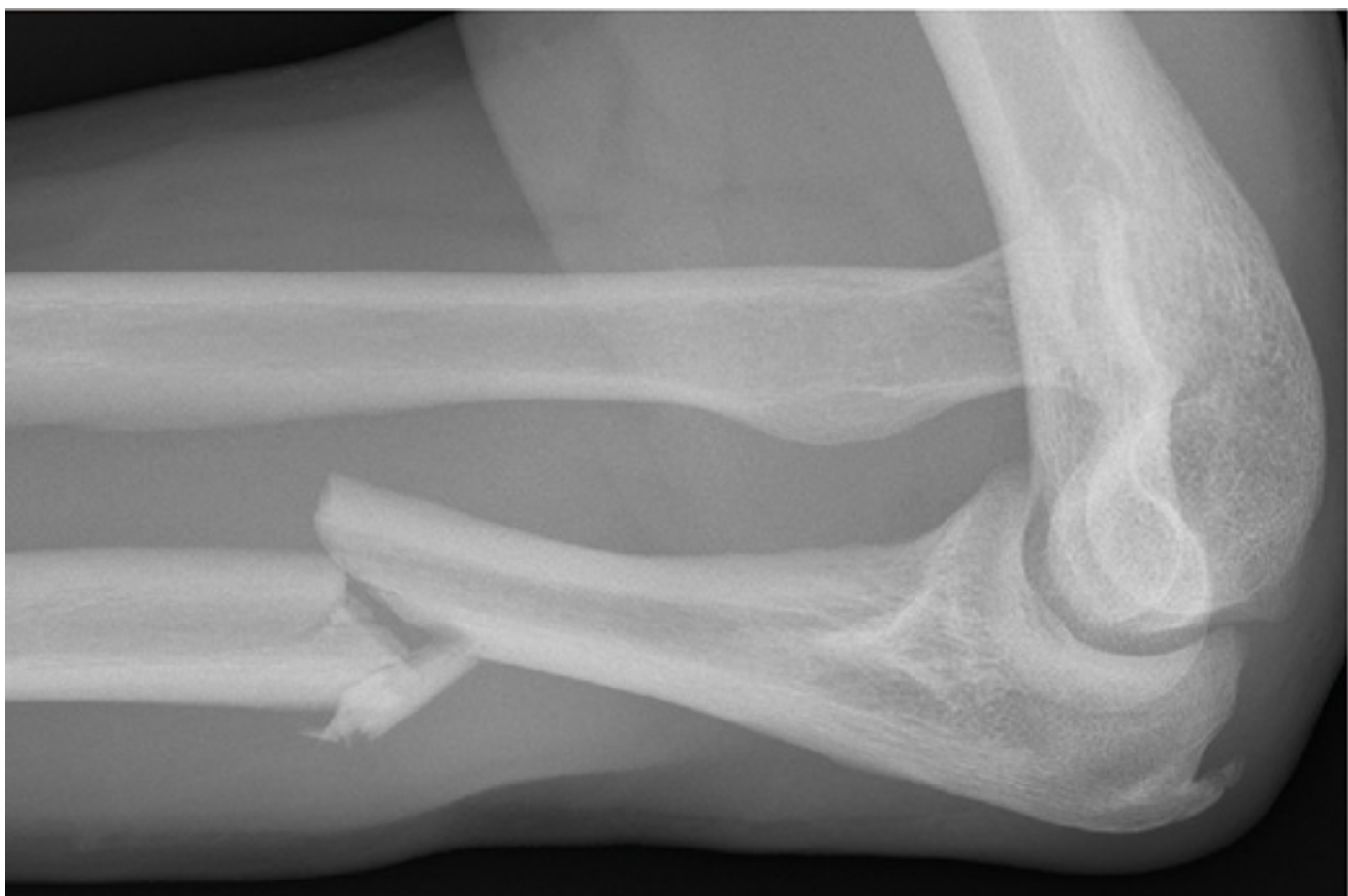Scapula

Subscapularis
muscle

Infraspinatus muscle





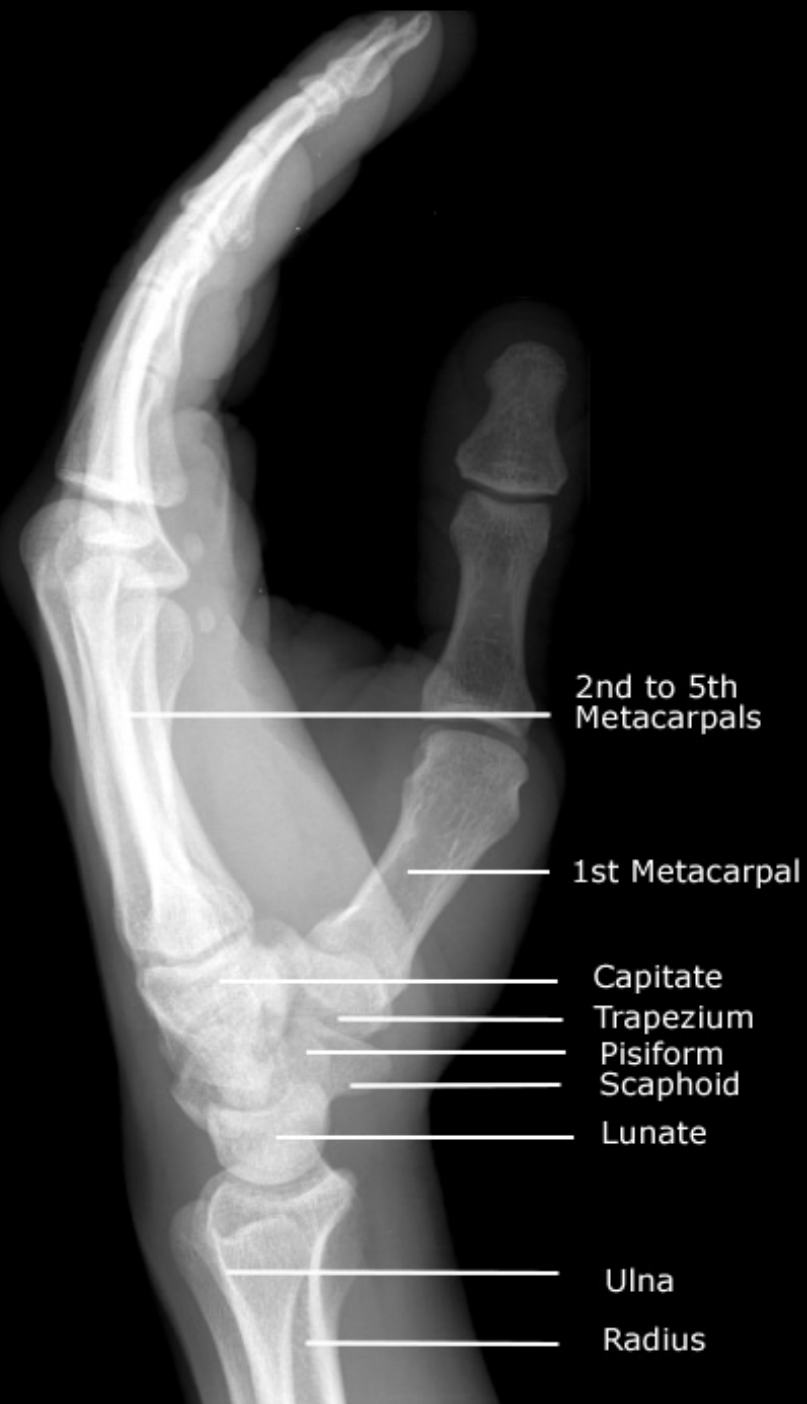



Phalanges

Metacarpals

Carpals



Distal Interphalangeal Joint

Proximal Interphalangeal Joint

Metacarpophalangeal Joint

Hamate
Capitate
Triquetrium
Pisiform
Lunate
Ulna Styloid Process
Ulna

Distal Phalanx

Middle Phalanx

Proximal Phalanx

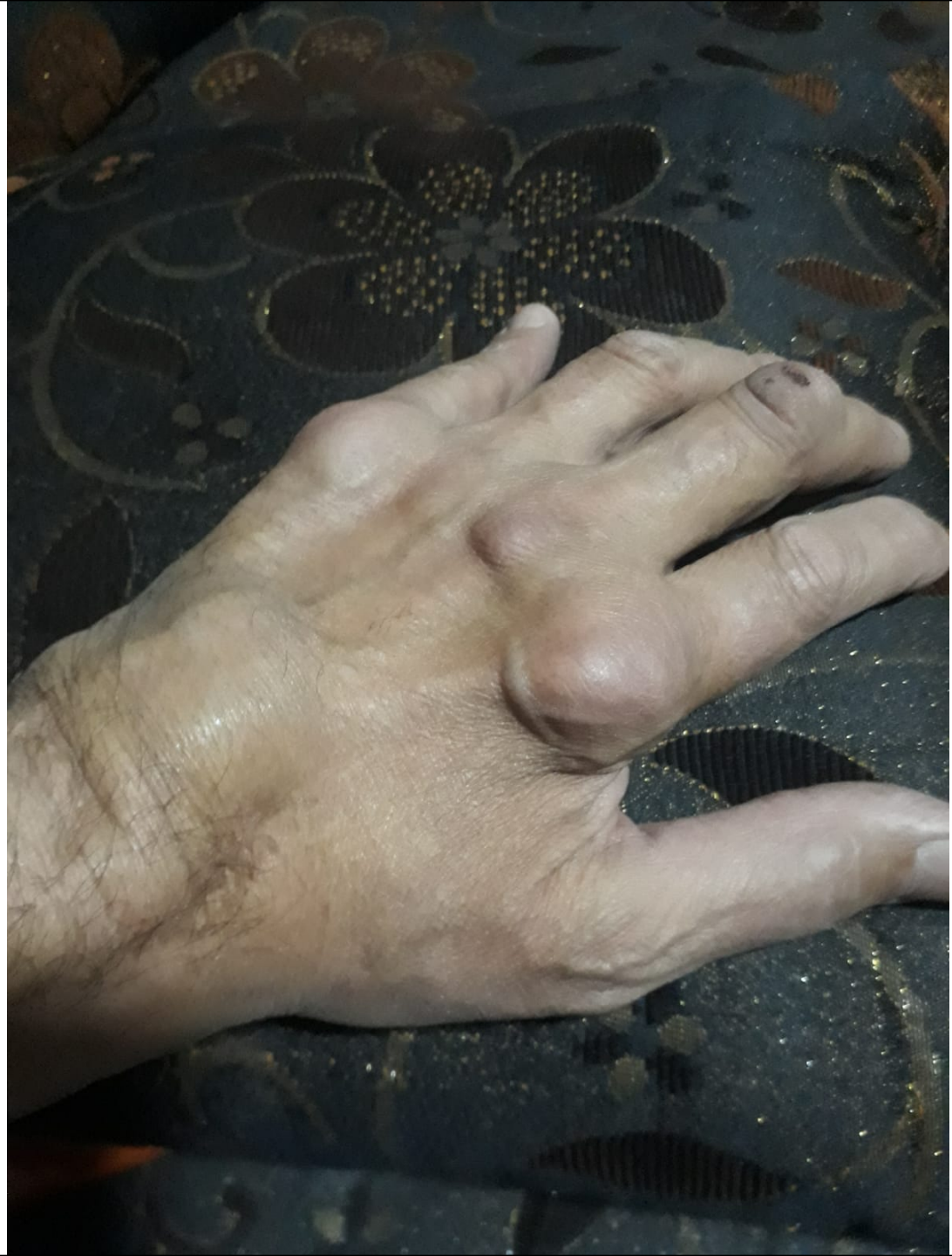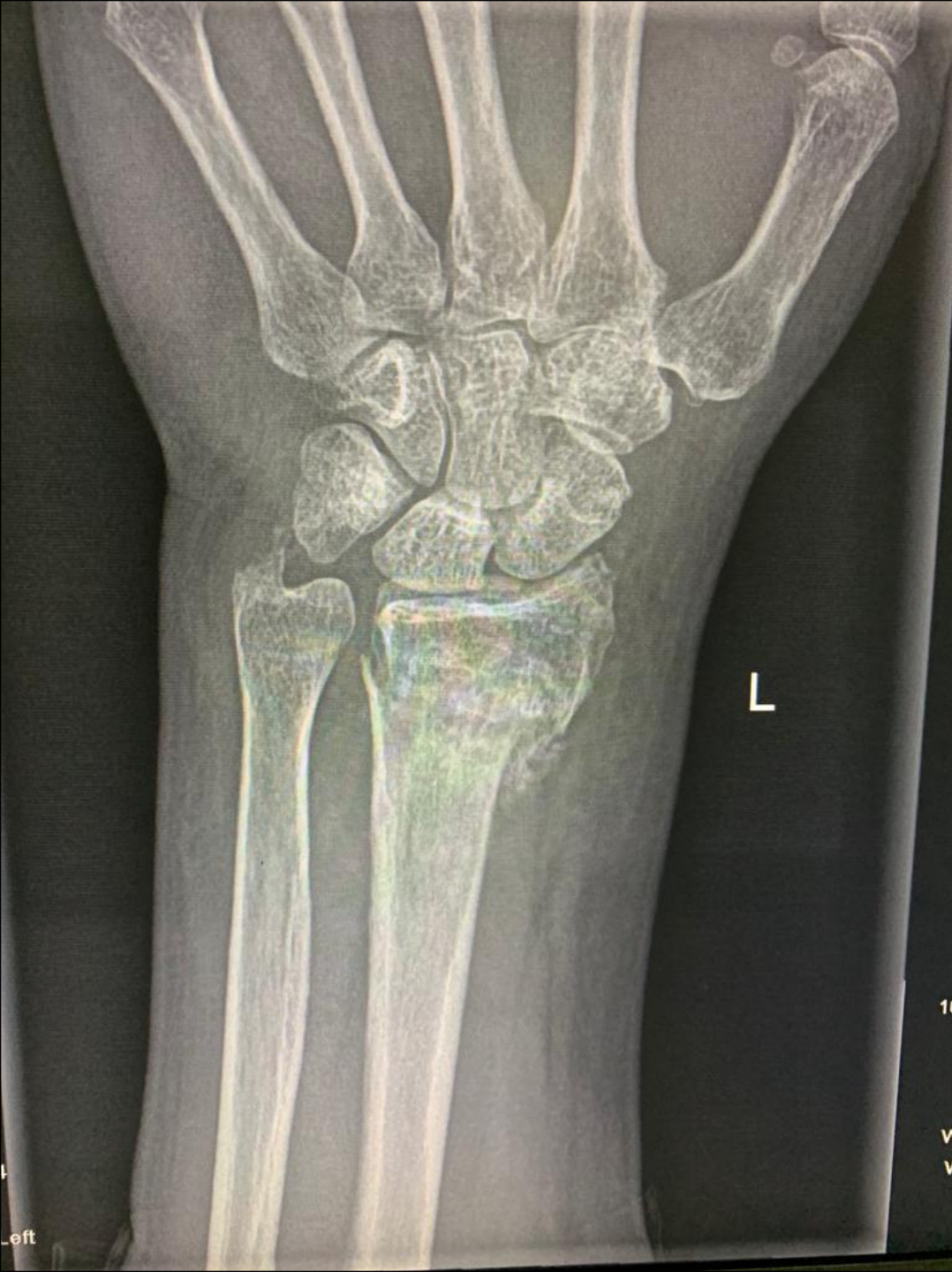Phalanges

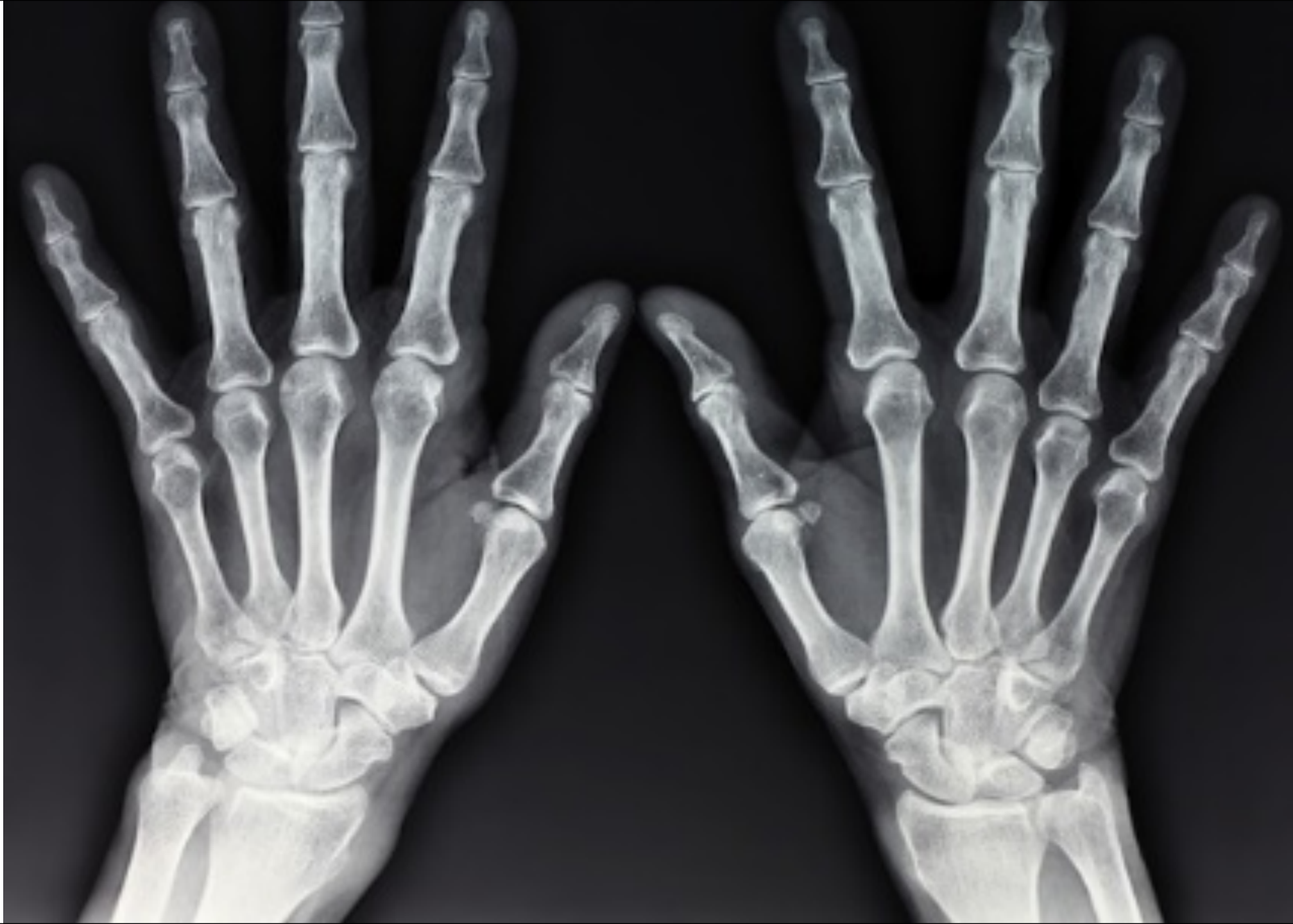Metacarpals

Carpals

5 4 3 2 1

Trapezoid
Trapezium
Scaphoid
Radial Styloid Process
Radius







Distal Interphalangeal Joint

Proximal Interphalangeal Joint

Metacarpophalangeal Joint

Hamate

Capitate


Triquetrium

Pisiform

Lunate

Ulna Styloid Process

Ulna



Distal Phalanx

Middle Phalanx

Proximal Phalanx

Phalanges

5

4

3

2

1

Metacarpals

Trapezoid

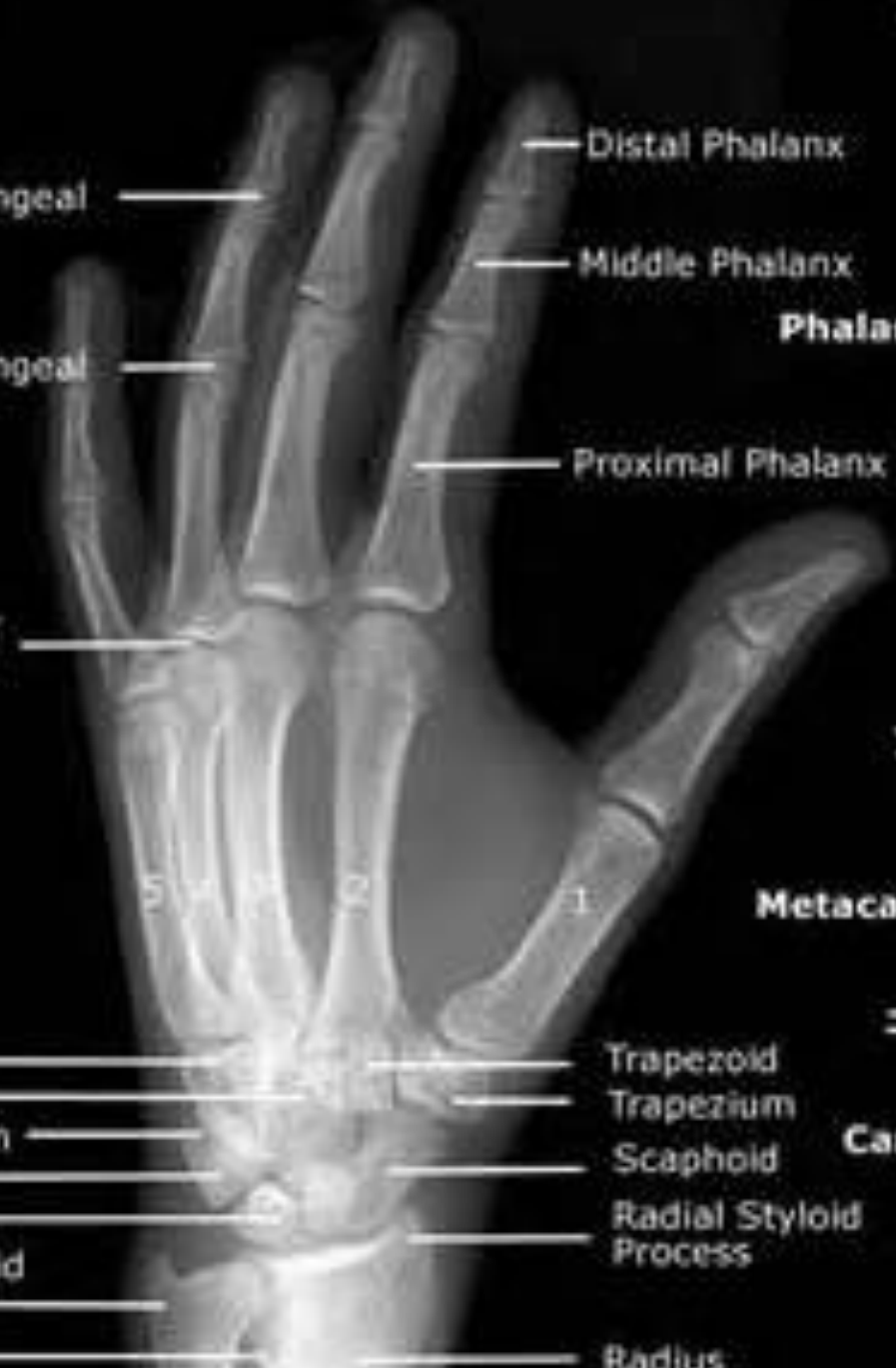Trapezium

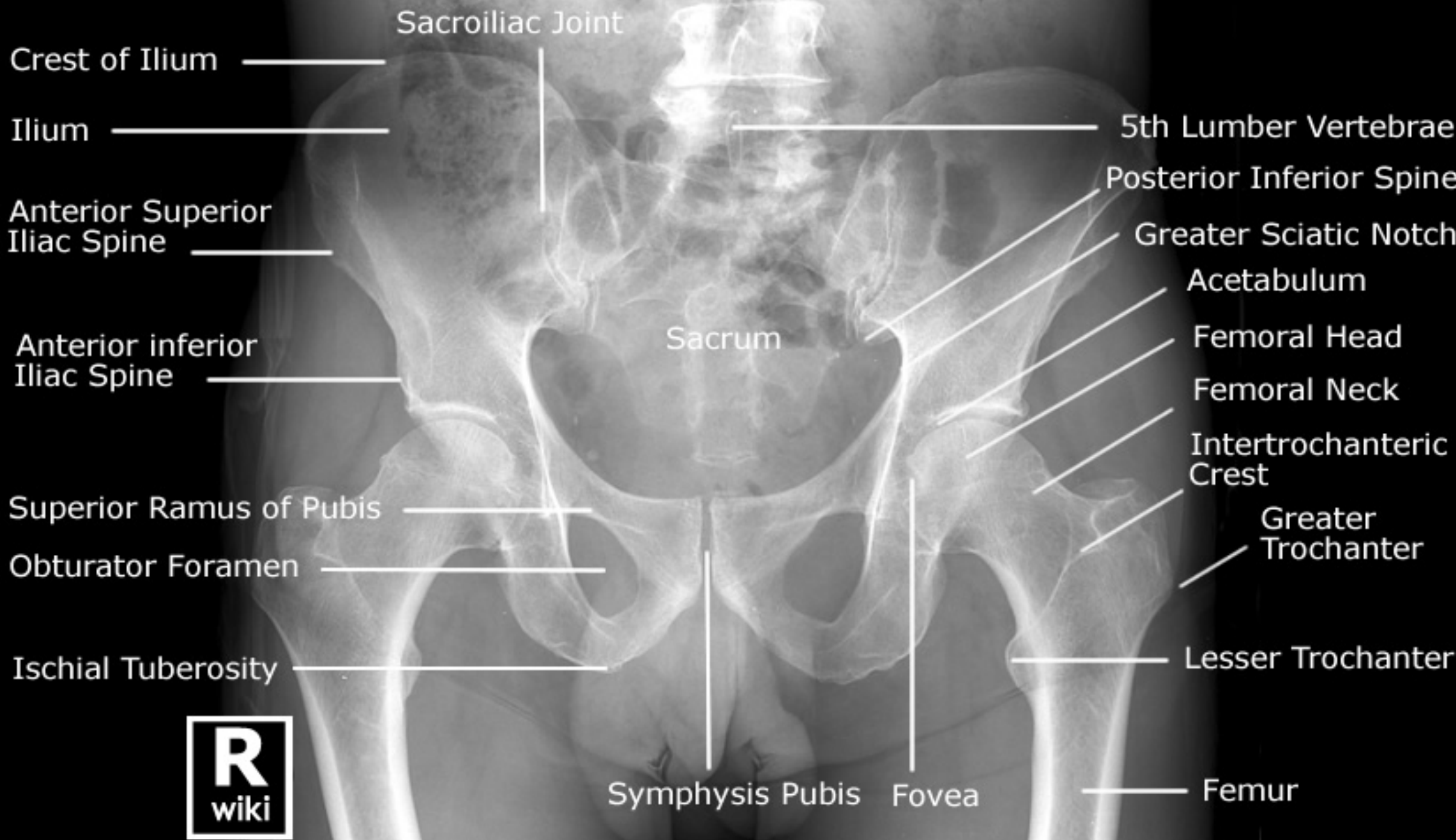Scaphoid

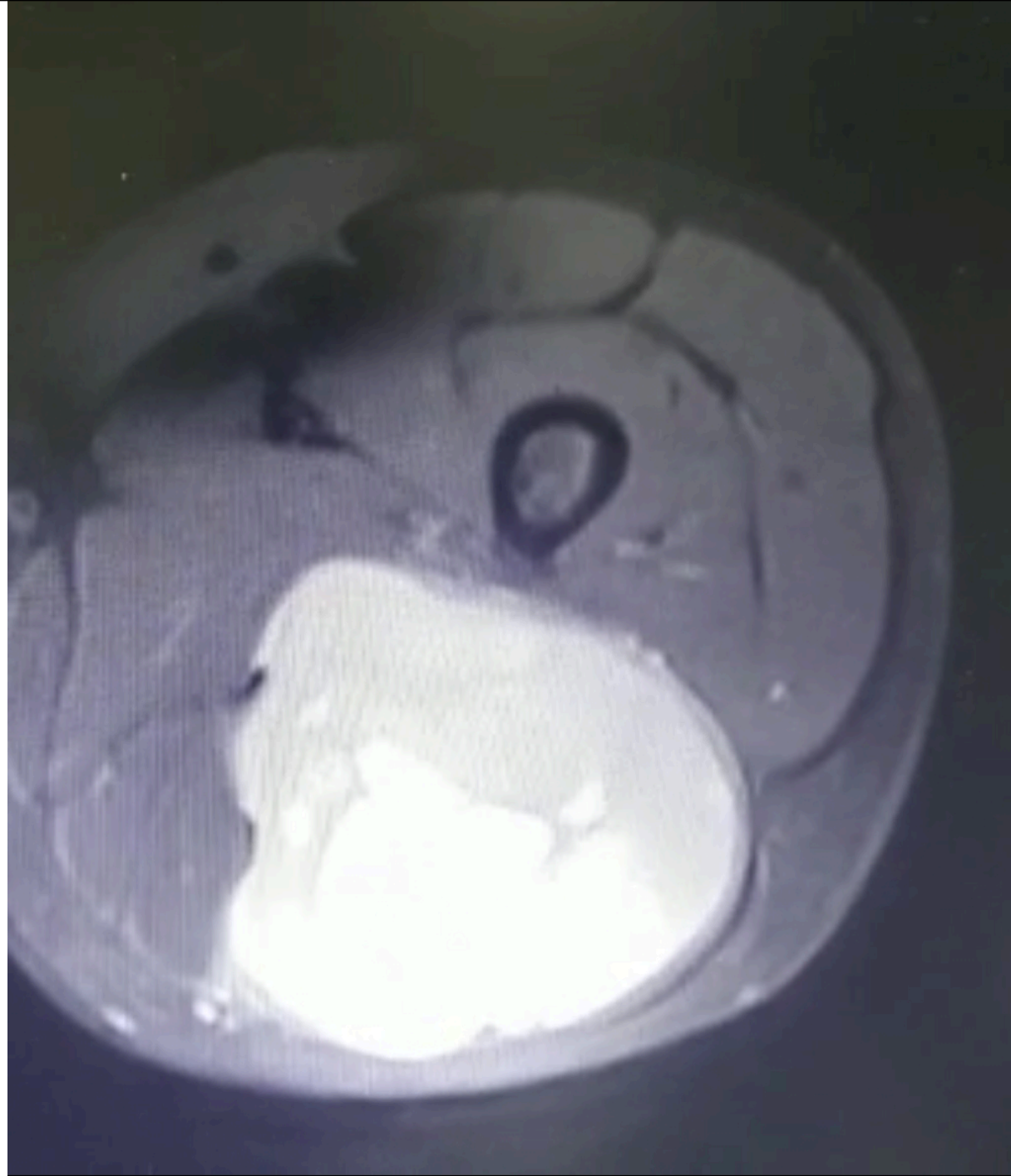
Radial Styloid Process

Radius

Carpals







Femur

Lateral Epicondyle

Lateral Femoral Condyle

Head of Fibula

Fibula

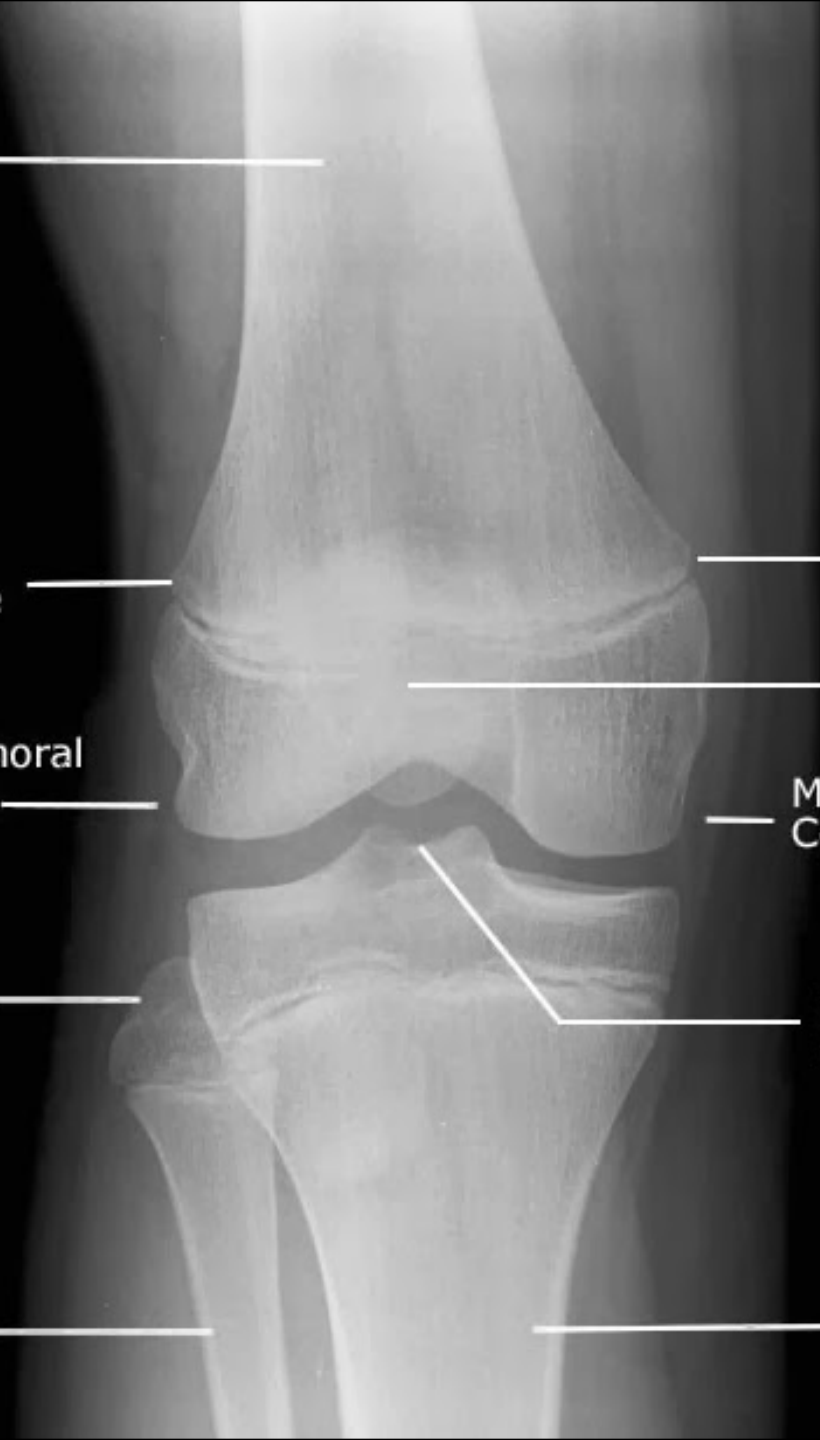Medial Epicondyle

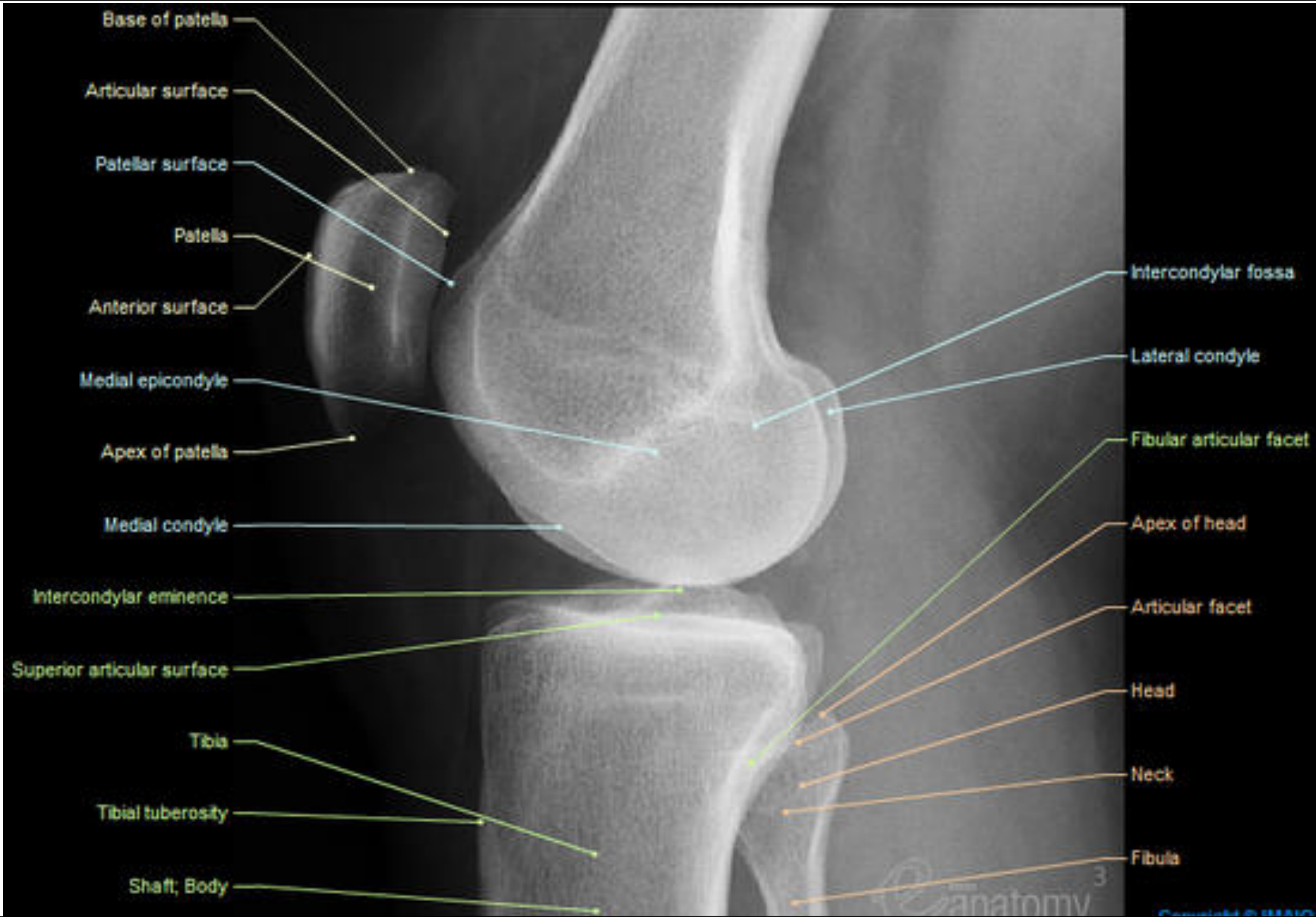
Patella

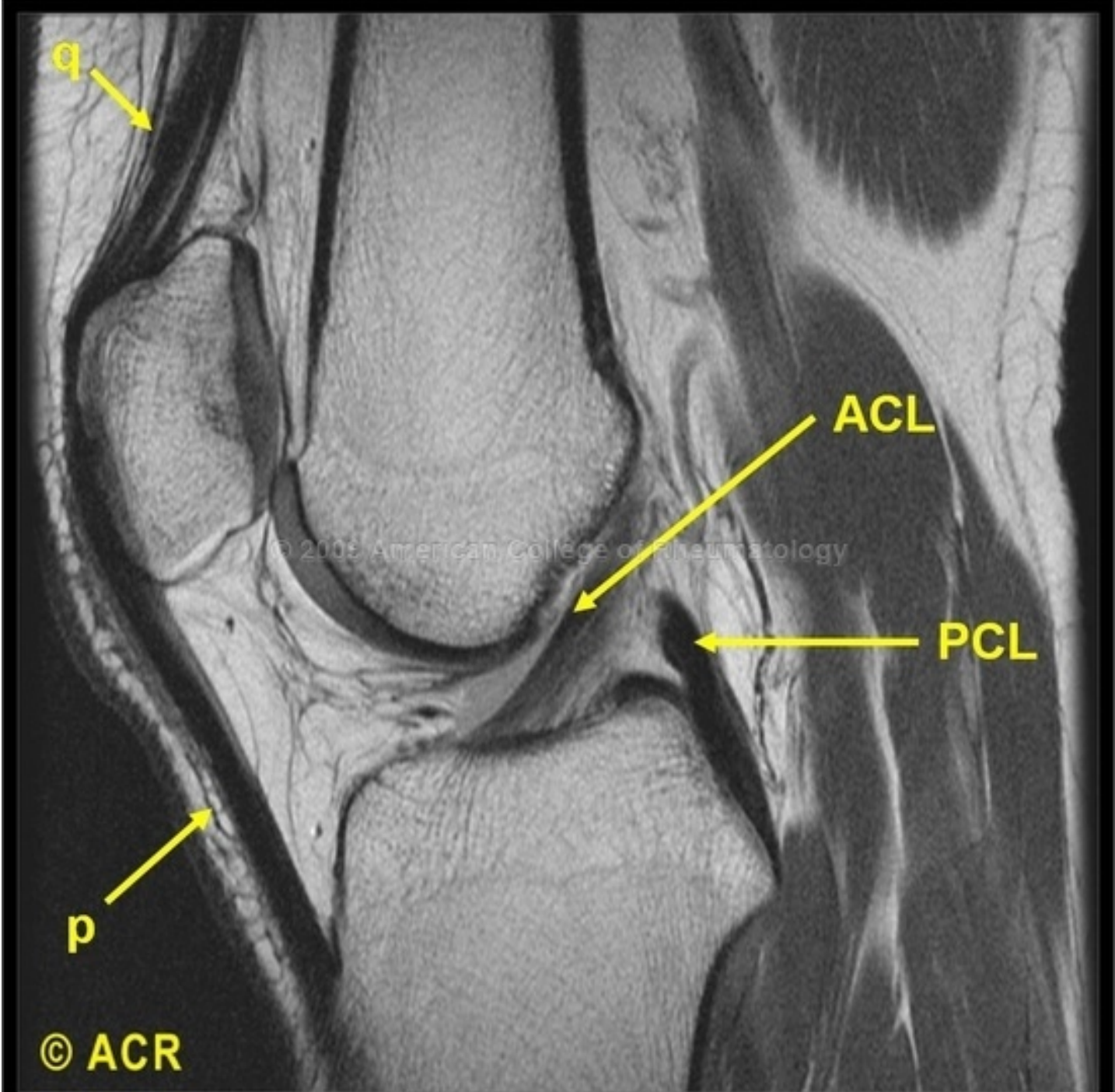
Medial Femoral Condyle

Intercondylar Eminence

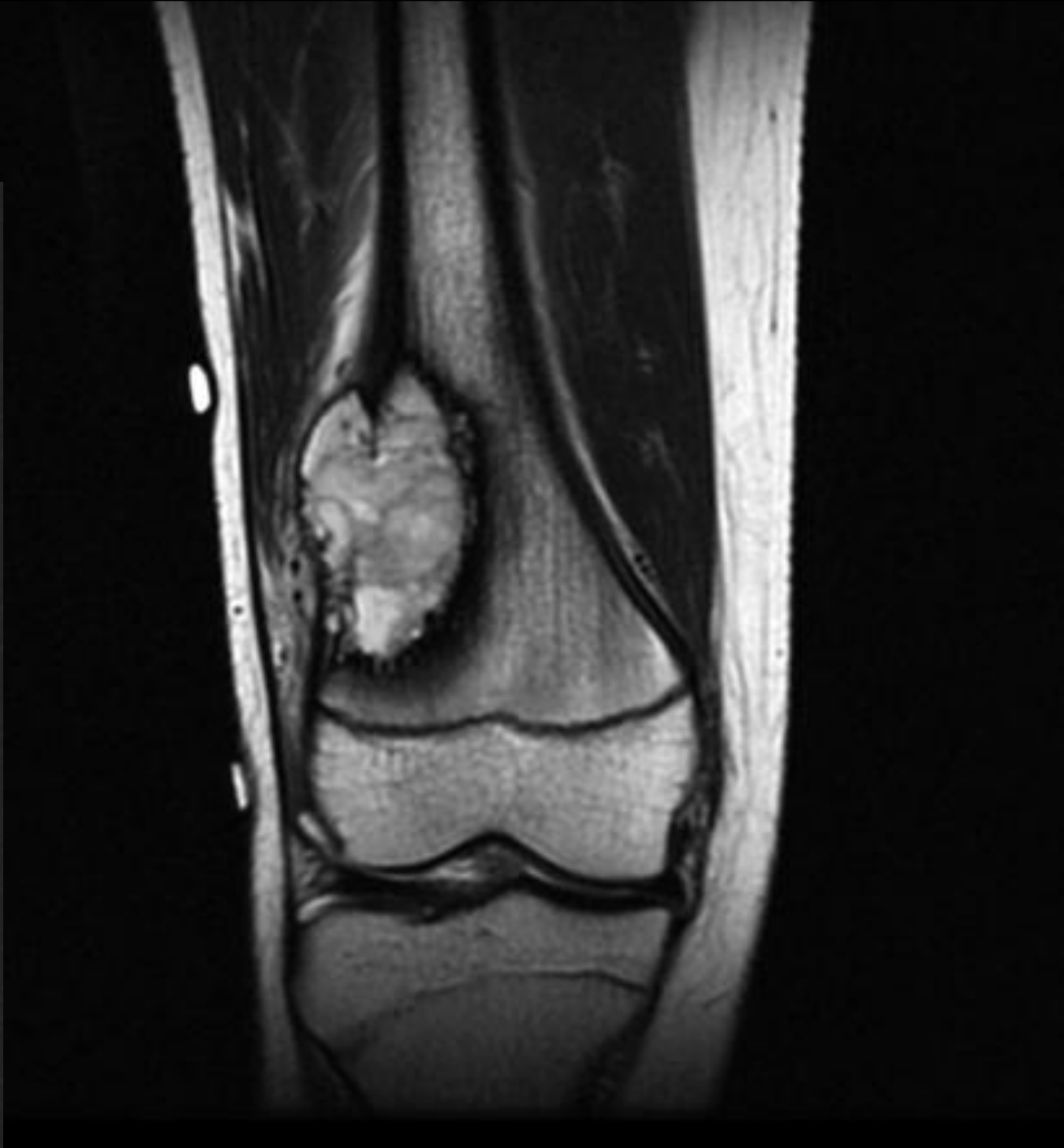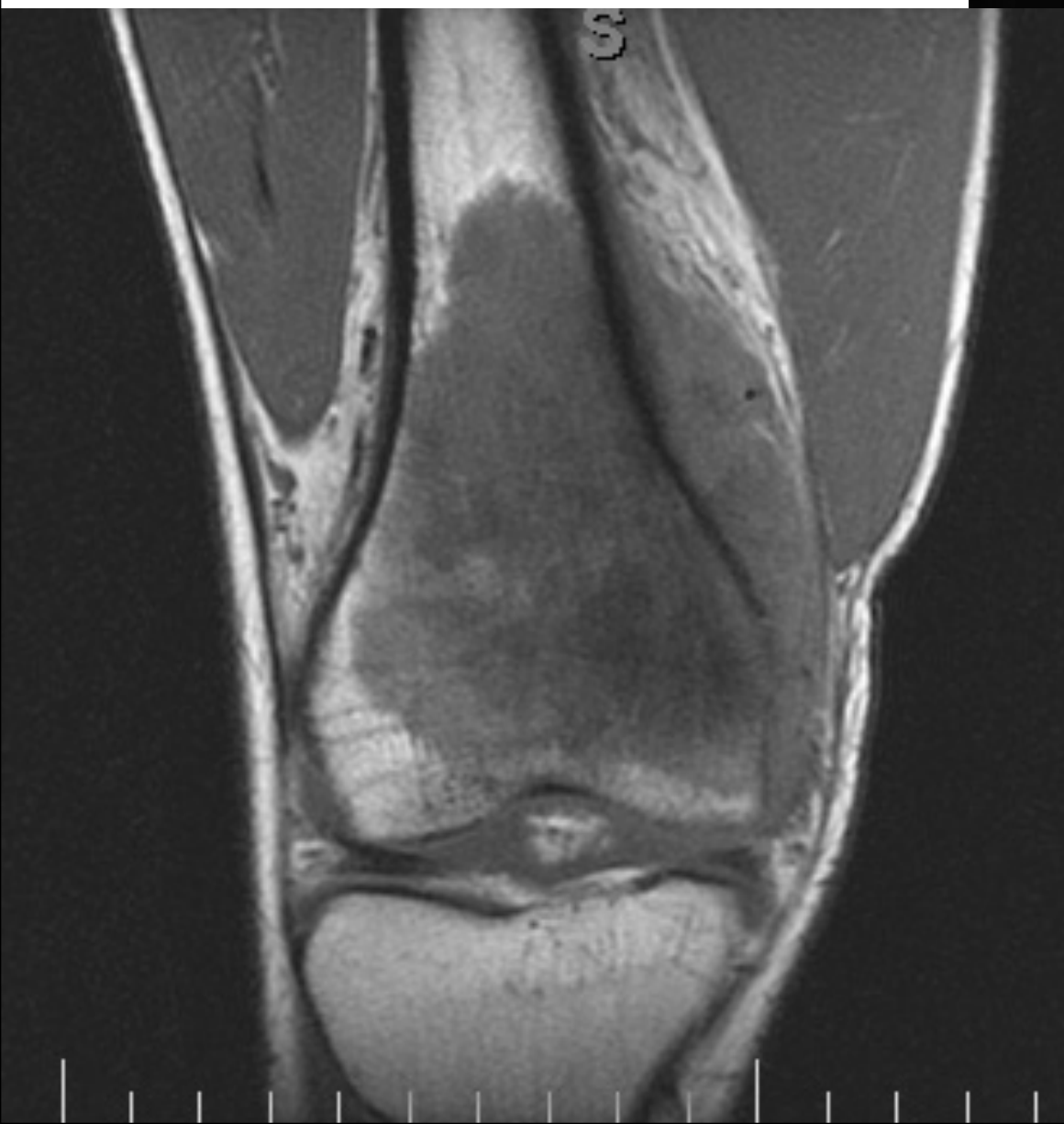
Tibia

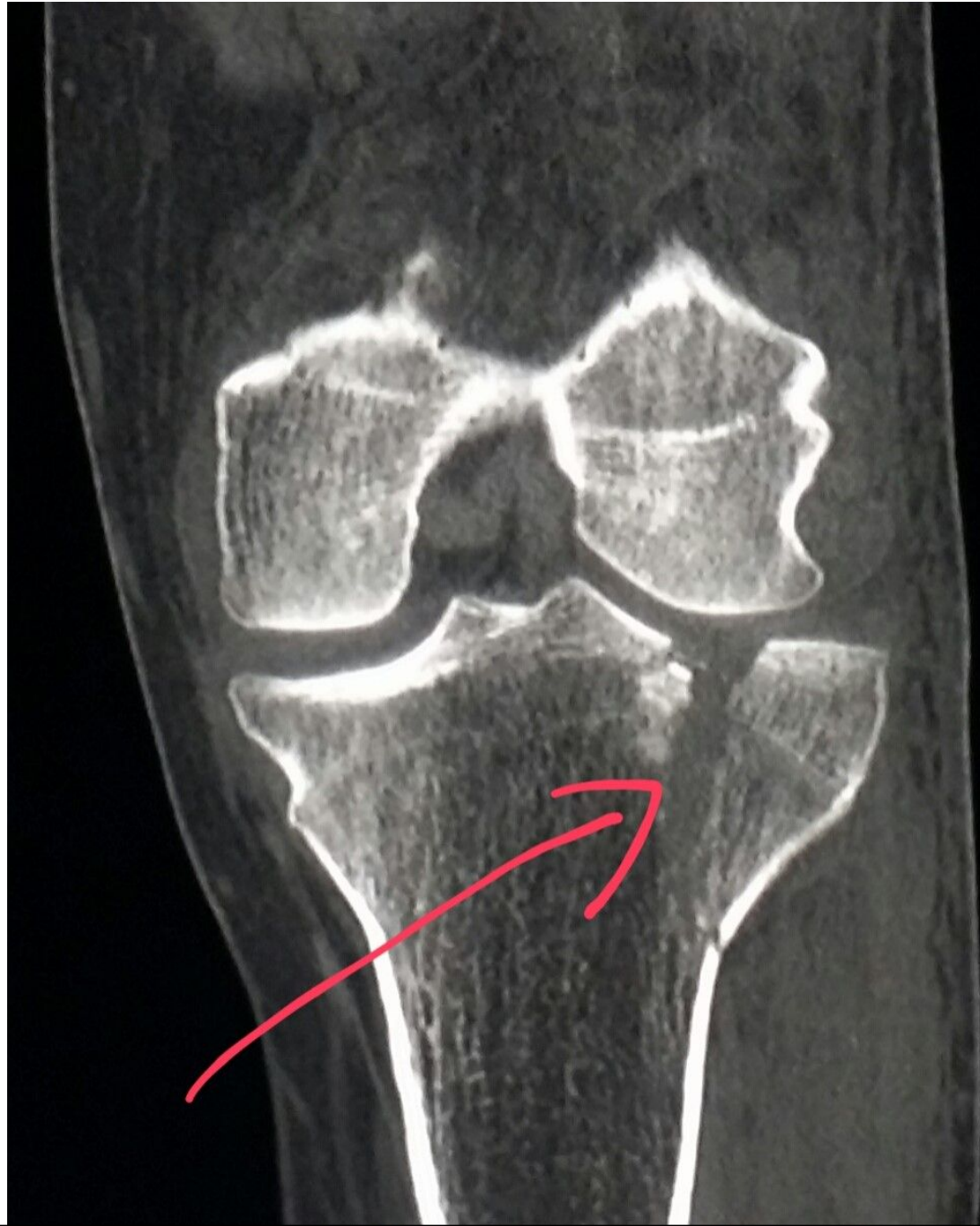
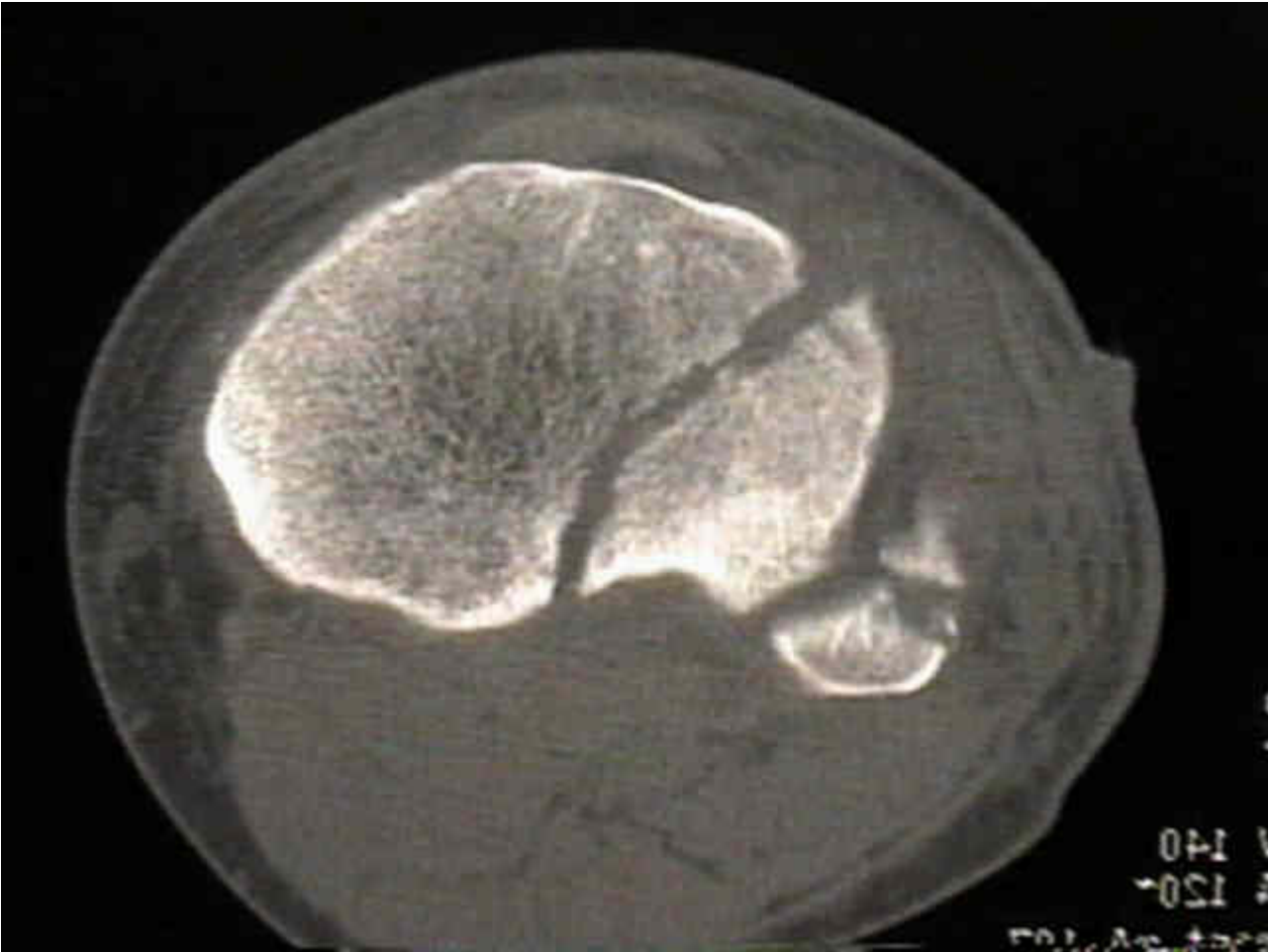
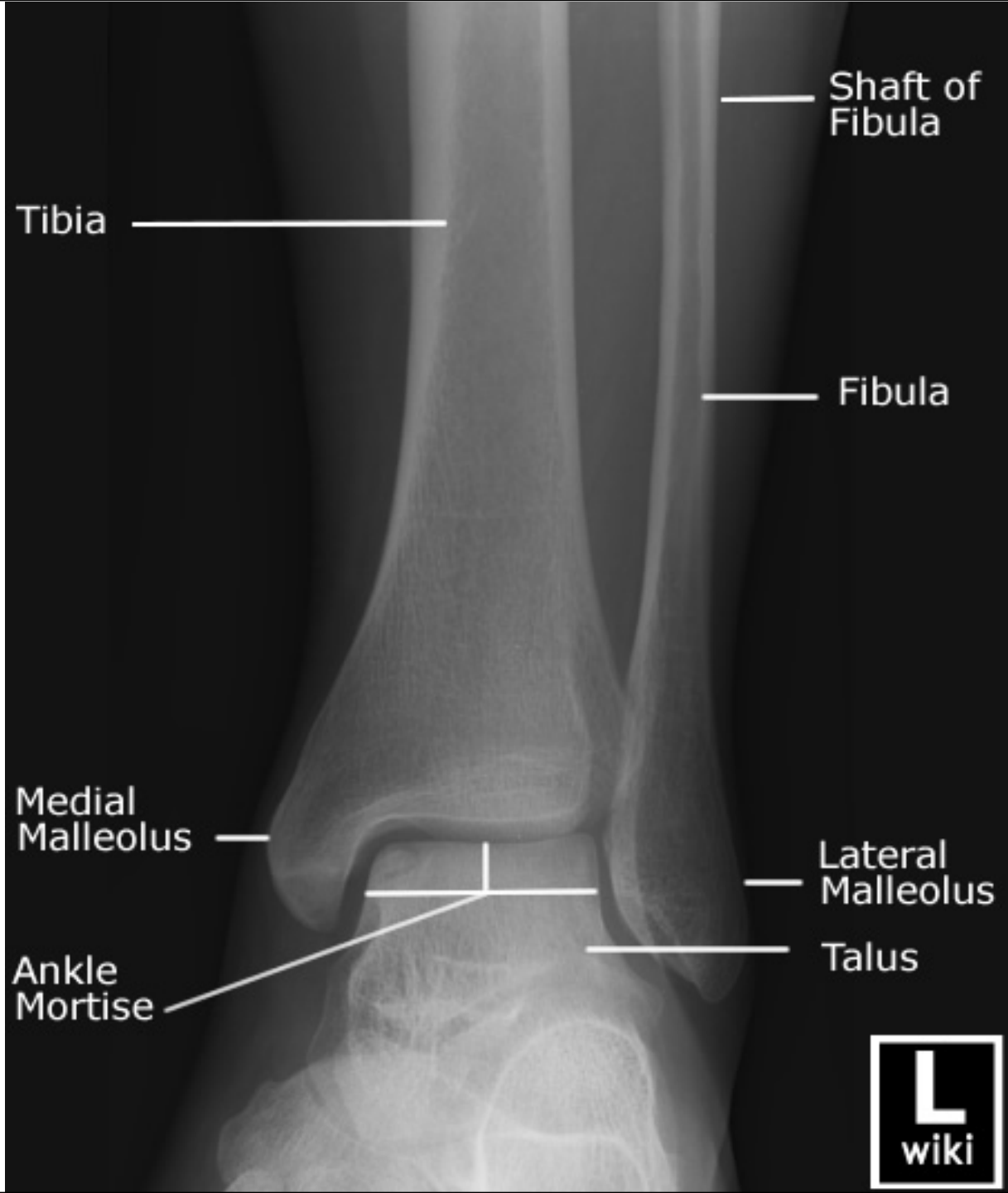




© ACR







Tibia

Shaft of Fibula

Fibula

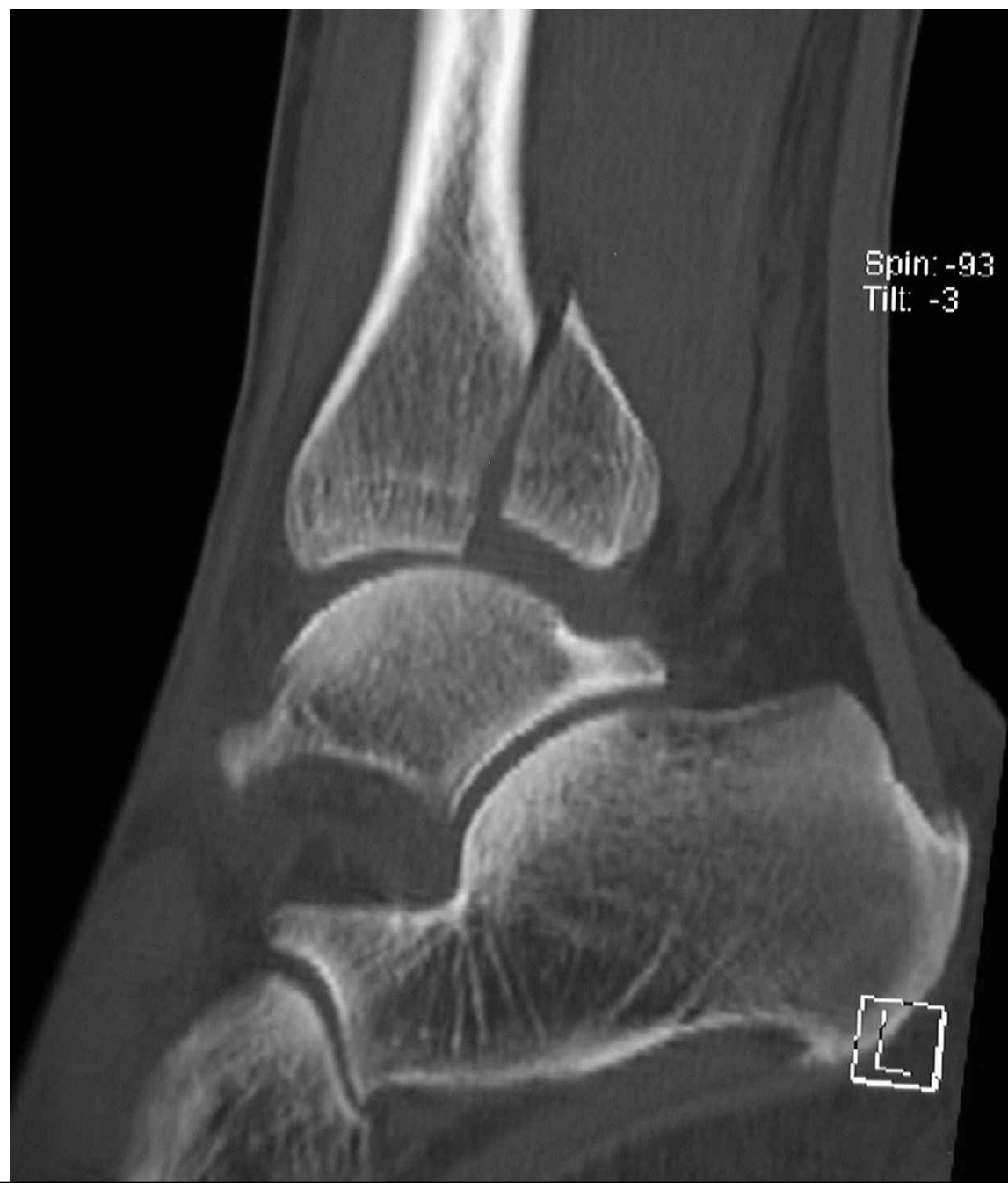Medial Malleolus

Lateral Malleolus

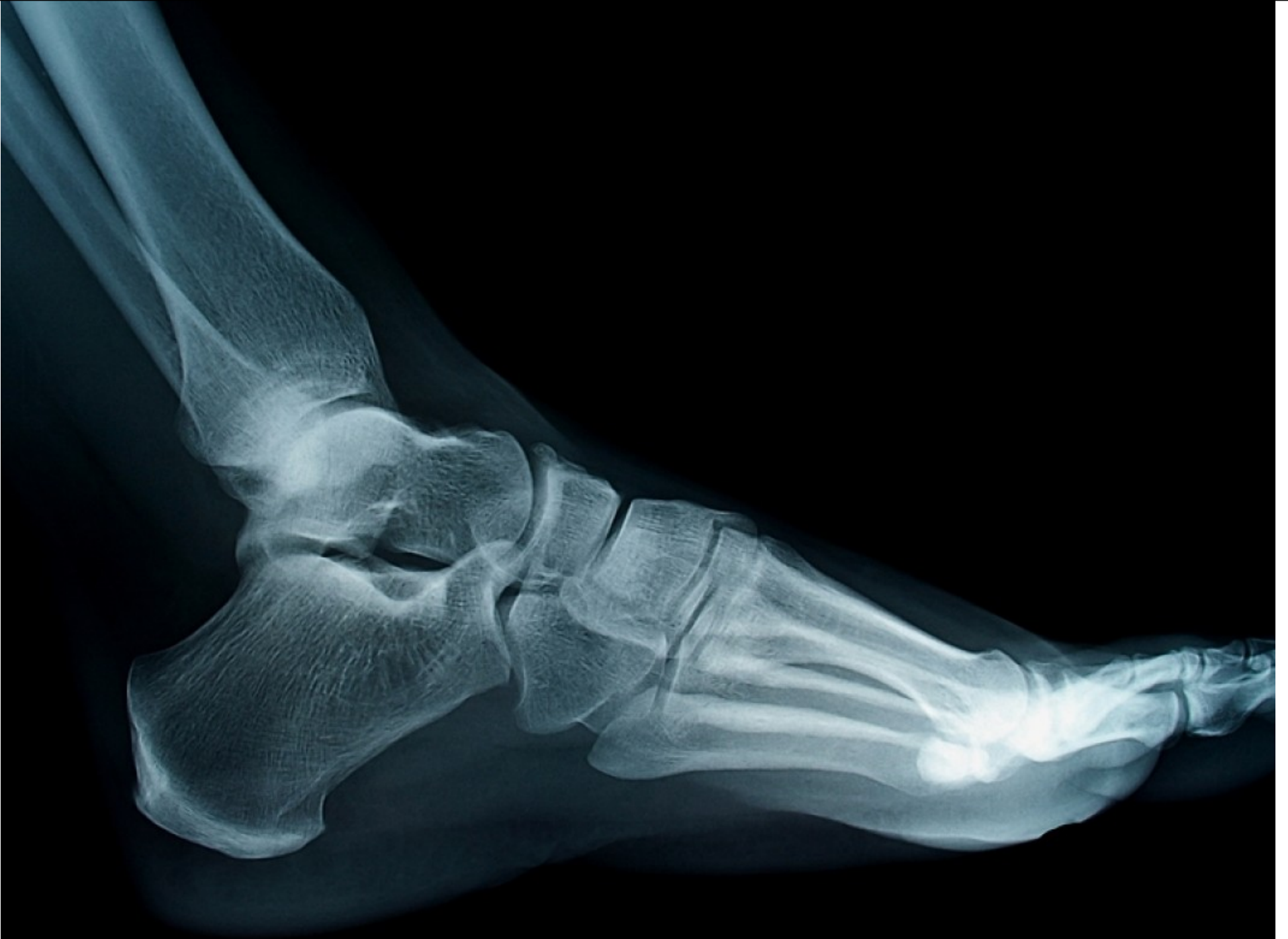Ankle Mortise

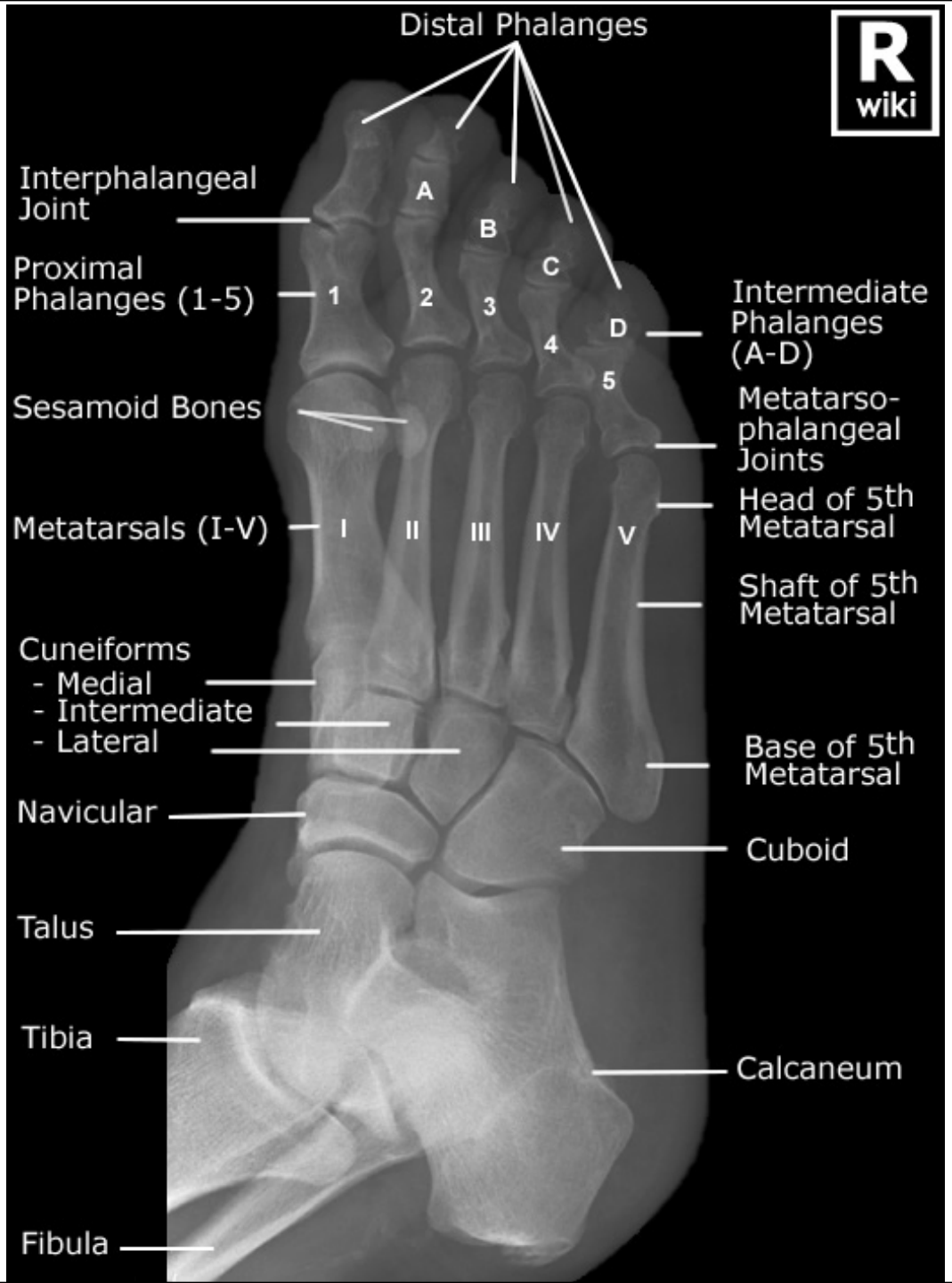
Talus

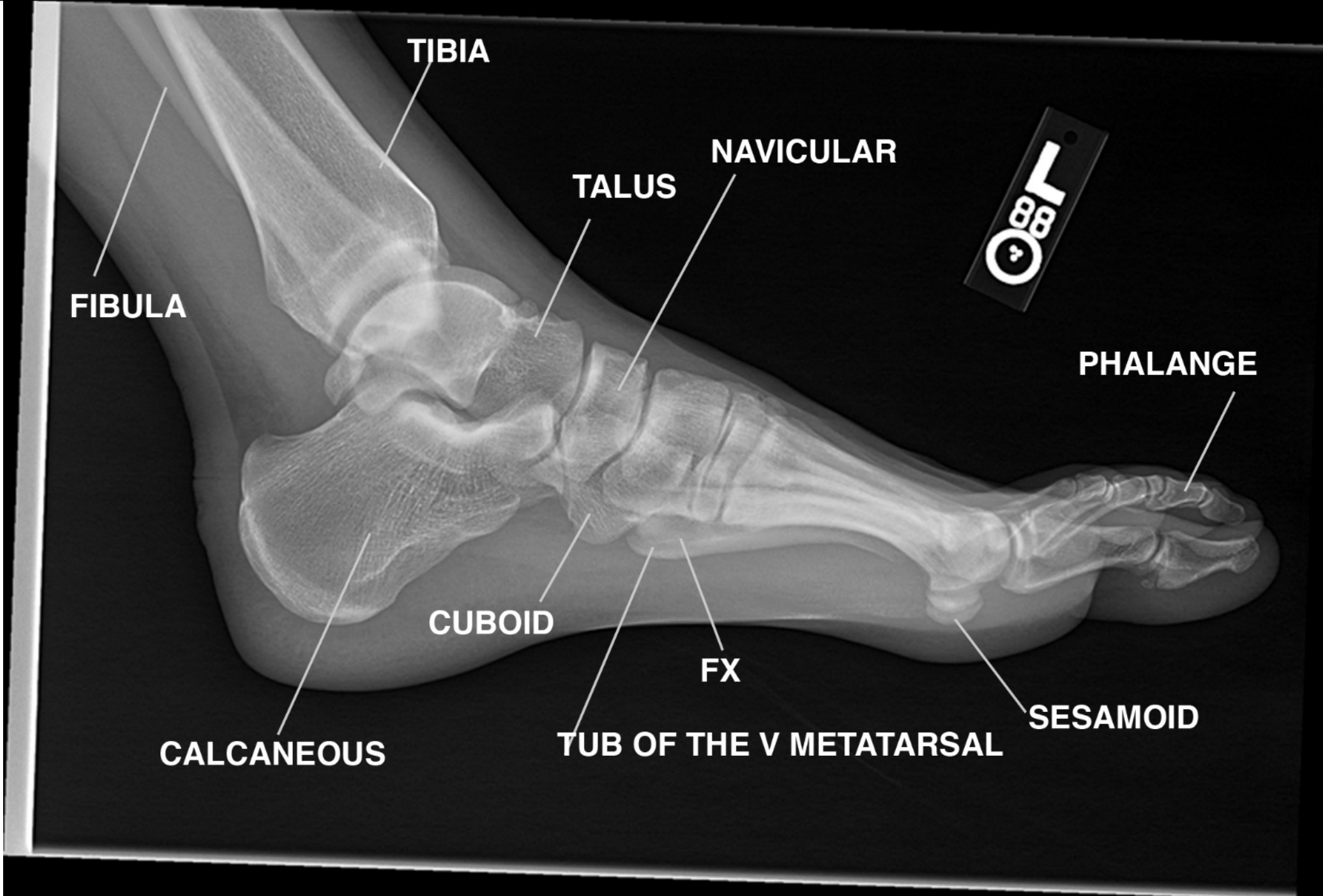




Spin: -93
Tilt: -3







FIBULA

TIBIA

NAVICULAR

TALUS

PHALANGE

CALCANEOUS

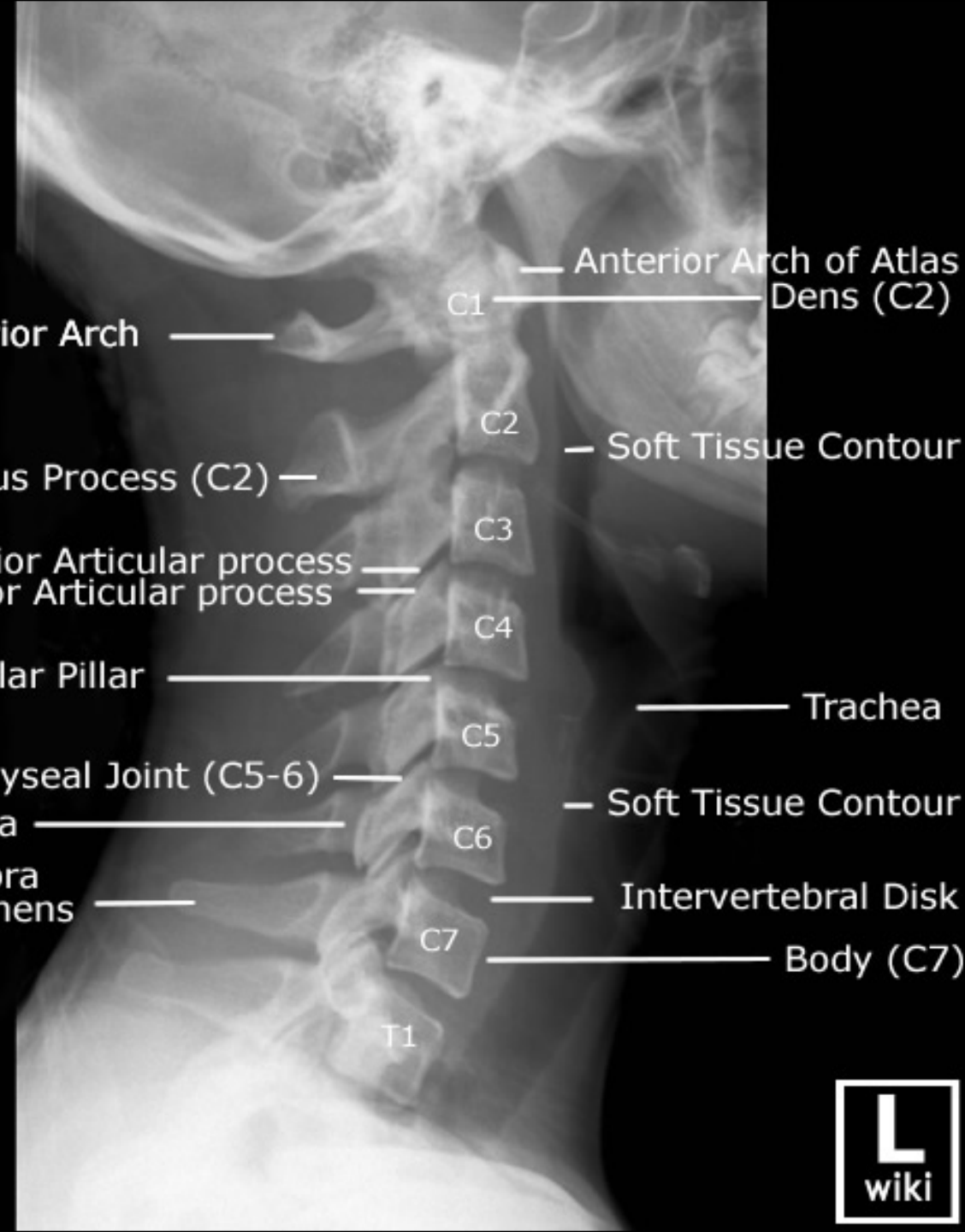
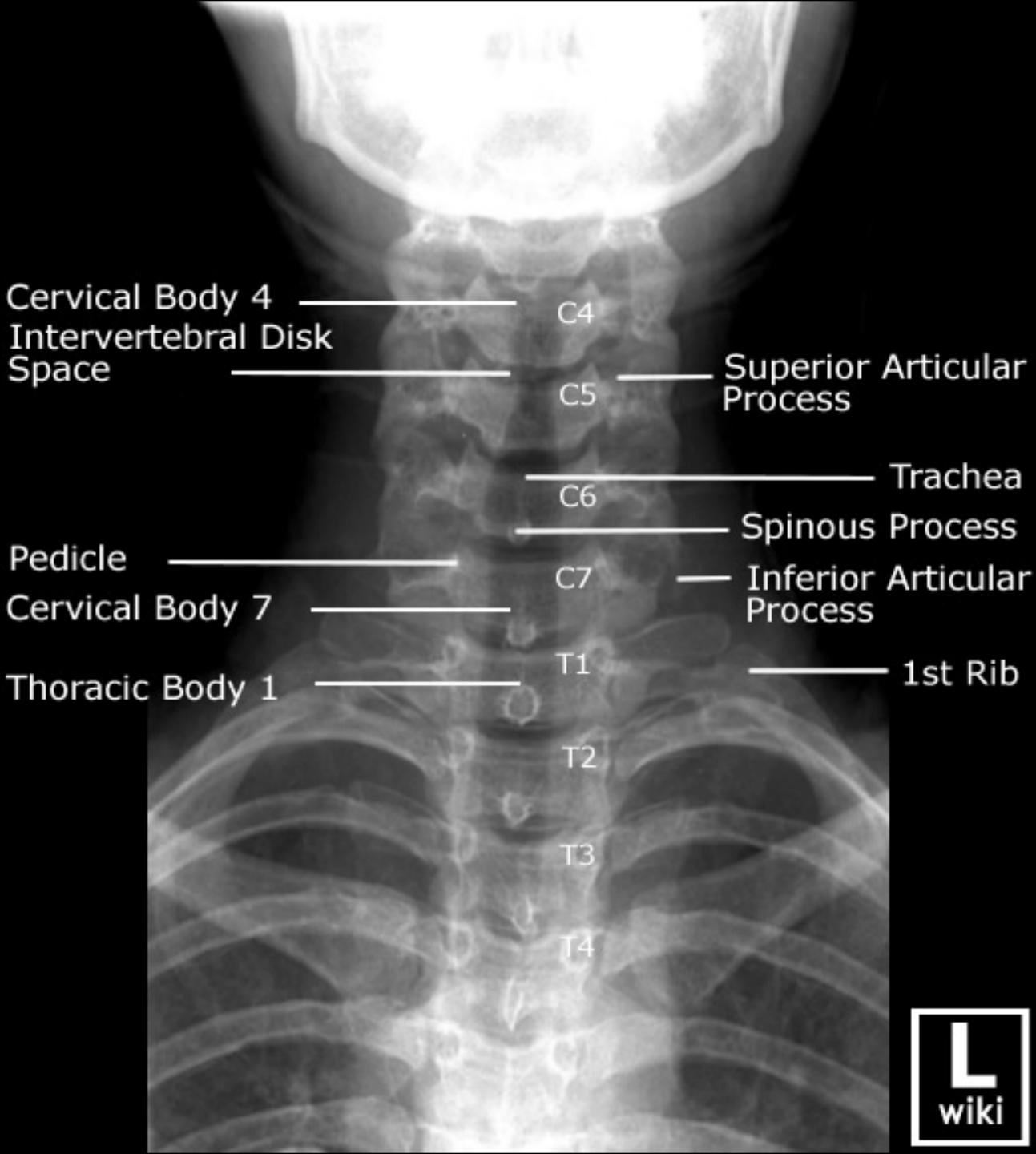
CUBOID

FX

TUB OF THE V METATARSAL

SESAMOID





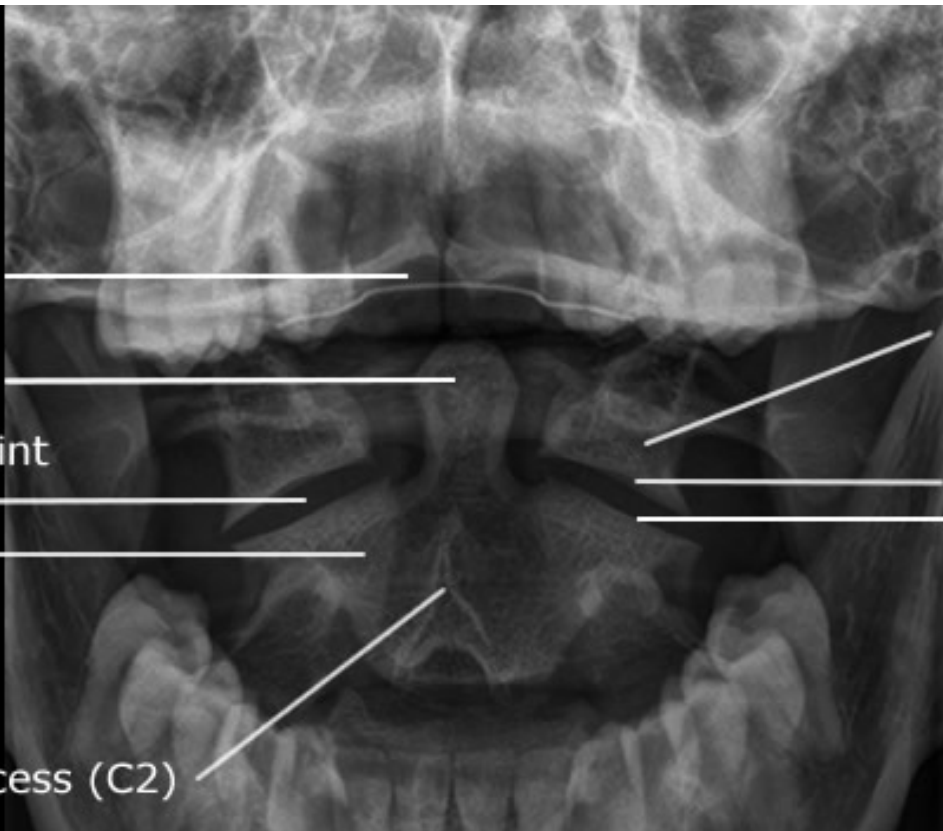
Upper Incisors

Odontoid Process

Zygapophyseal Joint
Space (C1-C2)

Body (C2)

Bifid Spinous Process (C2)



Lateral Mass (C1)

Inferior Articular
Surface (C1)

Superior Articular
Surface (C2)



