

**Jordan University
Faculty Of Medicine**



The Urinary Bladder and Urethra

DR. AHMED SALMAN

ASSOCIATE PROFESSOR OF ANATOMY

Urinary Bladder

The urinary bladder is a hollow viscus with strong muscular walls which acts as a reservoir for urine.

Site of Urinary Bladder

In infants: the bladder lies in the abdomen

At about 6 years of age : the bladder begins to enter the enlarging pelvis.

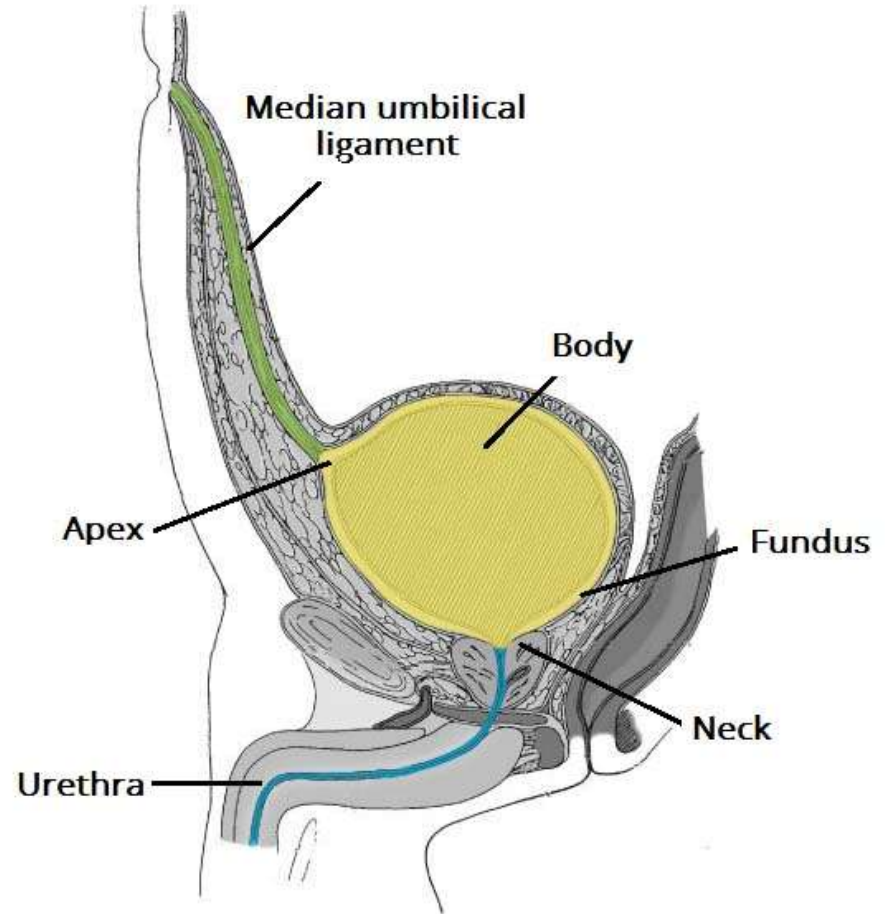
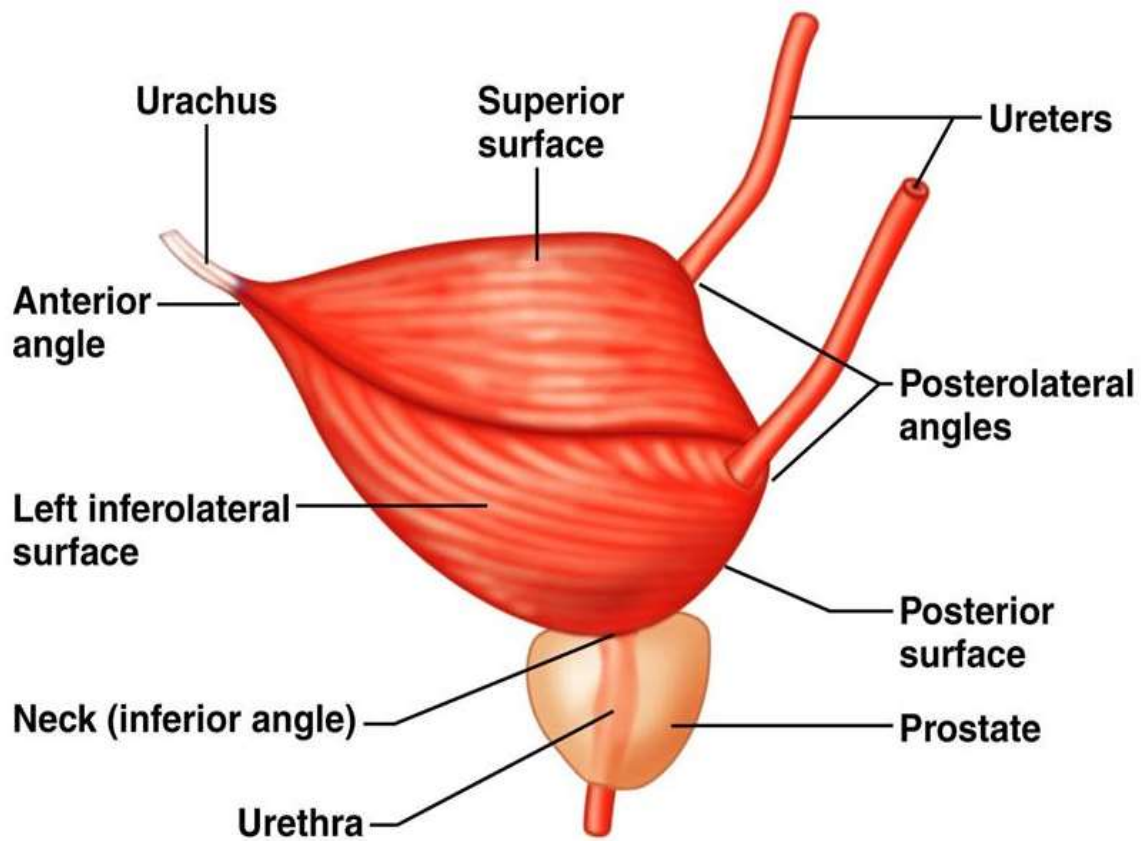
After puberty : the bladder lies within the lesser pelvis .

In the adult: an empty bladder lies in lesser pelvis and as it fills, it ascends to the greater pelvis.

Capacity of the Bladder:

- Average capacity of adult bladder is about 300 ml.
- Distension of the bladder by 500 ml may be tolerated. Beyond this, distension of the bladder is painful

The bladder is enveloped in loose connective tissue called vesical fascia in which vesical venous plexus is embedded.



Description and Relations of the Urinary Bladder :

- The empty bladder has; Apex, base, 3 surfaces (superior, right and left inferolateral) and neck .

1- Apex of the bladder:

- Is continuous with the median umbilical ligament which raises the median-umbilical fold of peritoneum.
- The ligament is the remnant of the embryonic urachus.

2- Base of the bladder (fundus) :

- It is directed posteroinferiorly
- Its superolateral angles receive the ureters
- **Relations :**

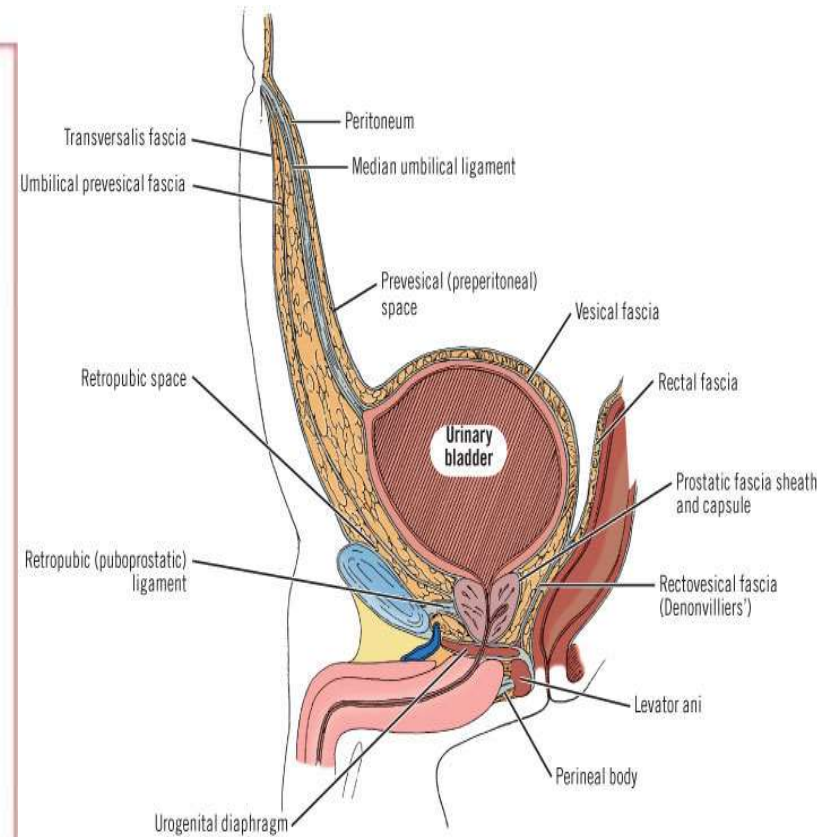
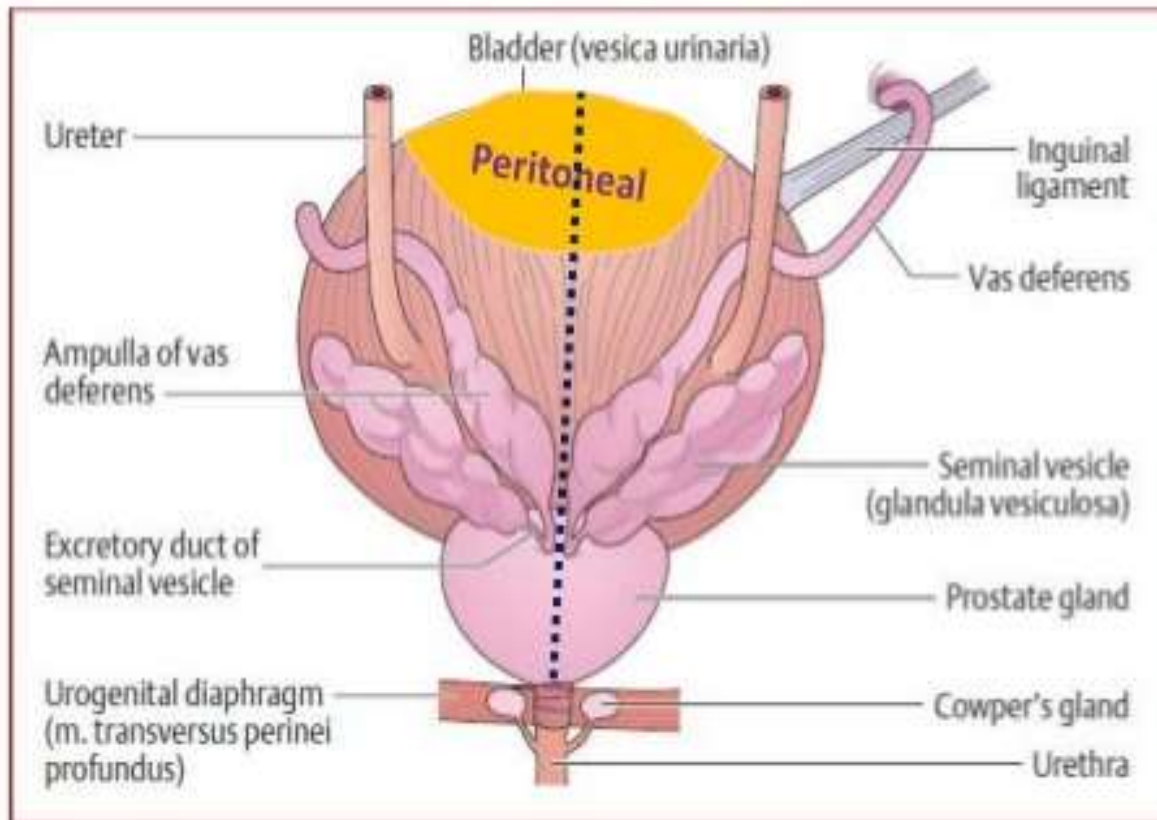
Male

- Base is related to rectum, but separated from it by
 - Rectovesical pouch
 - 2 seminal vesicles
 - Ampullae of the vas deferent

female

The base is related to upper part of anterior wall of vagina.

Base of Bladder in male



Copyright ©2006 by The McGraw-Hill Companies, Inc. All rights reserved.

3-Superior Surface:

is covered by peritoneum and is related to

Male	female
<ul style="list-style-type: none">❖ Sigmoid colon,❖ Loops of ileum	<ul style="list-style-type: none">❖ Vesical surface of uterus.❖ Supravaginal part of cervix with uterovesical pouch in between

4-Inferolateral surface:

It is **not** covered by peritoneum. It is related to:

- ✓ Body of pubis with retropubic pad of fat in the retropubic space of Retzius.
- ✓ Levator ani.
- ✓ Obturator internus.

5-Neck of the bladder:

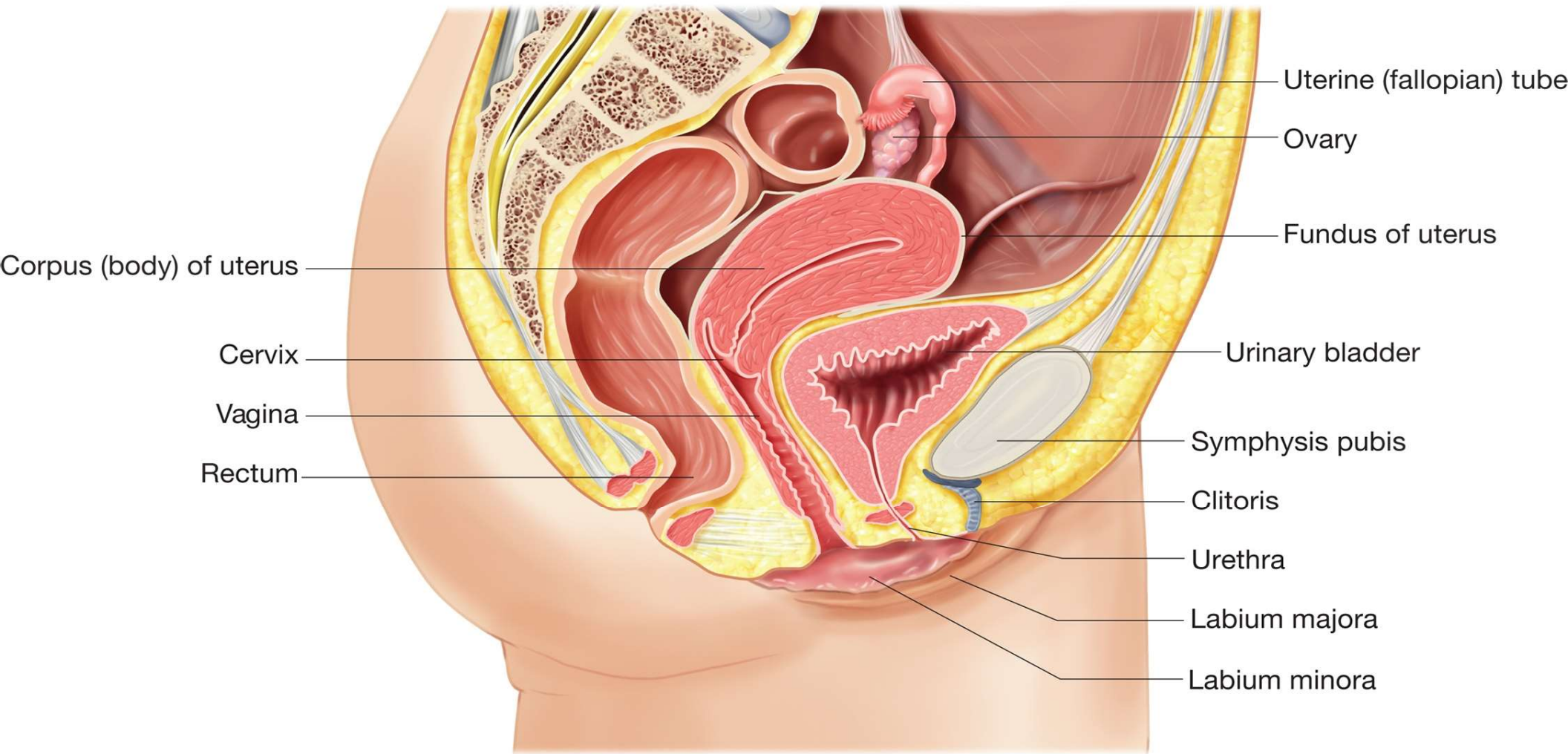
It is the lowest and most fixed part of the bladder.

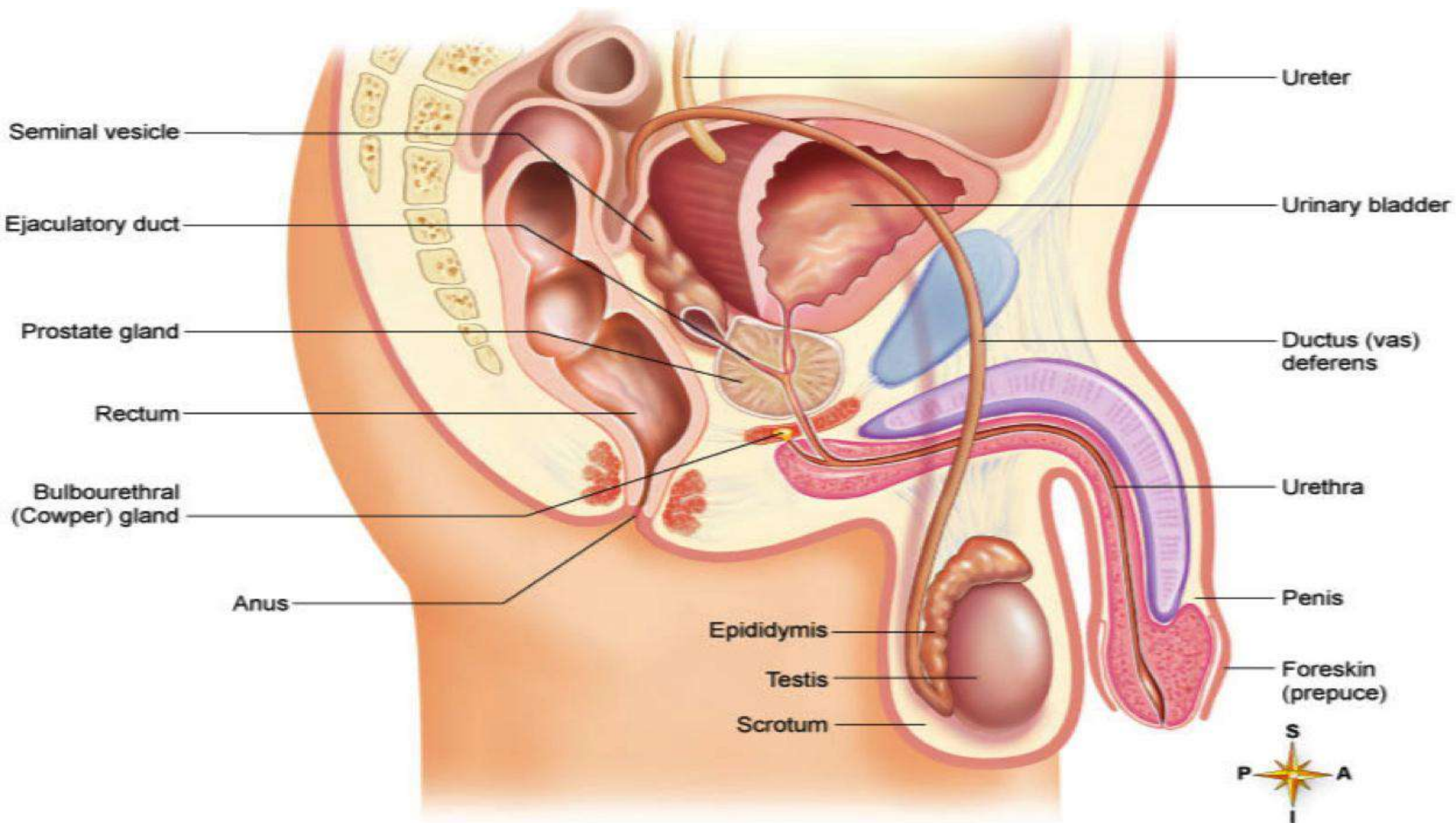
- In the **male**: it is continuous with the urethra at the internal ureteral meatus and rests on the upper surface of the prostate.
- In **female**: it is continuous with the urethra and rests in the pelvic fascia which surrounds the urethra.

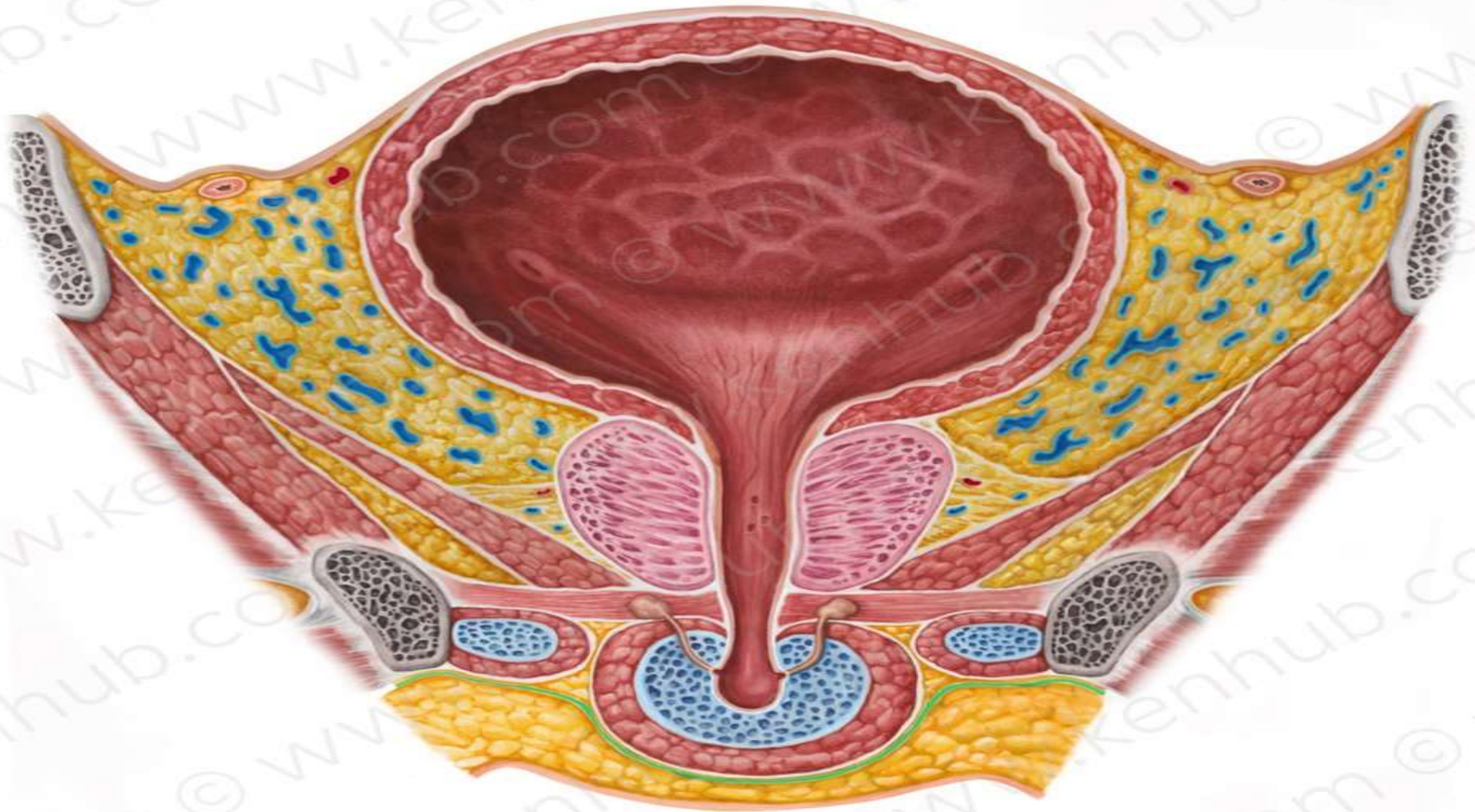
At the junction of the neck and urethra, sphincter vesicae is present.

Muscular coat of the bladder

is composed of smooth muscle and is arranged as three layers known as the detrusor muscle.





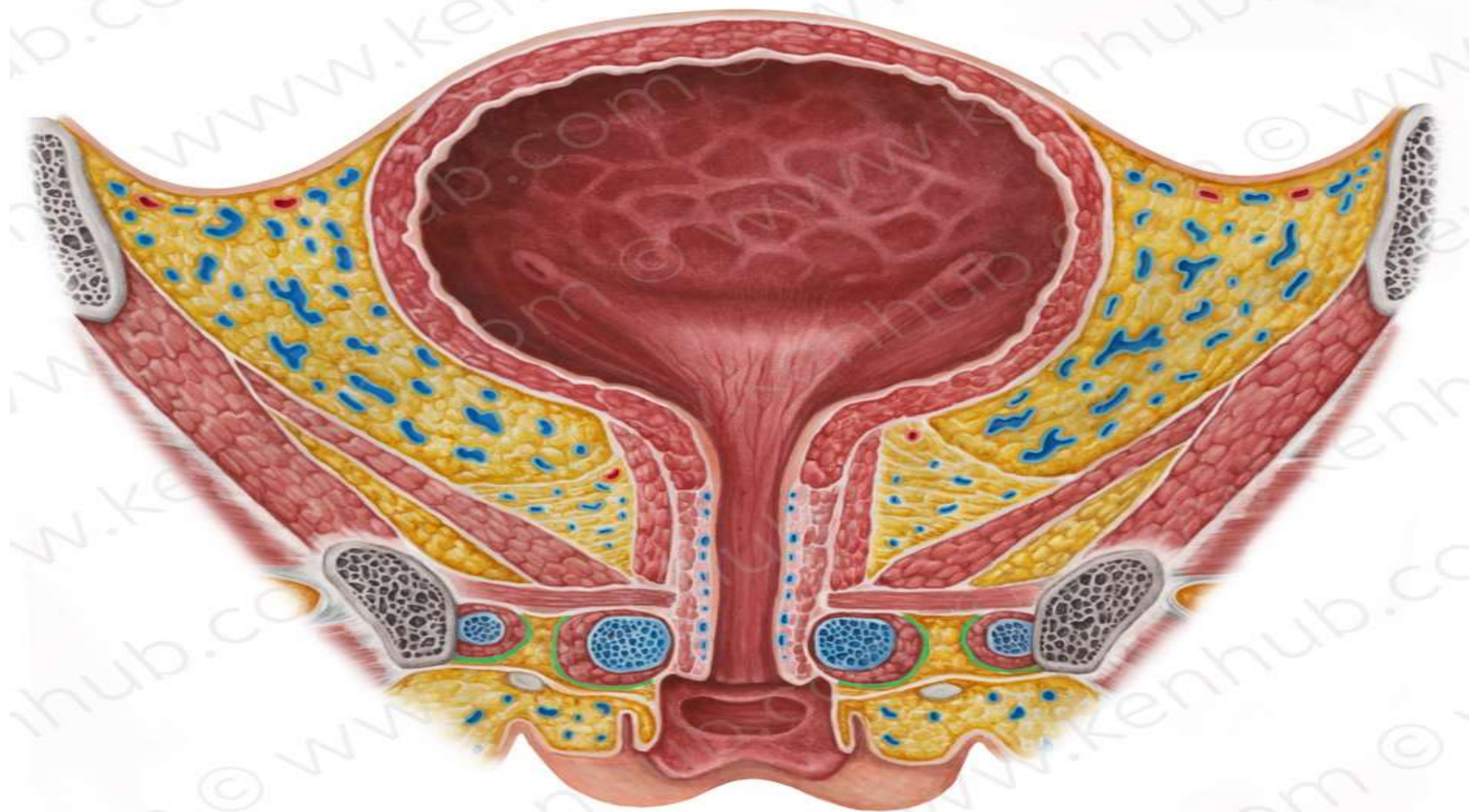


Urinary Bladder Male



© www.kenhub.com

DR AHMED SALMAN



Urinary Bladder Female



© www.kenhub.com

Peritoneal Covering of the Bladder :

- In **male**, the superior surface and the superior part of its base is covered by peritoneum,
- In **females**, only the superior surface is covered by peritoneum.

The peritoneum leaving the bladder is loosely attached to the suprapubic part of abdominal wall.

The distended bladder lifts this peritoneum from the abdominal wall.

 In case of suprapubic cystostomy instruments could be introduced into the distended bladder to avoid injury of the peritoneum

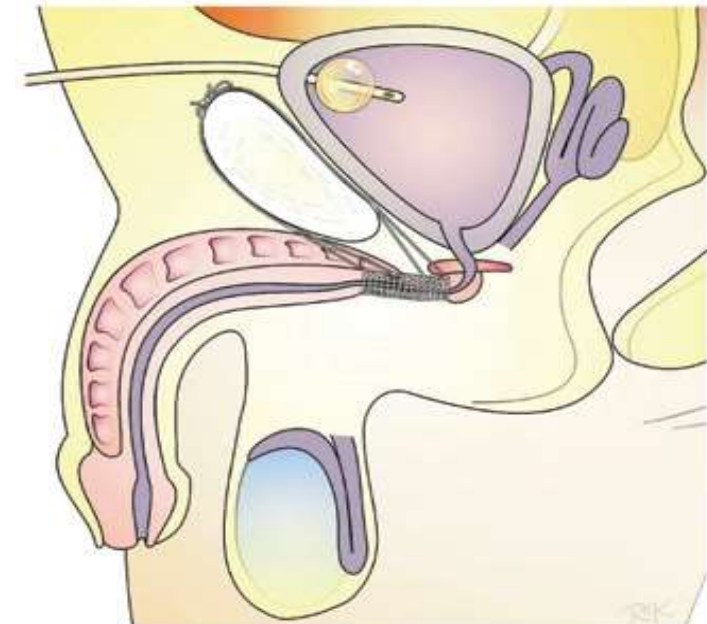


Figure 3 – Schematic drawing of a schematic sagittal section showing how the sutures are passed and fixed anteriorly and posteriorly to the pubis.

The ligaments of the bladder:

1-Median umbilical ligament:

Continuous with apex of the bladder (it is the embryonic urachus)

2-Medial umbilical ligament:

Between superior surface of the bladder (it is the obliterated distal part of superior vesical artery)

3-Puboprostatic and pubovesical ligaments:

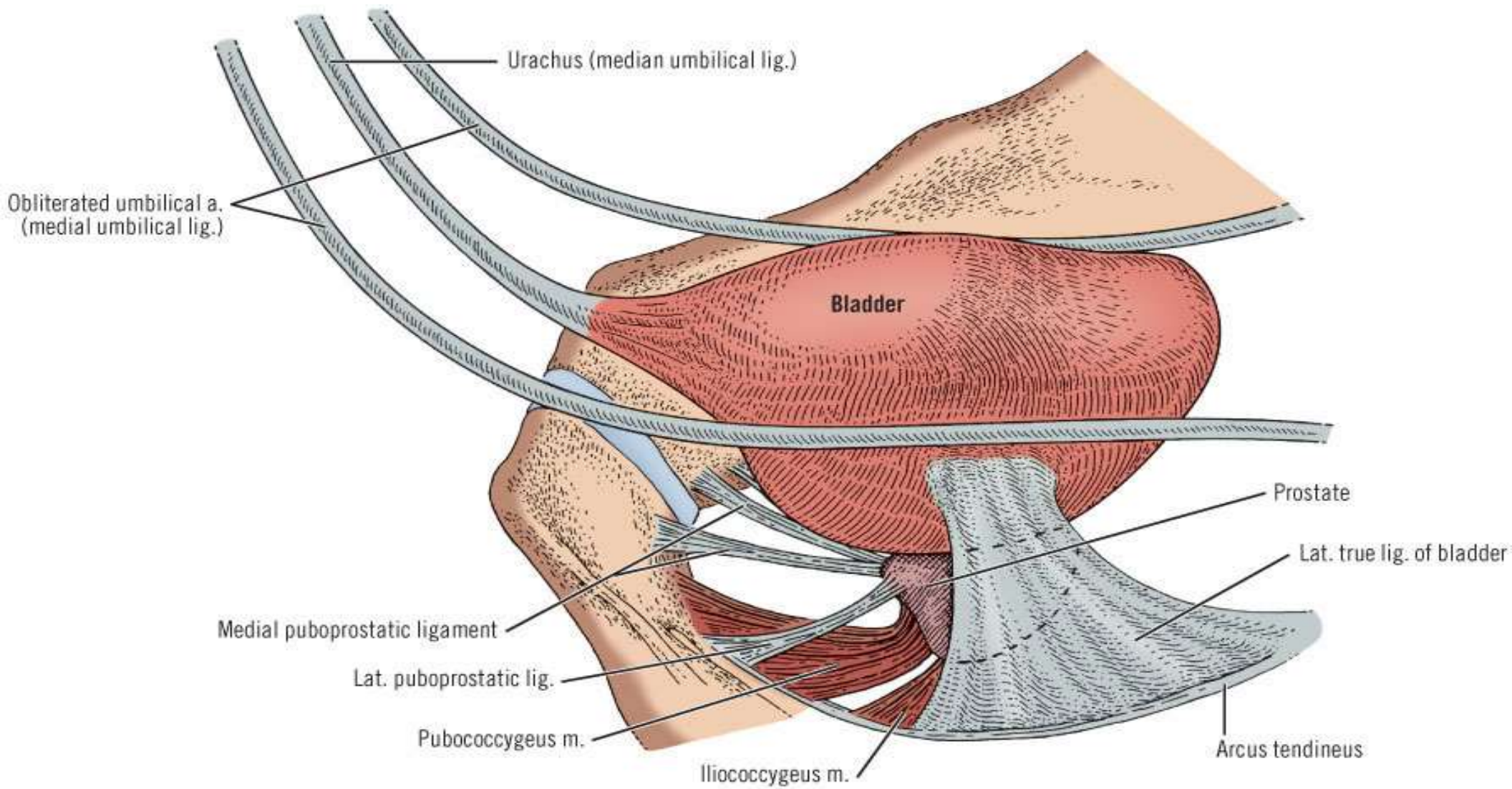
- In the **male**, the puboprostatic ligaments extend from back of the bodies of pubic bones to the anterior surface of the sheath of the prostate and neck of the bladder.
- In the **female**, the pubovesical ligaments extend from pubic bones to the urethra and neck of the bladder.

4-Lateral ligaments of the bladder:

- Each extends laterally from the side of the base of the bladder across the pelvic floor to the tendinous arch in side wall of the pelvis.
- These ligaments enclose arteries and autonomic nerves of the bladder.

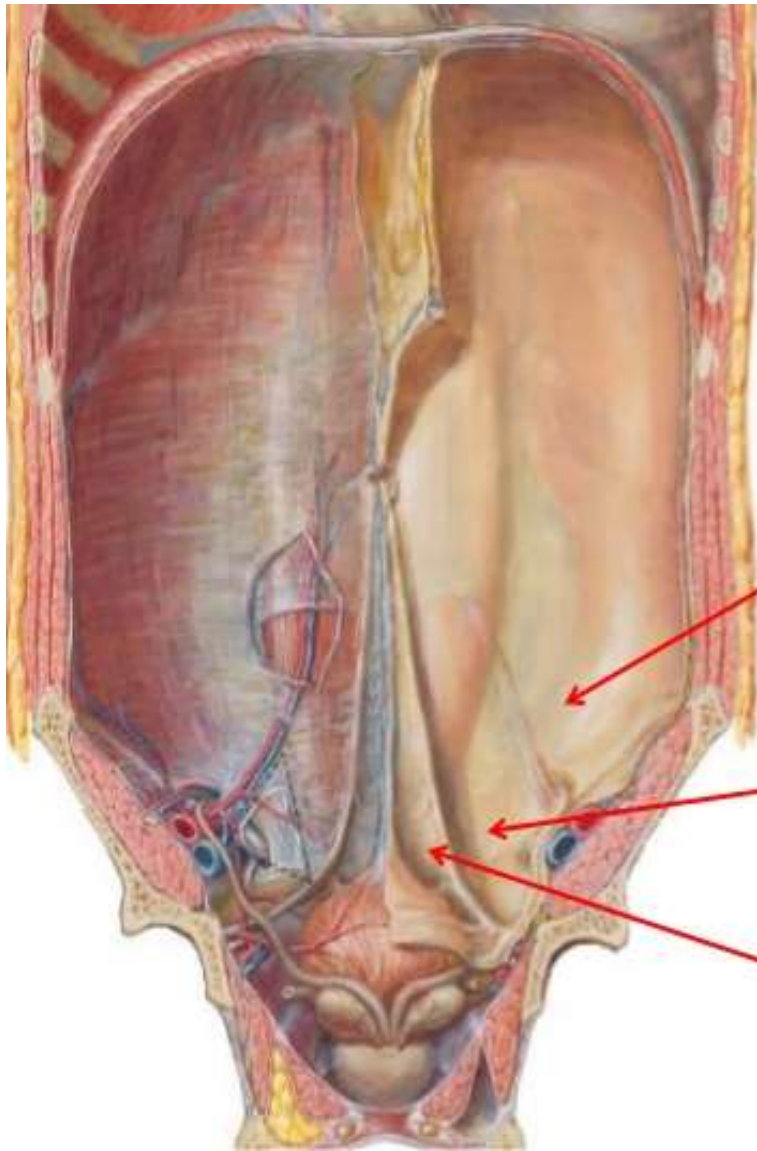
5-Posterior ligaments:

- Each extends backwards from the base of the bladder to the corresponding internal iliac vein.
- They enclose vesical veins in their way to the internal iliac vein.



Copyright ©2006 by The McGraw-Hill Companies, Inc.
 All rights reserved.

Supravesical fossa: Between median umbilical and medial umbilical folds



Lateral Inguinal fossa

Medial Inguinal fossa

Supra-vesical fossa

Interior of the Urinary Bladder :

- The mucous membrane over most of the bladder is loosely attached to the underlying muscular layer (detrusor muscle).
- The mucous membrane is folded in empty bladder, but in distended bladder, the folds disappear.

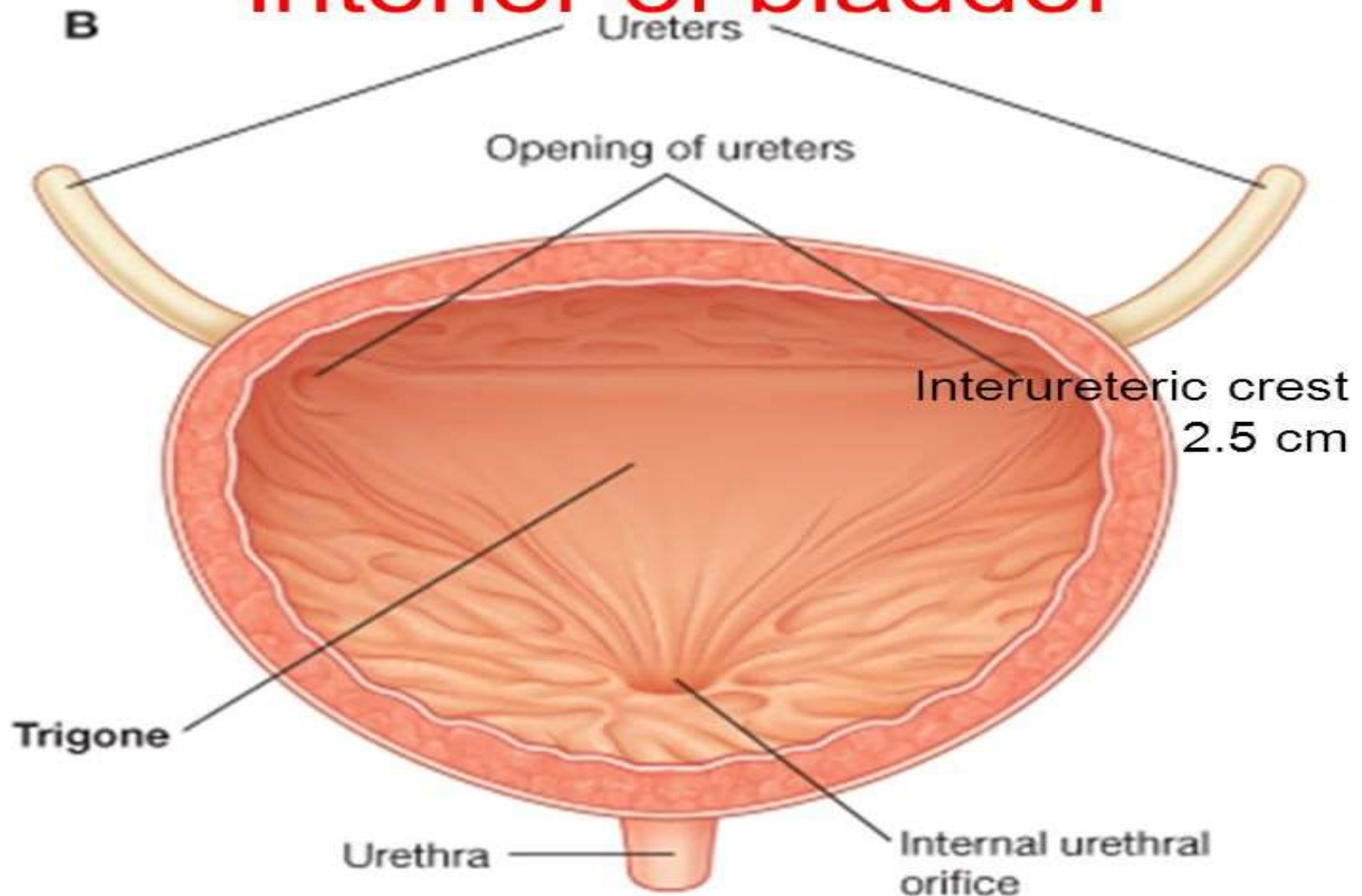
Trigone of the bladder:

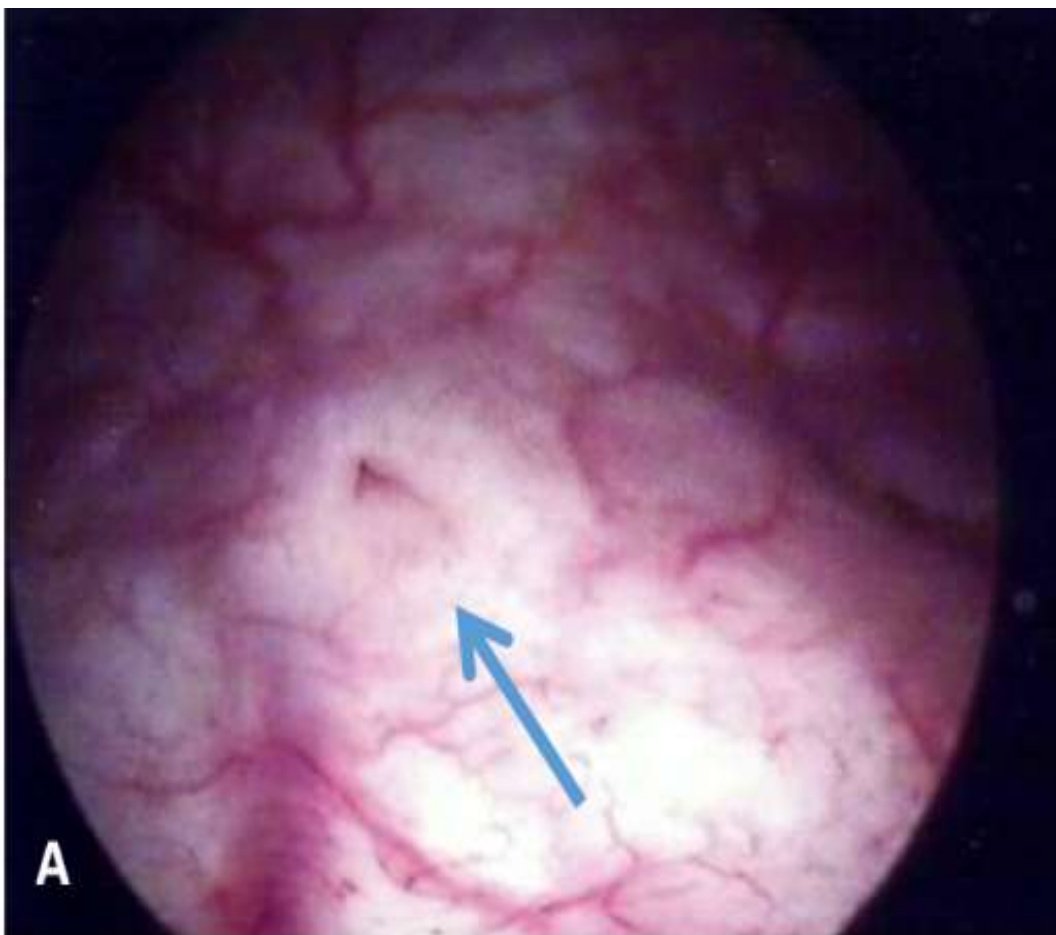
It is the small triangular area which lies between the orifices of the ureters and the internal urethral meatus. (it is mesodermal in origin).

It has the following special features:

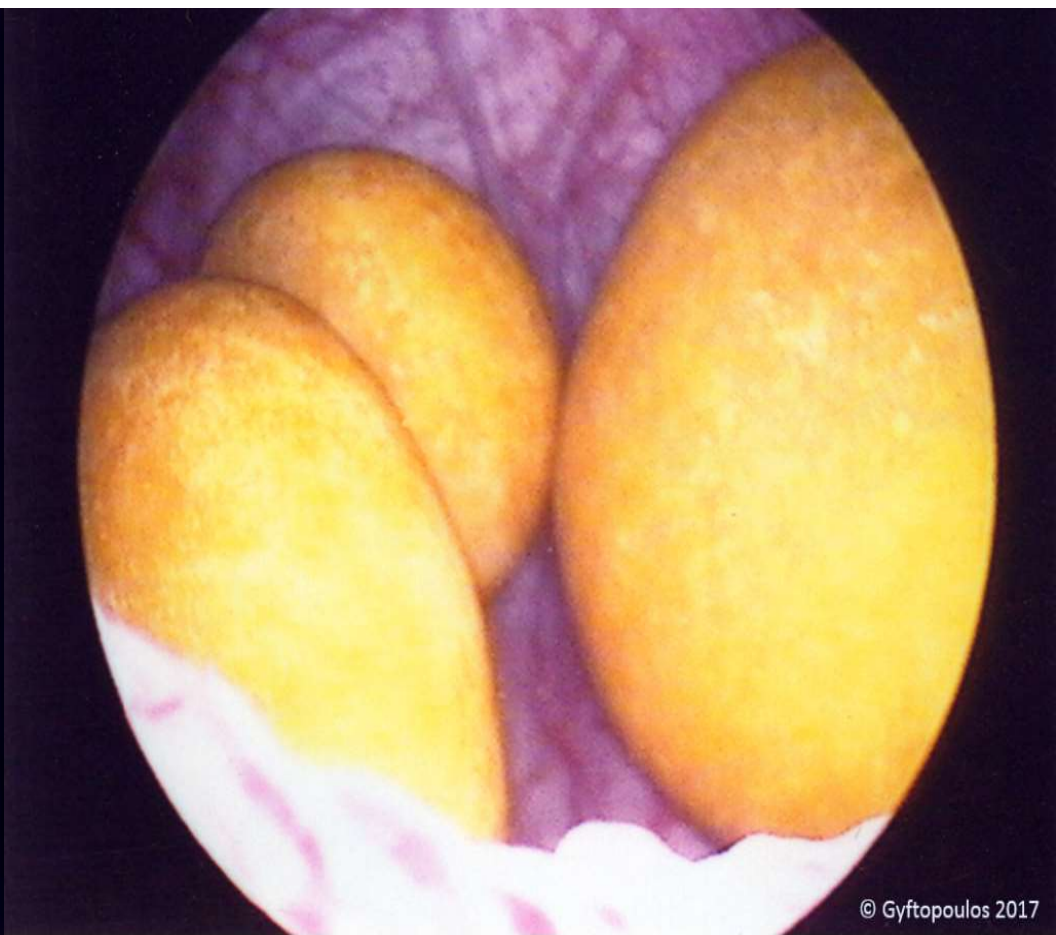- Its superior boundary is formed by the interureteric crest (ridge) which connects the two ureteric orifices.
- Its mucous membrane is always smooth and firmly adherent to the underlying muscle.
- It is very sensitive and vascular, so that, in cystoscope it appears red violet in colour
- In the male, the trigone overlies the median lobe of the prostate.
- After the middle age, the enlarged prostate elevates the mucous membrane behind the internal urethral orifice producing what is known as uvula vesicae of the bladder

Interior of bladder





Endoscopy of urinary bladder
Showing Trigone and ureteric
orifice



Endoscopy of urinary bladder
Showing stones

Arterial Blood Supply:

In the **male**: superior and inferior vesical arteries.

In the **female**: superior vesical and vaginal arteries.

1) Superior Vesical A. (Obliterated Umbilical A.):

- It was the umbilical artery in the fetus
- Its **proximal part is patent** (= superior vesical A.)
- It gives branches to the bladder, ureter and vas deference (In male) .
- Its **distal part is fibrosed** form medial umbilical ligament which form the medial the medial umbilical fold of peritoneum.

2) Inferior Vesical A. (Vaginal A. in the female):

- It supplies base of the urinary bladder, seminal vesicle, prostate and gives artery of the vas which runs in the spermatic cord and anastomoses with the testicular artery.
- **In female**: The vaginal A. supplies the base of the bladder and gives vaginal branches which anastomose with vaginal branches from uterine A.

Arterial Blood Supply:

In the **male**: superior and inferior vesical arteries.

In the **female**: superior vesical and vaginal arteries.

Venous Drainage:

Begins by the vesical venous plexus, embedded in the visceral fascia on the inferolateral surfaces of the bladder.

Inferiorly:

In the **male**: it communicates with the prostatic venous plexus. and receives the Deep dorsal vein of the penis

In the **female**: it communicates with the vaginal venous plexus and receives the deep dorsal vein of the clitoris.

Posteriorly: the plexus is drained by numerous vesical veins which run in the posterior ligaments of the bladder to end in the internal iliac veins.

Vesical venous plexus

Posteriorly

Internal iliac veins

MALE
Prostatic venous plexus
Deep dorsal vein of the penis

FEMALE
Vaginal venous plexus
deep dorsal vein of the clitoris

Lymphatic Drainage:

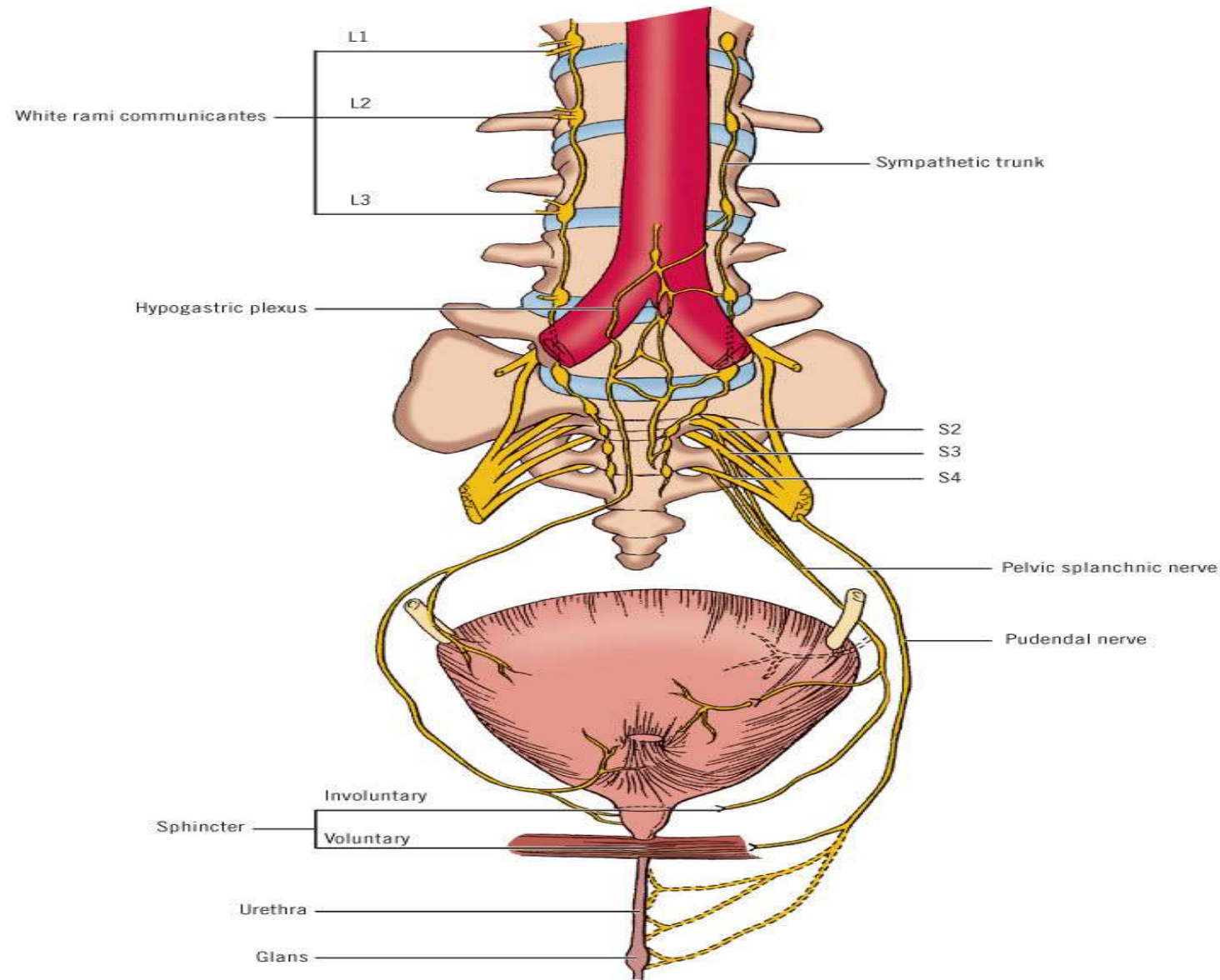
- To internal and external iliac lymph nodes.
- From the bladder neck, lymphatics drain directly to the sacral lymph nodes.

Nerve Supply:

- By vesical nerve plexus, derived from the **inferior hypogastric plexus**, it contains the following fibers :

- ❖ **Parasympathetic efferents** (pelvic splanchnic nerves) (S_2, S_3, S_4): motor to the detrusor muscle, inhibitory to sphincter vesicae (they produce micturition).
- ❖ **Sympathetic efferents**: ($L1, L2$) are inhibitory to detrusor and stimulant to sphincter vesicae .
- ❖ **Sensory afferents**: Reach central nervous system through pelvic splanchnic nerves or Sympathetic fibers
It records bladder distension and pain sensation.

Nerve Supply:



Bladder Injuries

Intraperitoneally

Usually involves the superior wall of the bladder

Most commonly when the bladder is full

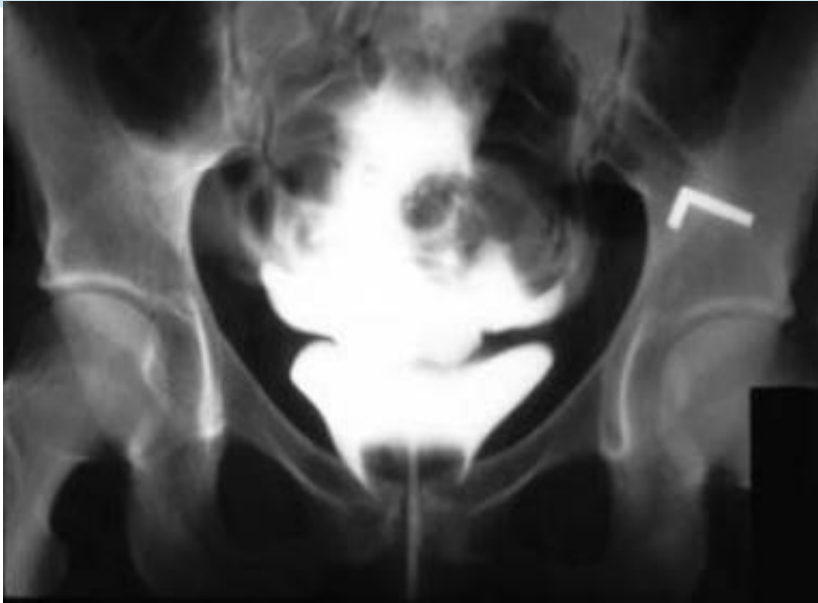Urine and blood escape freely into the peritoneal cavity

Extraperitoneally

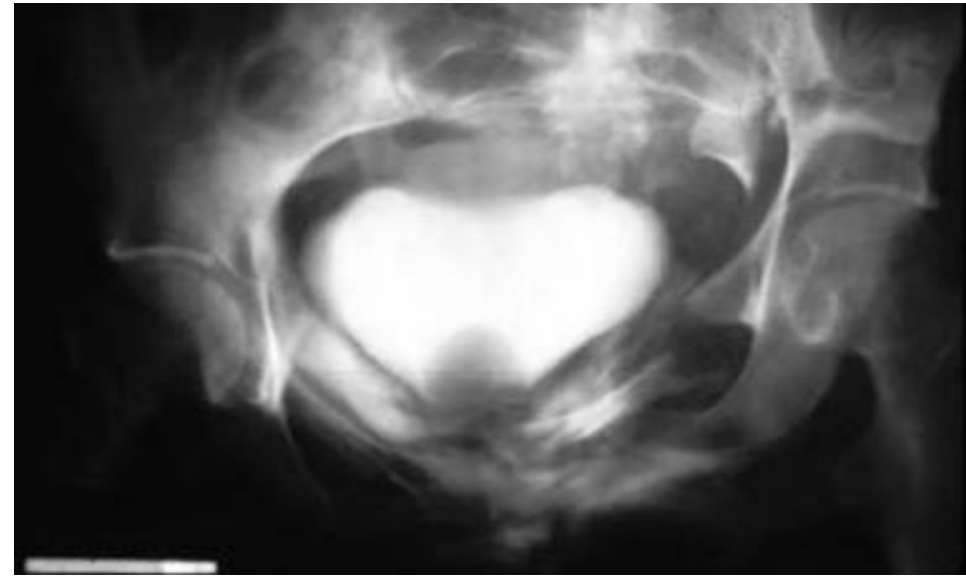Usually involves the anterior part of the bladder wall below the level of the peritoneal reflection

it most commonly occurs in fractures of the pelvis

The patient complains of lower abdominal pain and blood in the urine (hematuria)



Cystogram of **intraperitoneal** bladder rupture. The contrast enters the intraperitoneal cavity and outlines loops of bowel



Cystogram of **extraperitoneal** bladder rupture. The contrast extravasation into the space of Retzius.



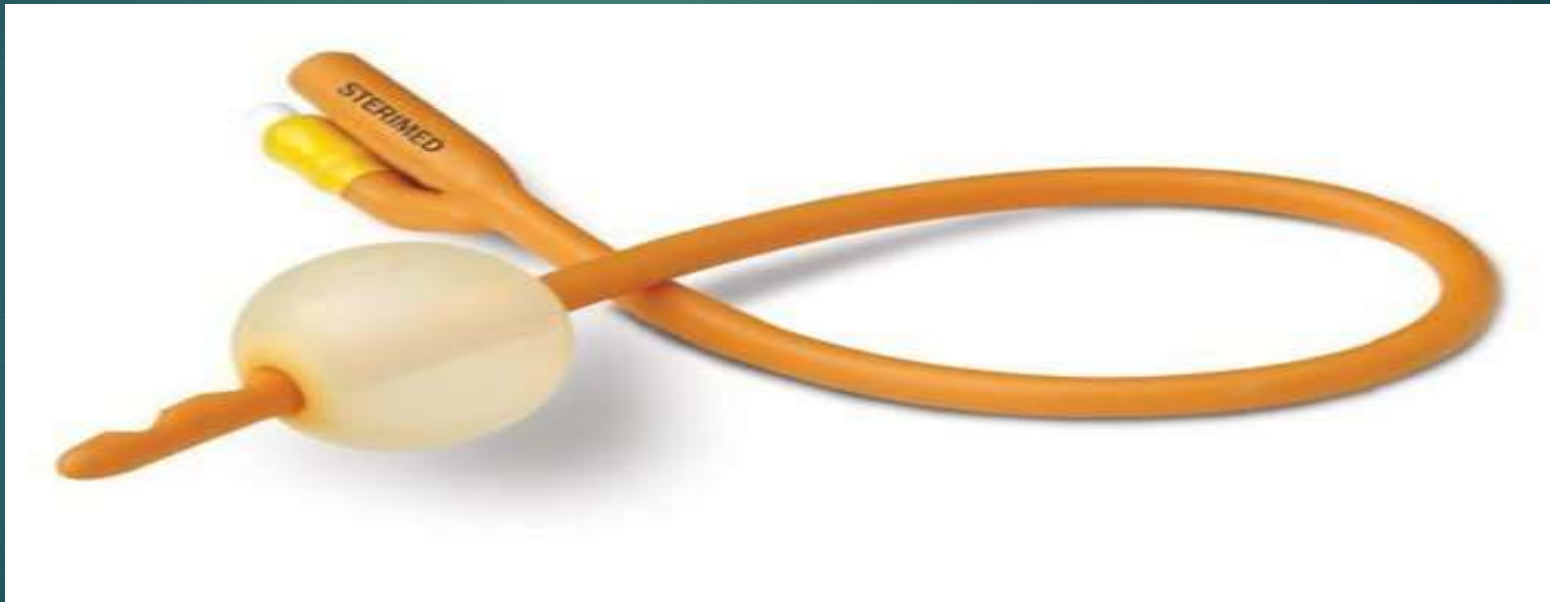
The Urethra

Dr Ahmed Salman

During inserting a foley catheter in a male patient you feel a resistance.

WHY and What you will do ?

What the Difference of size between the cannula and foley catheter ?



Urethra:

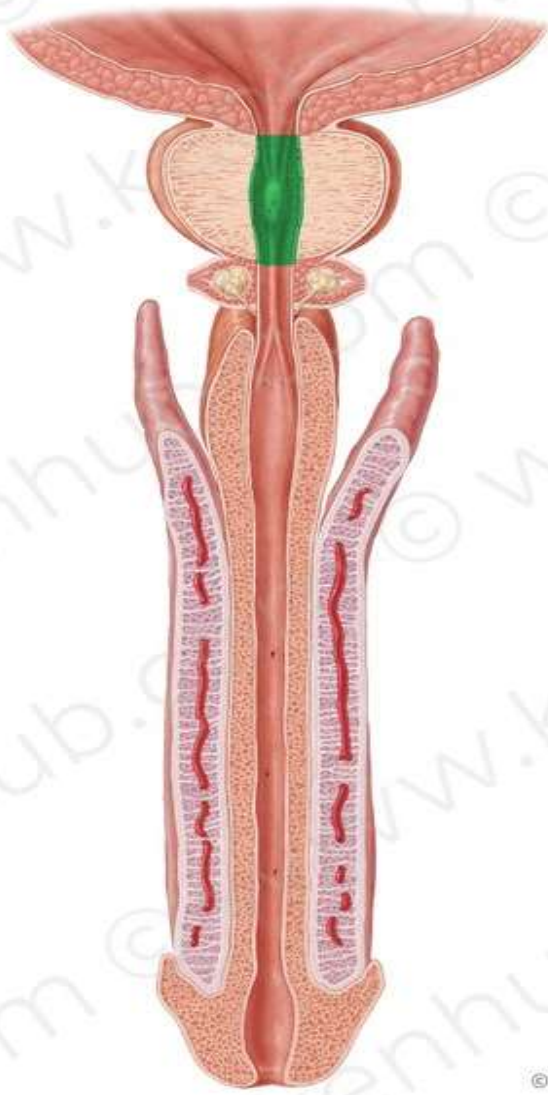
Male Urethra

- ❑ The male urethra is about 20 cm long.
- ❑ It extends between 2 meatuses.
 - **Internal urethral meatus:** at its junction with the neck of the bladder
 - **External urethral meatus:** is a vertical slit, about 6 mm long.
It is the narrowest part of urethra, and a calculus may lodge there.
- ❑ It is divided into 4 parts: the first and the second parts are in the pelvis, the third and fourth parts are in the perineum .
- ❑ It has 2 sphincters:
 - Internal urethral sphincter** (or sphincter vesicae), surrounds the neck of urinary bladder and the **first** (preprostatic) part of the urethra.

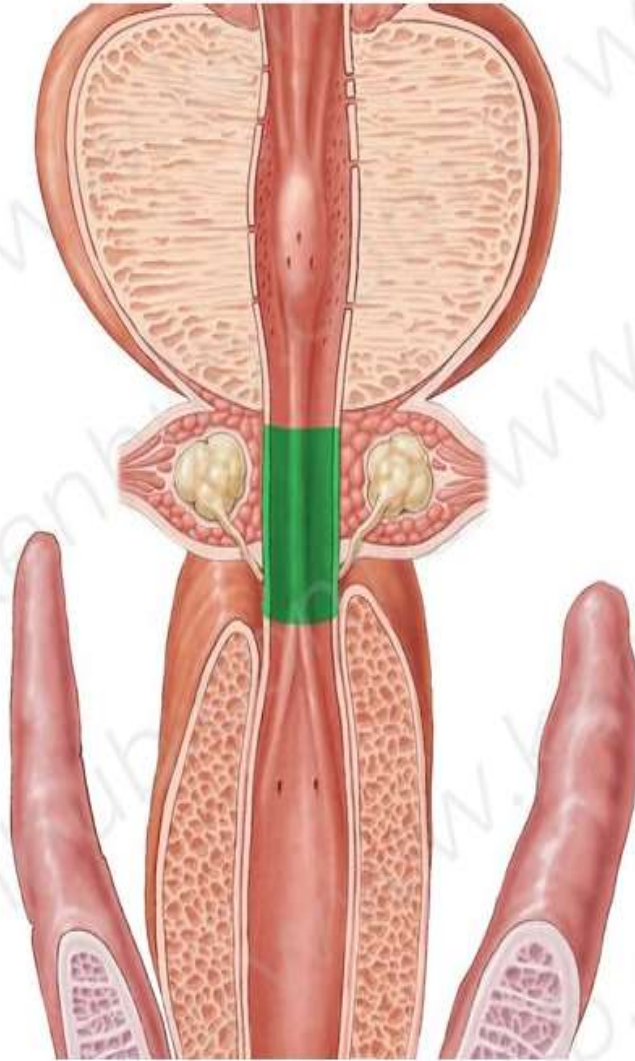
 - External urethral sphincter** (or sphincter urethrae), surrounds the **third** (membranous) part of the urethra

Parts of the Urethra

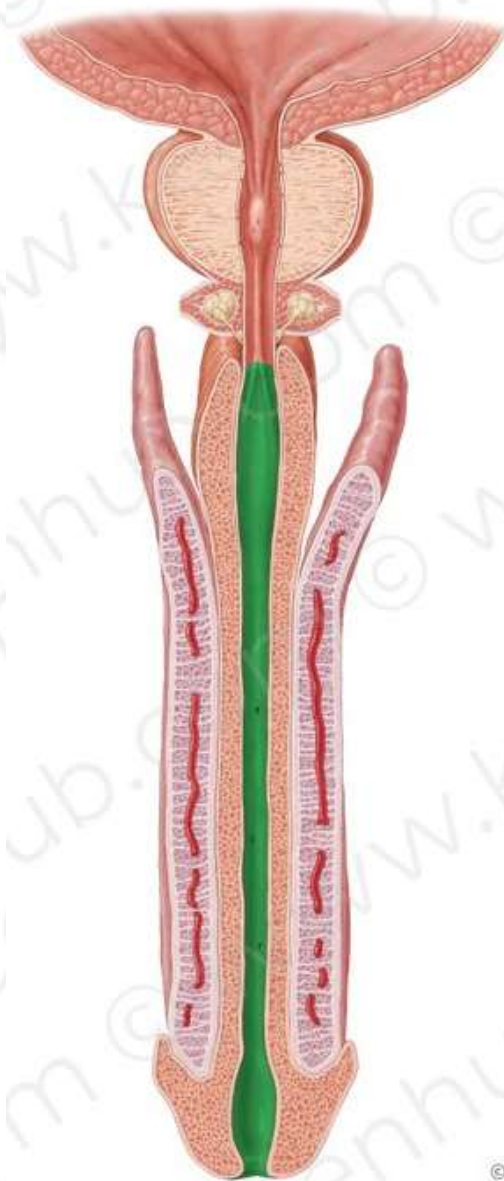
	First part: pre-prostatic part	Second part: prostatic part	Third part : membranous part	Fourth : spongy part
Length	1-1.5 cm	3 cm	2 cm	15 cm
Site	between neck of the bladder and the base of the prostate	traverses prostate from base to apex	runs in deep perineal pouch	bulb of penis and corpus spongiosum (Superficial Perineal Pouch)
Size		it is the widest part of urethra	it is the least dilatable part	
Special features	It is surrounded by internal sphincter	Urethral crest Seminal colliculus Prostatic sinuses	surrounded by external urethral sphincter	-Dilated at its beginning to form to form <u>intra</u>bulbar fossa and at termination in glans penis to form the <u>navicular fossa</u> . -The bulbourethral glands open into its beginning



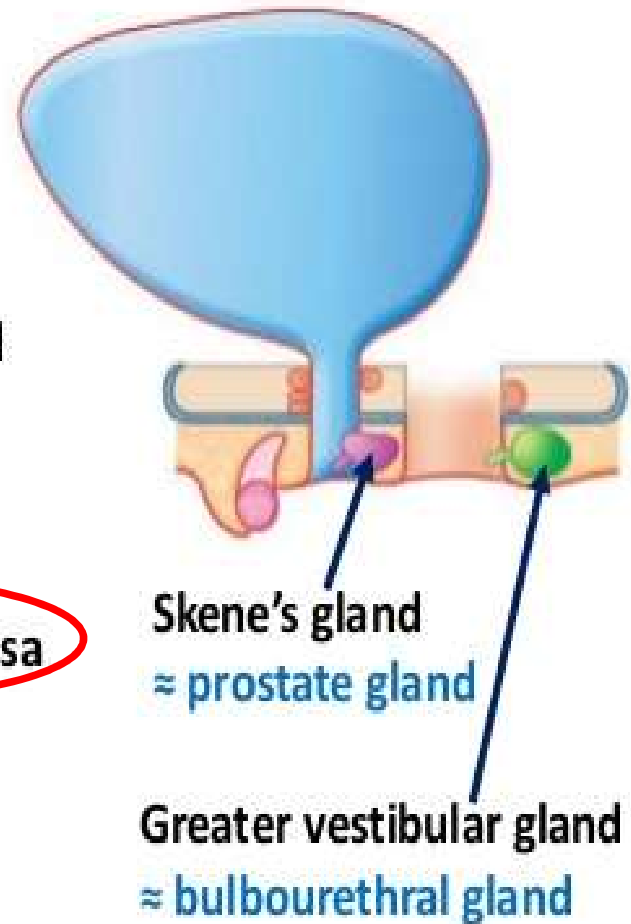
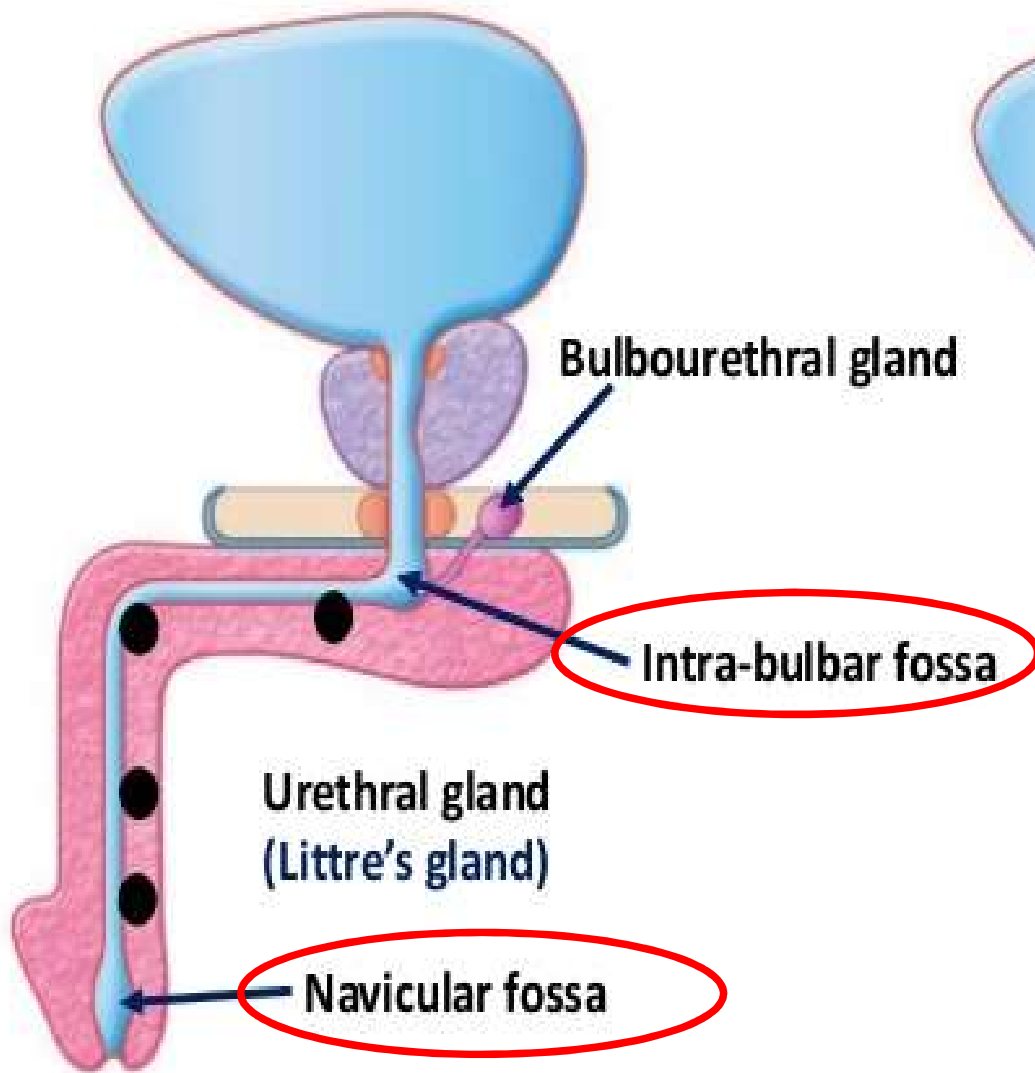
Prostatic part



Membranous part of urethra



Spongy part of urethra



Special features of prostatic part of urethra

Urethral crest:

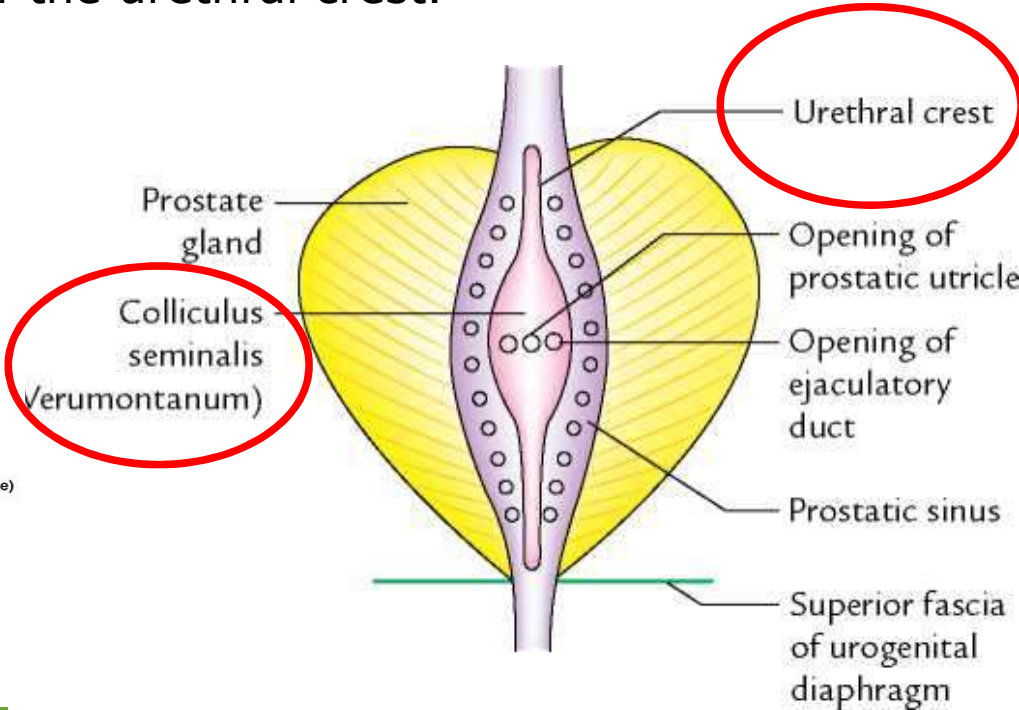
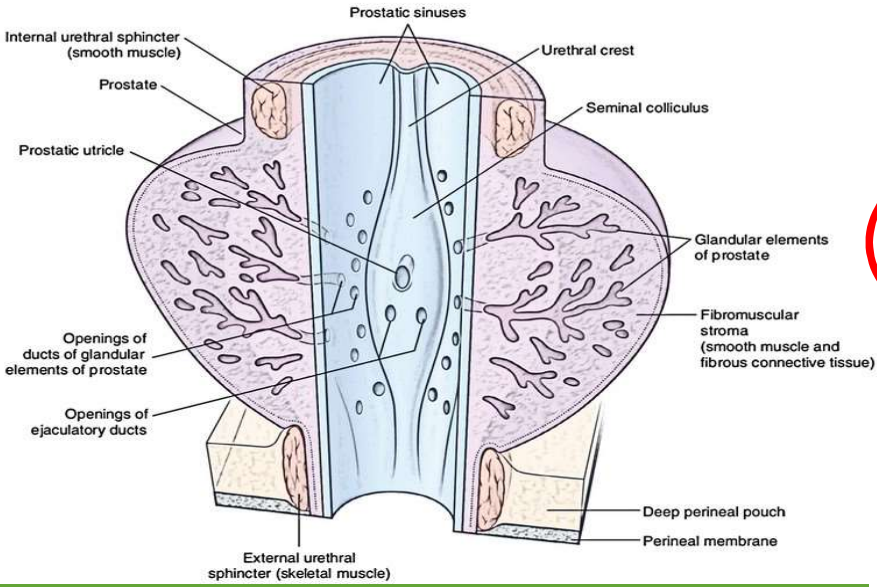
is a median longitudinal elevation in the mucous membrane of its posterior wall.

Seminal colliculus (verumontanum):

- ✓ Is a prominence at the middle of the crest.
- ✓ It has three openings ; the opening of the prostatic utricle in its middle, and the openings of the two ejaculatory ducts on the sides.

Prostatic sinuses :

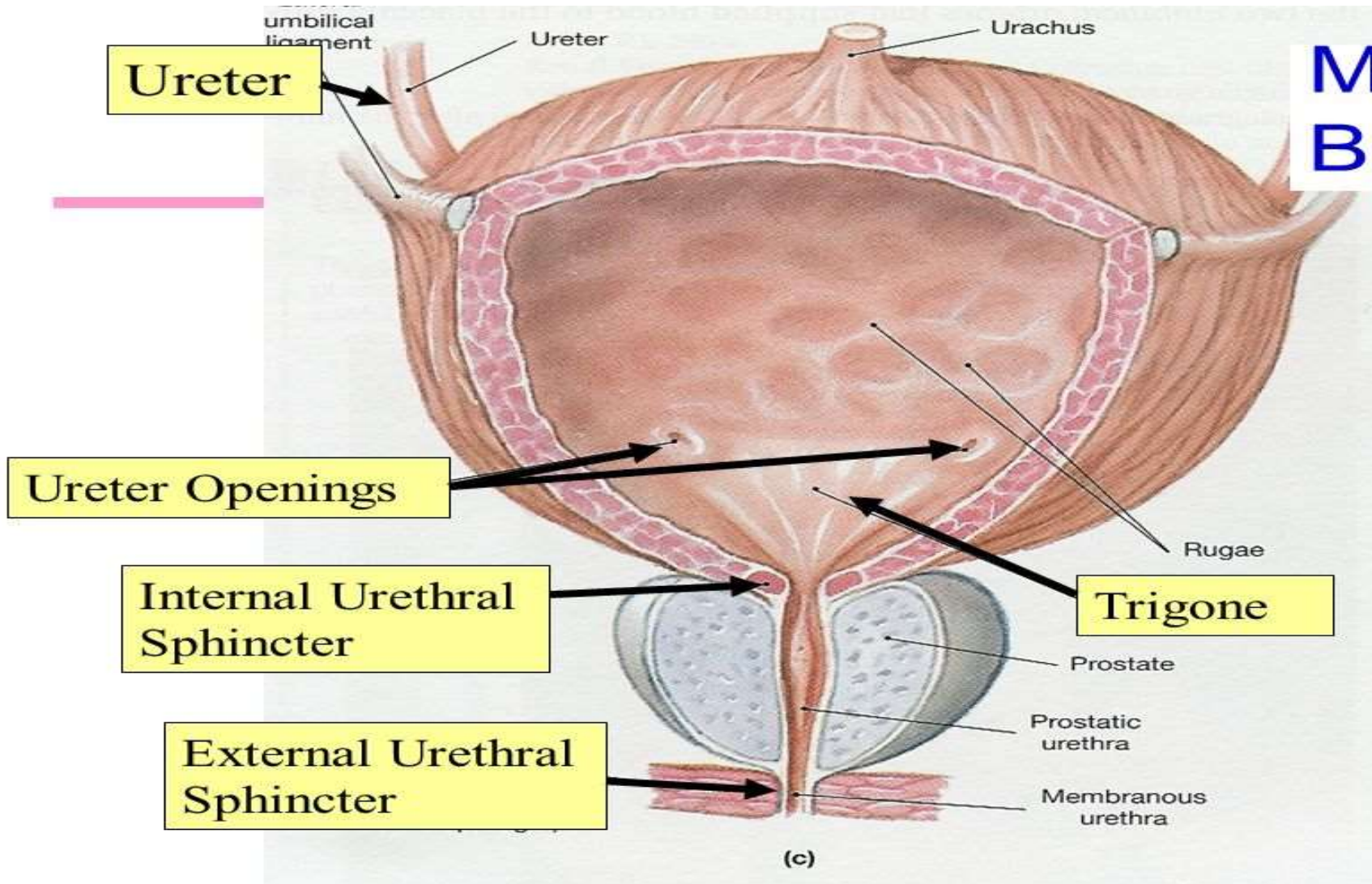
- ✓ Each is a shallow depression on the side of the urethral crest.
- ✓ Each receives 15-20 prostatic ducts.



Sphincters of the Urethra

	Internal Urethral sphincter	External Urethral sphincter
Site	It lies in pelvis around neck of the bladder and pre-prostatic part of the urethra.	It lies in the perineum, surrounds the membranous urethra in the deep perineal pouch.
Structures	It is formed of smooth muscle fibers	It is formed of striated muscle fibers
Nerve Supply	Autonomic fibers from the inferior hypogastric plexus	Somatic : from the perineal branch of pudendal nerve of the sacral plexus
Functions	<ul style="list-style-type: none"> ❖ It acts Involuntarily. ❖ It is well-developed in both male and female. ❖ It maintains continence of urine. <p><u>In the male:</u> it has a genital function, it prevents reflux of semen into the urinary bladder during ejaculation</p>	<ul style="list-style-type: none"> ❖ It acts voluntarily. ❖ It is well-developed in the male ❖ It maintains continence of urine.

Male Bladder



Vessels Nerves and Lymphatics of the urethra :

Urethra receives its blood and nerve supply from those of prostate and penis.

Lymphatics:

From the *prostatic and membranous* parts to **internal and external iliac.**

lymph nodes From the *spongy* part to **deep and superficial inguinal lymph nodes.**

Urinary Retention

It is more common in **male** due to a benign or malignant enlargement of the prostate or acute urethritis or prostatitis .

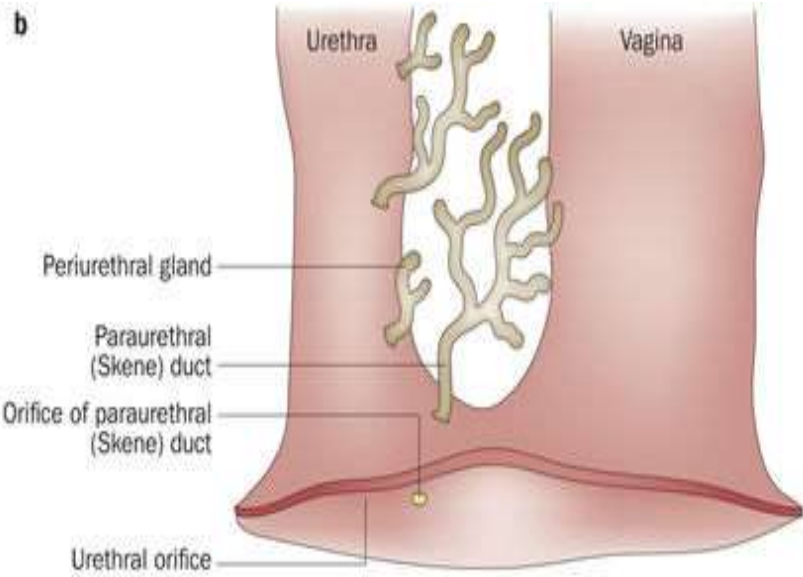
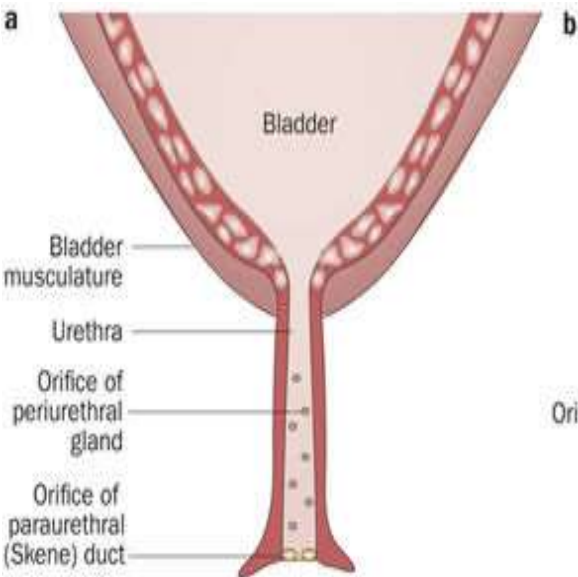
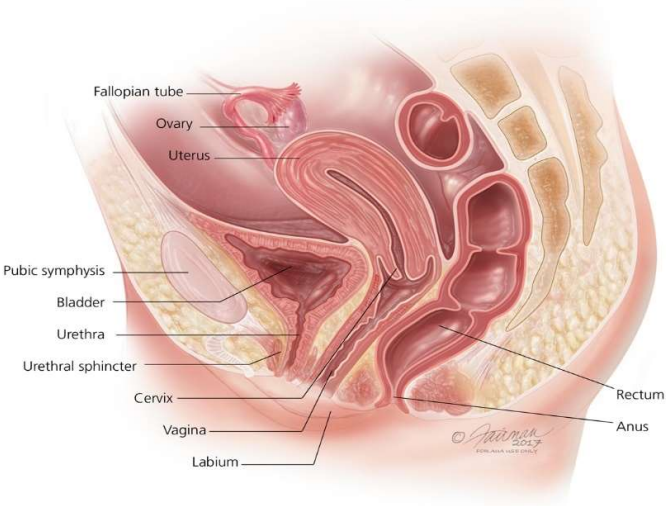
The only anatomic cause of urinary retention in **females** is acute inflammation around the urethra (e.g., from herpes).

Female Urethra :

length : 4 cm.

Course. Relations:

- It begins at the internal urethral meatus at the neck of the bladder.
- It traverses the deep perineal pouch to end at the external urethral orifice in the vestibule anterior to the vaginal orifice.
- It is embedded in the anterior wall of the vagina.
- On each side of the urethra, the mucous membrane of the urethra presents a number of small mucous glands called the paraurethral glands which correspond to the prostate in the male.



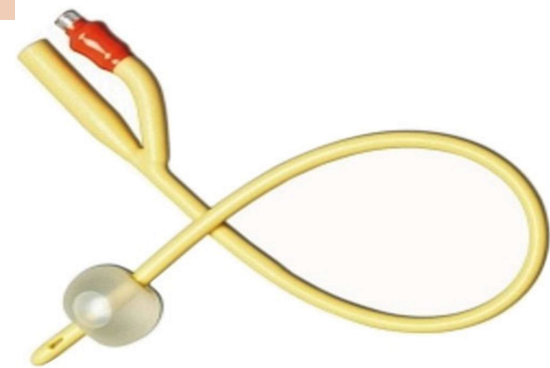
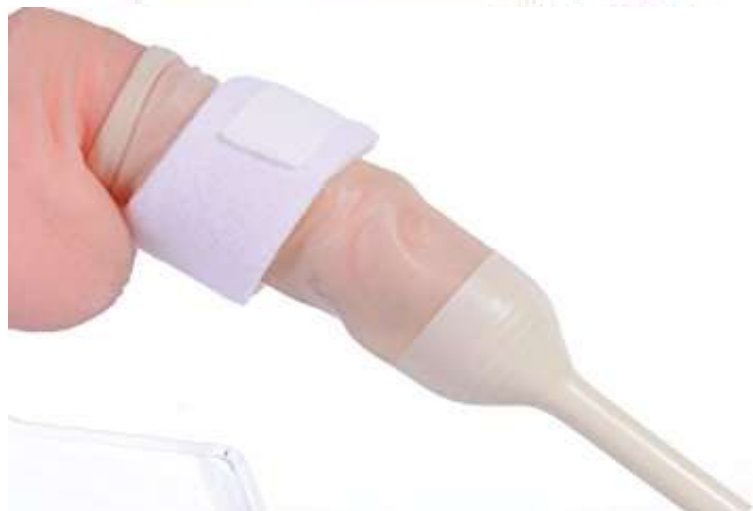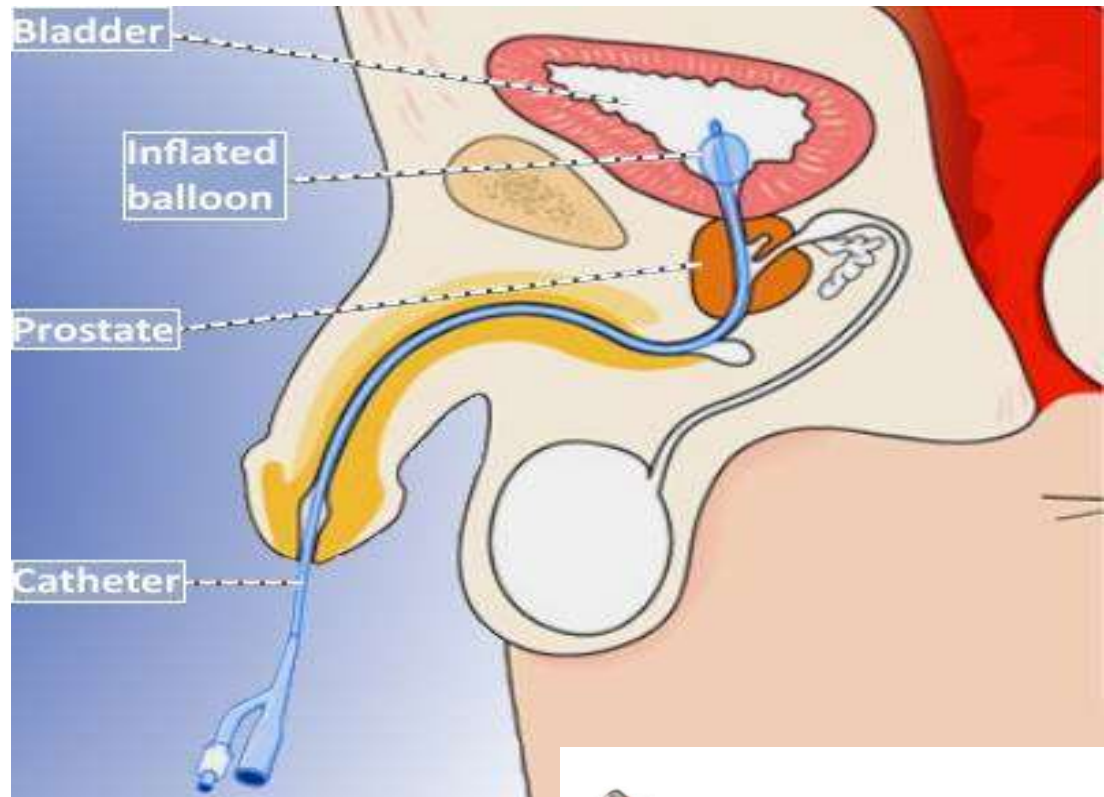
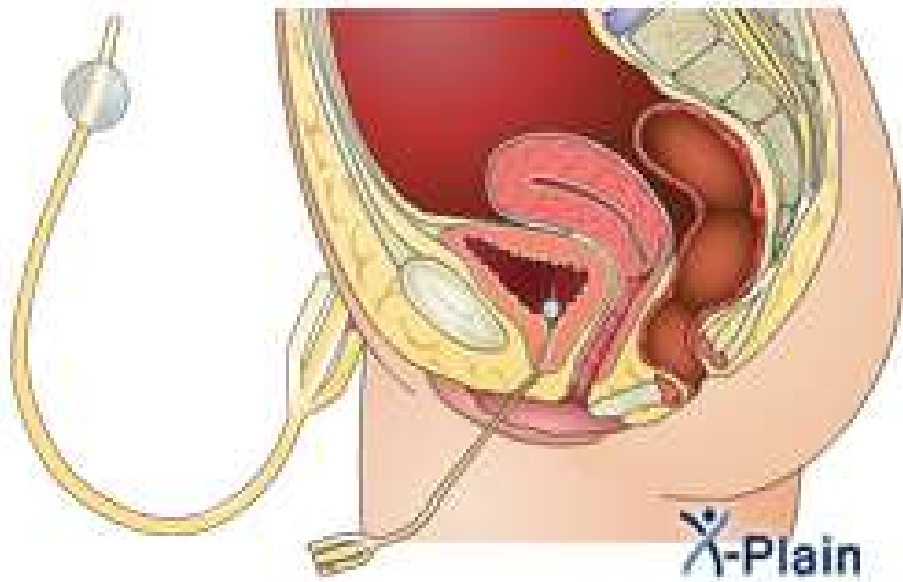
Clinically Significant Differences Between Male and Female Urethrae:

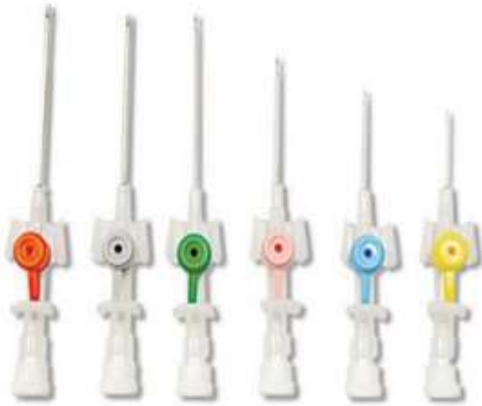- The female urethra is distensible because it contains considerable elastic tissue, as well as smooth muscle.
- It can be easily dilated without injury.
- Infections of the urethra, and bladder, are more common in women because the female urethra is short, more distensible, and is open to the exterior.

Anatomy of the Procedure of Catheterization


REED ONLY

- 1.** The patient lies in a supine position.
- 2.** With gentle traction, the penis is held erect at right angles to the anterior abdominal wall. The lubricated catheter is passed through the narrow external urethral meatus. On reaching the membranous part of the urethra, a slight resistance is felt because of the tone of the urethral sphincter and the surrounding rigid perineal membrane.
- 3.** The penis is then lowered toward the thighs, and the catheter is gently pushed through the sphincter
- 4-**Passage of the catheter through the prostatic urethra and bladder neck should be easily.





Cannula Size



Foley's Color Code

IV Cannula Sizes & Colors

Gauge	Colour Code	Ext. Dia. mm	Length mm	Flow Rate ml/min	Indications
14G	Orange	2.1	45	240	Trauma, surgical procedures
16G	Grey	1.8	45	180	Trauma, surgical procedures
18G	Green	1.3	32/45	90	Trauma, quick blood transfusion
20G	Pink	1.1	32	60	Normal IV or blood transfusion
22G	Blue	0.9	25	36	Children, older adults
24G	Yellow	0.7	19	20	Neonates, children, old elderly
26G	Violet	0.6	19	13	Neonates

COLOR	SIZE FRENCH	SIZE MILLIMETER
orange	6	2.0
red	8	2.7
yellow	10	3.3
white	12	4.0
green	14	4.7
orange	16	5.3
red	18	6.0
yellow	20	6.7
purple	22	7.3
blue	24	8.0
black	26	8.7

Thank you!

