



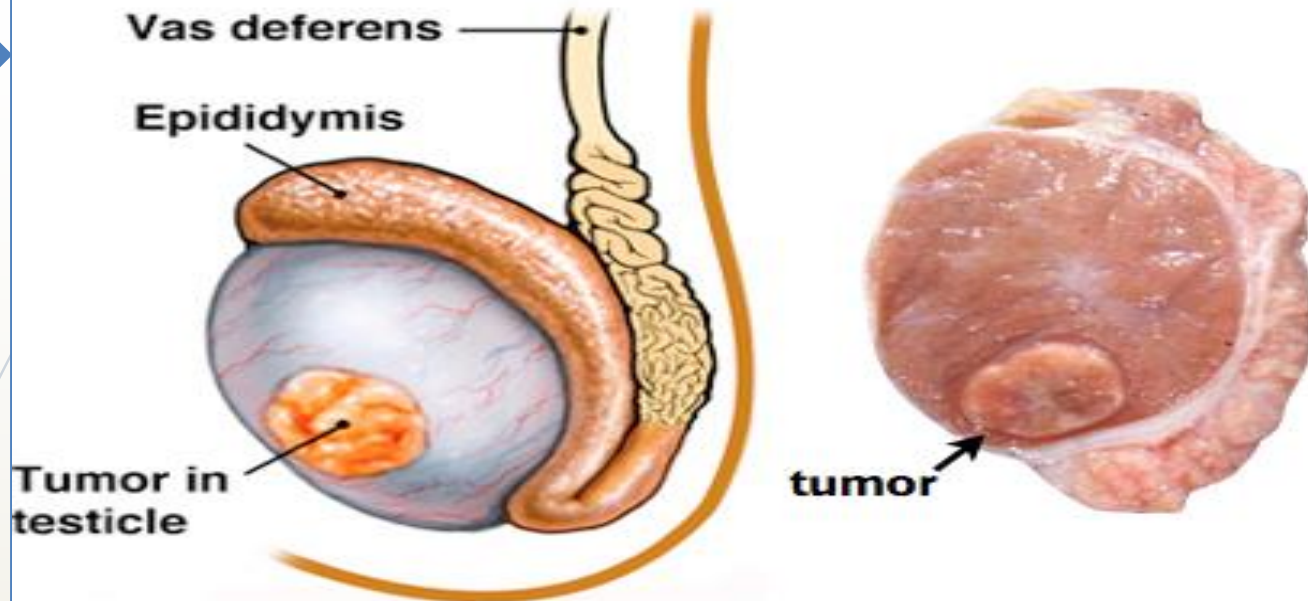
Testicular and prostatic tumors

Dr. Nisreen Abu Shahin

Department of Pathology

Faculty of Medicine, University of Jordan

Testicular Cancer



- Most common in ages 20–35 years
- Painless, firm, hard, fixed scrotal mass
- Ultrasound

The most common tumors in young men <40 years; causes 10% of cancer deaths

include:

I. Germ cell tumors : (95%); *all are malignant in postpubertal males*

II. Sex cord-stromal tumors: (5%); generally benign.

Testicular germ cell tumors are sub-classified into:

I. Seminomas

II. Non-seminomatous germ cell tumors(NSGCT)

- embryonal ca
- yolk sac tumor
- choriocarcinoma
- teratoma

• The histologic appearances may be:

1. **Pure** (i.e. composed of a single histologic type; 40% of cases)
2. **Mixed** (60% of cases).



RISK FACTORS:

1. whites > blacks

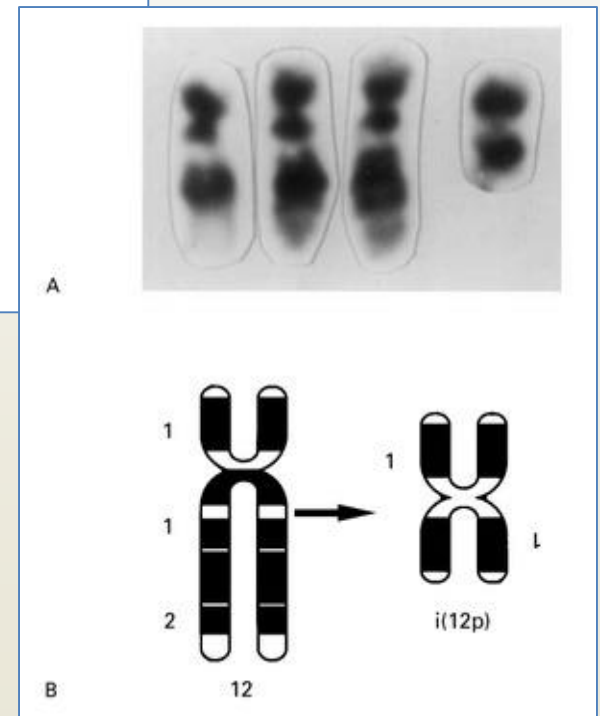
2. Cryptorchidism :

(3-5 folds risk of cancer in undescended testis, and an increased risk of cancer in contralateral descended testis).

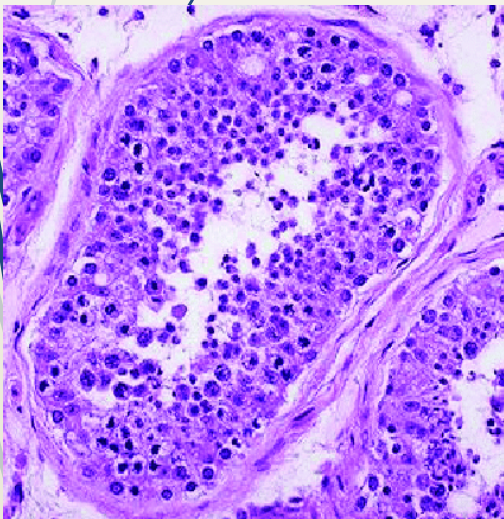
3. Intersex syndromes: e.g. Androgen insensitivity syndrome; Gonadal dysgenesis

4. Family history: relative risk is higher than normal in fathers, brothers, and sons of affected patients

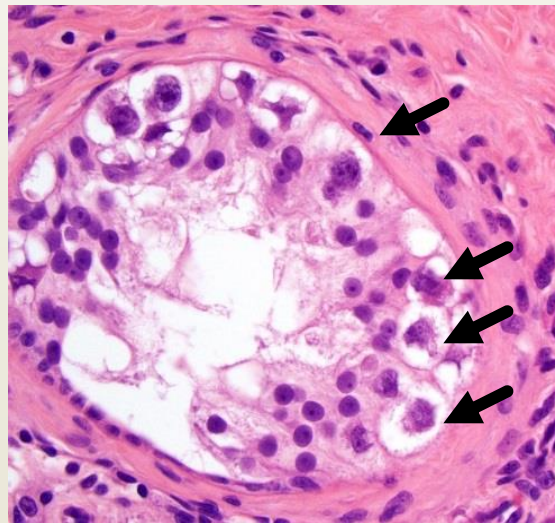
5. The development of cancer in one testis markedly increase risk of neoplasia in the contralateral testis.
6. An isochromosome of the short arm of chromosome 12, $i(12p)$, is found in virtually all germ cell tumors, regardless of their histologic type.



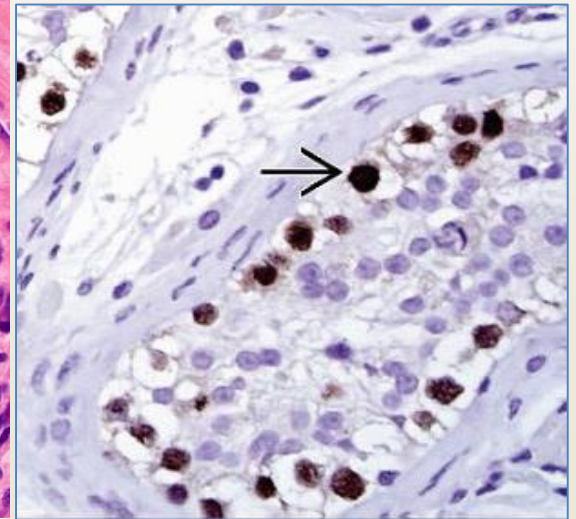
7. Most testicular tumors in postpubertal males arise from the in situ lesion “*intratubular germ cell neoplasia*”



Normal



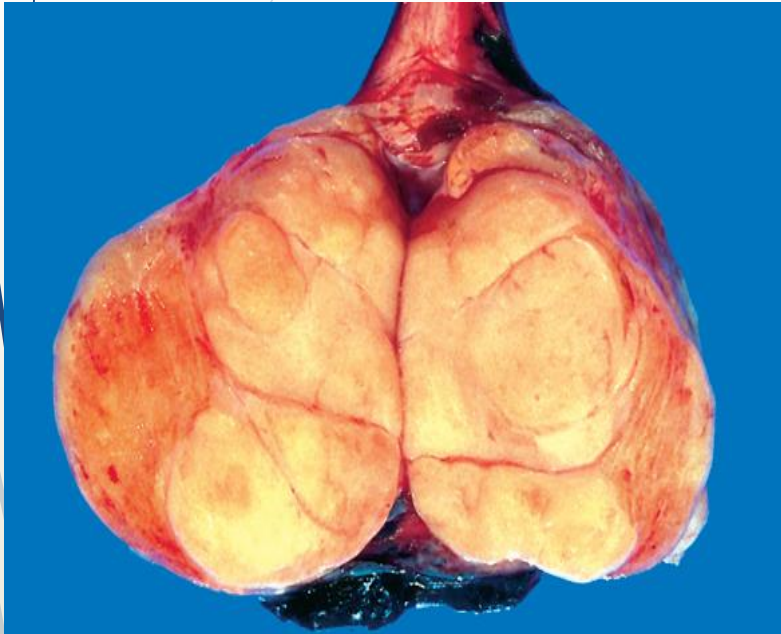intratubular germ cell neoplasia (ITGN)



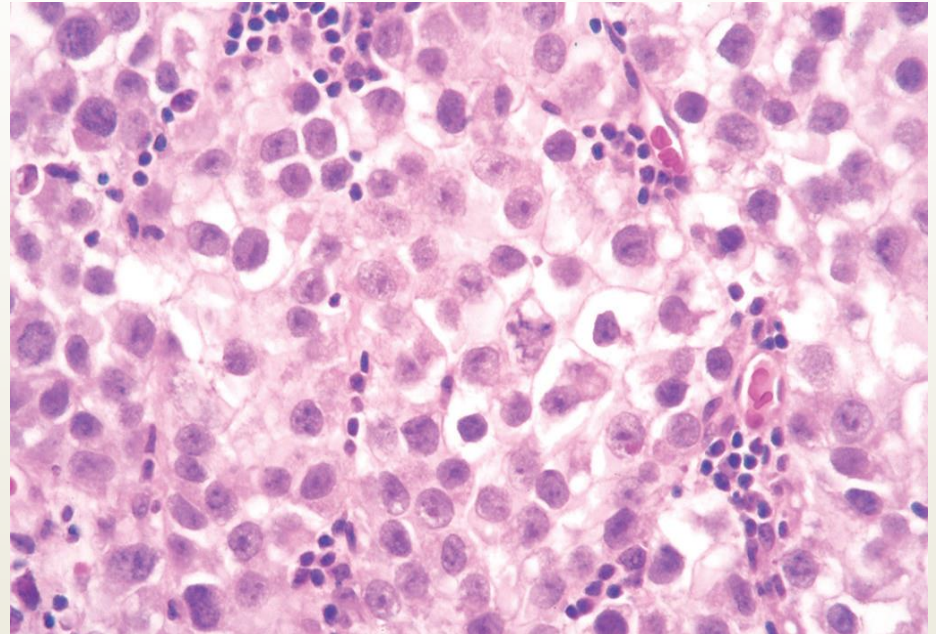
I. Seminoma:

- **Make up to 50% of all testicular tumors**
- ***Classic seminoma:***
 - 40-50 years old
 - Rare in prepubertal children
 - Progressive painless enlargement of the testis
 - Histologically identical to ovarian dysgerminomas and to germinomas occurring in the CNS and other extragonadal sites.

1. Seminoma

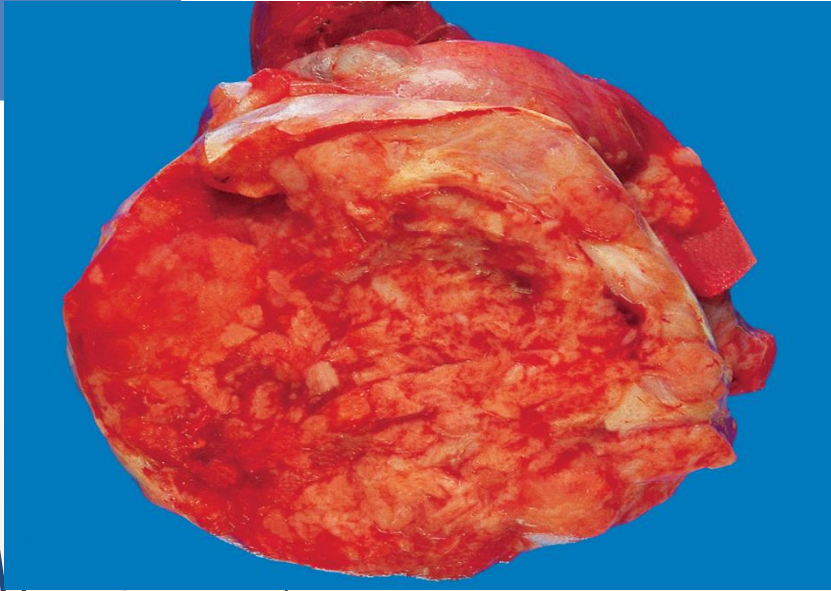


Seminoma :circumscribed, pale, fleshy, homogeneous mass; usually without hemorrhage or necrosis.

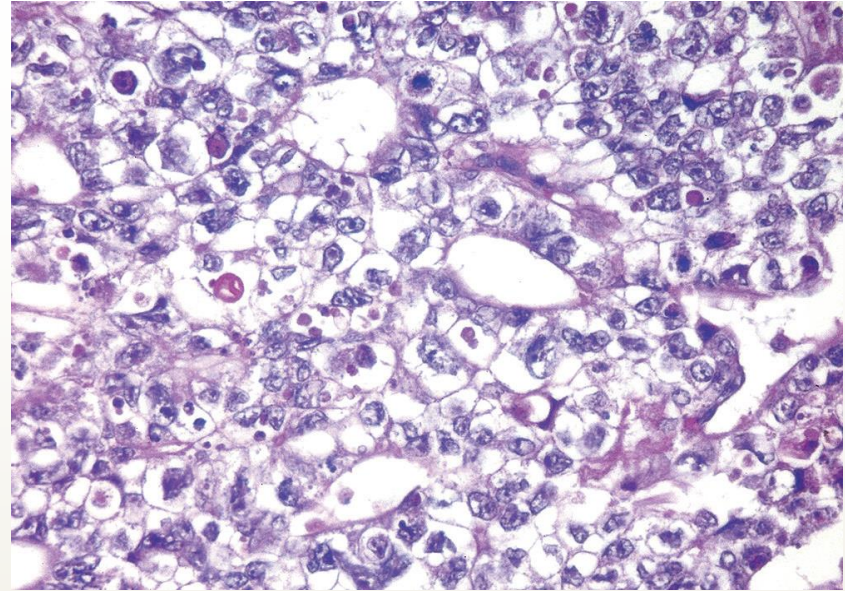


Microscopic examination reveals large cells with distinct cell borders, pale nuclei, prominent nucleoli, and lymphocytic infiltrate.

2. Embryonal carcinoma



ill-defined masses containing foci of hemorrhage and necrosis



Sheets of undifferentiated cells & primitive gland-like structures. The nuclei are large and hyperchromatic with prominent nucleoli, and increased mitotic activity

- **20-30 years old**
- **More aggressive than seminoma**

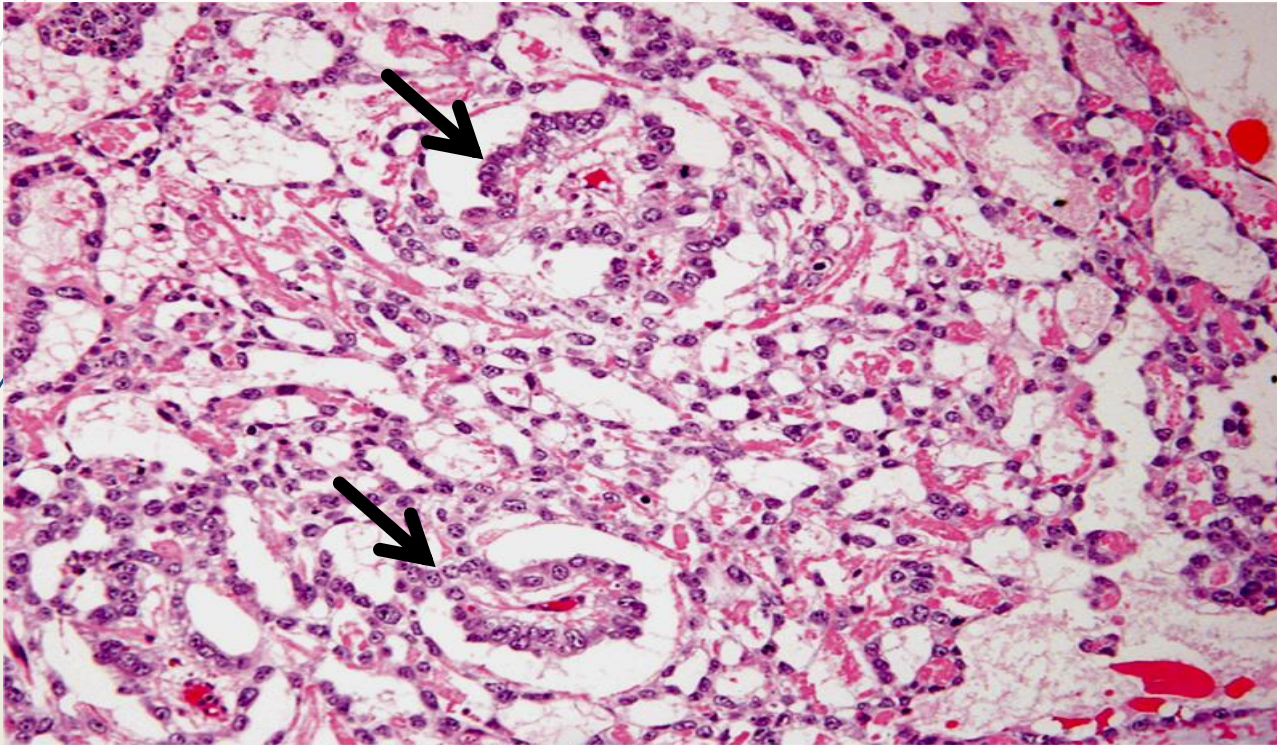
3. Yolk sac tumors

- ➔ The most common primary testicular neoplasm in **children** <3 year
- ➔ good prognosis in young children
- ➔ In adults, pure form of yolk sac tumors is rare and have a worse prognosis

Yolk sac tumors macroscopically:

- ➔ large and may be well demarcated.
- ➔ **Histologically:**
 - The tumor is composed of low cuboidal to columnar epithelial cells forming Microcysts, Lacelike (reticular) patterns.
 - A distinctive feature is the presence of structures resembling primitive glomeruli, called **Schiller-Duvall bodies**.
 - **Alpha-feto-protein (AFP)** usually detected in serum.

3. Yolk sac tumor (arrows: Schiller-Duval bodies)



Kumar et al: Robbins Basic Pathology, 9e.
Copyright © 2013 by Saunders, an imprint of Elsevier Inc.

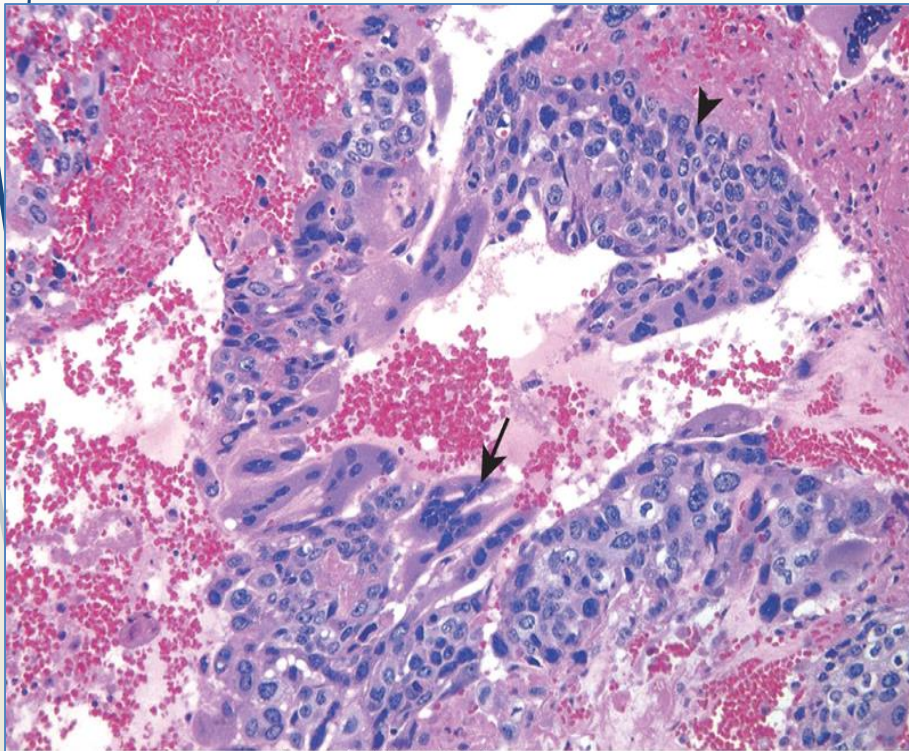
4. Choriocarcinomas

- 20-30 years old
- highly malignant form of testicular tumor.
- its “pure” form is rare, constituting less than 1% of all germ cell tumors; usually mixed with other germ cell tumors
- can also arise in the female genital tract
- Elevated serum level of **HCG**.

Choriocarcinoma

Arrow: Syncytiotrophoblast

Arrow head: Cytotrophoblast



Kumar et al: Robbins Basic Pathology, 9e.
Copyright © 2013 by Saunders, an imprint of Elsevier Inc.

Macroscopically:

- The primary tumors often are small (<5cm) , palpable nodule with no testicular enlargement, even in patients with extensive metastatic disease.
- necrosis and hemorrhage are extremely common

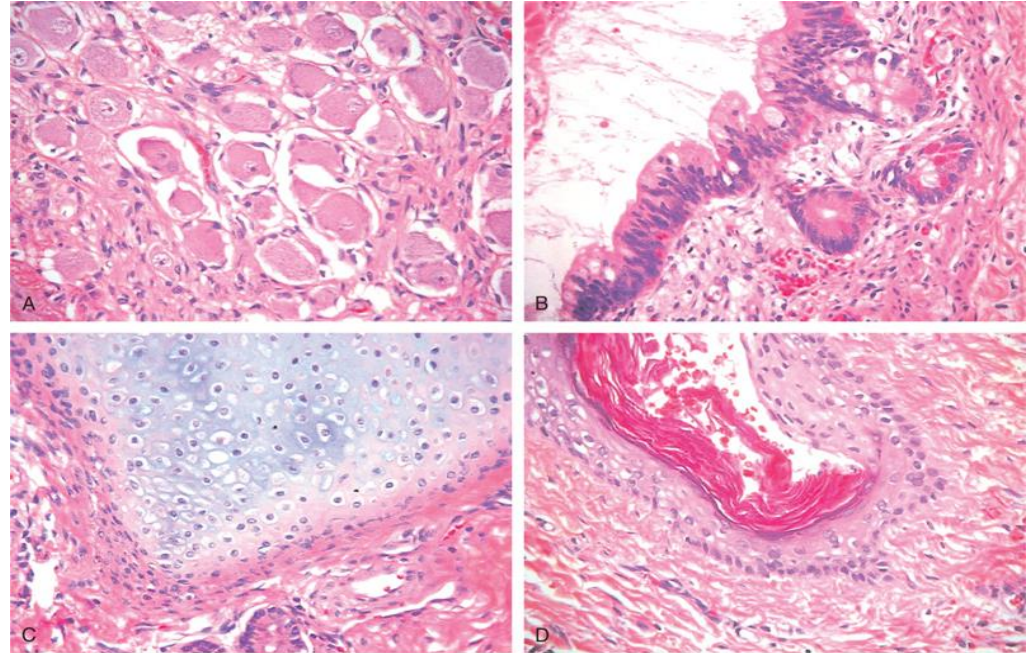
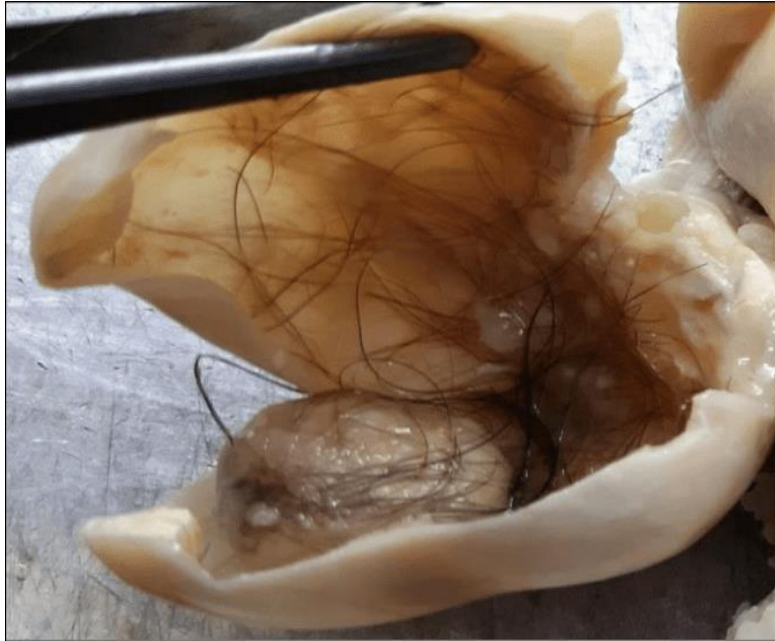Microscopic examination:

- Syncytiotrophoblasts: large multinucleated cells with abundant eosinophilic vacuolated cytoplasm producing HCG.
- Cytotrophoblasts: polygonal cells with distinct borders and clear cytoplasm; grow in cords or masses and have a single, fairly uniform nucleus.

5. Teratoma

- ▶ The neoplastic germ cells differentiate along somatic cell lines showing various cellular or organoid components
- ▶ Reminiscent of the normal derivatives of more than one germ layer.
- ▶ All ages
- ▶ Pure forms of teratoma are common in infants and children , being second in frequency only to yolk sac tumors
- ▶ In adults, pure teratomas are rare, constituting 2% to 3% of germ cell tumors. However, the frequency of teratomas mixed with other germ cell tumors is approximately 45%.

5. Teratoma



Kumar et al: Robbins Basic Pathology, 9e.
Copyright © 2013 by Saunders, an imprint of Elsevier Inc.

- **Grossly:**

firm masses containing cysts and recognizable areas of cartilage


- **Histologically:**

1. **Mature teratomas:**

a heterogeneous, collection of differentiated cells or organoid structures, such as neural tissue, muscle bundles, islands of cartilage, clusters of squamous epithelium, etc

2. **Immature teratomas:**

- Share histologic features with fetal or embryonal tissues

- 
- **In prepubertal males**, mature teratomas usually follow a benign course.
 - **In postpubertal males**, all teratomas are malignant, being capable of metastasis regardless of whether they are composed of mature or immature elements.
 - it is not critical to detect immaturity in a testicular teratoma of a postpubertal male.

Clinical Features of testicular germ cell neoplasms:

- ➔ present most frequently with a **painless testicular mass** that is non-translucent
- ➔ Some tumors, especially NSGCT, may have metastasized widely by the time of diagnosis in the absence of a palpable testicular lesion.
- ➔ Biopsy of a testicular neoplasm is **contraindicated**, because it's associated with a risk of tumor spillage
- ➔ The standard management of a solid testicular mass is **radical orchiectomy**, based on the presumption of malignancy.



Seminomas and nonseminomatous tumors differ in their behavior and clinical course:

I. Seminomas:

- ▶ often remain confined to the testis for long periods and may reach considerable size before diagnosis.
- ▶ Metastases most commonly in the iliac and paraaortic lymph nodes, particularly in the upper lumbar region.
- ▶ Hematogenous metastases occur late in the course of the disease.

II. Nonseminomatous germ cell neoplasms:

- ▶ tend to metastasize earlier, by lymphatic & hematogenous (**liver and lung** mainly) routes.
- ▶ Metastatic lesions may be identical to the primary testicular tumor or different containing elements of other germ cell tumors

Assay of tumor markers secreted by germ cell tumors:

- ▶ helpful in diagnosis and follow up (recurrence and response to therapy)
 - ✓ **HCG** : elevated in patients with **choriocarcinoma**
 - ✓ **AFP** : elevated in patients with **yolk sac tumor**
 - ✓ **lactate dehydrogenase (LDH)** level: correlate with the **tumor burden** (tumor burden); regardless of histologic type

TREATMENT:

➤ Seminoma:

- **Surgery; radiosensitive**

- tends to remain **localized** for long periods

- **best** prognosis.

- >95% of patients with early-stage disease can be cured.

➤ Nonseminomatous germ cell tumors:

- histologic subtype **DOES NOT** influence the therapy.

- 90% of patients achieve complete remission with **aggressive chemotherapy**, and **most are cured**.

- The exception is **choriocarcinoma**, which is associated with **a poorer prognosis**.

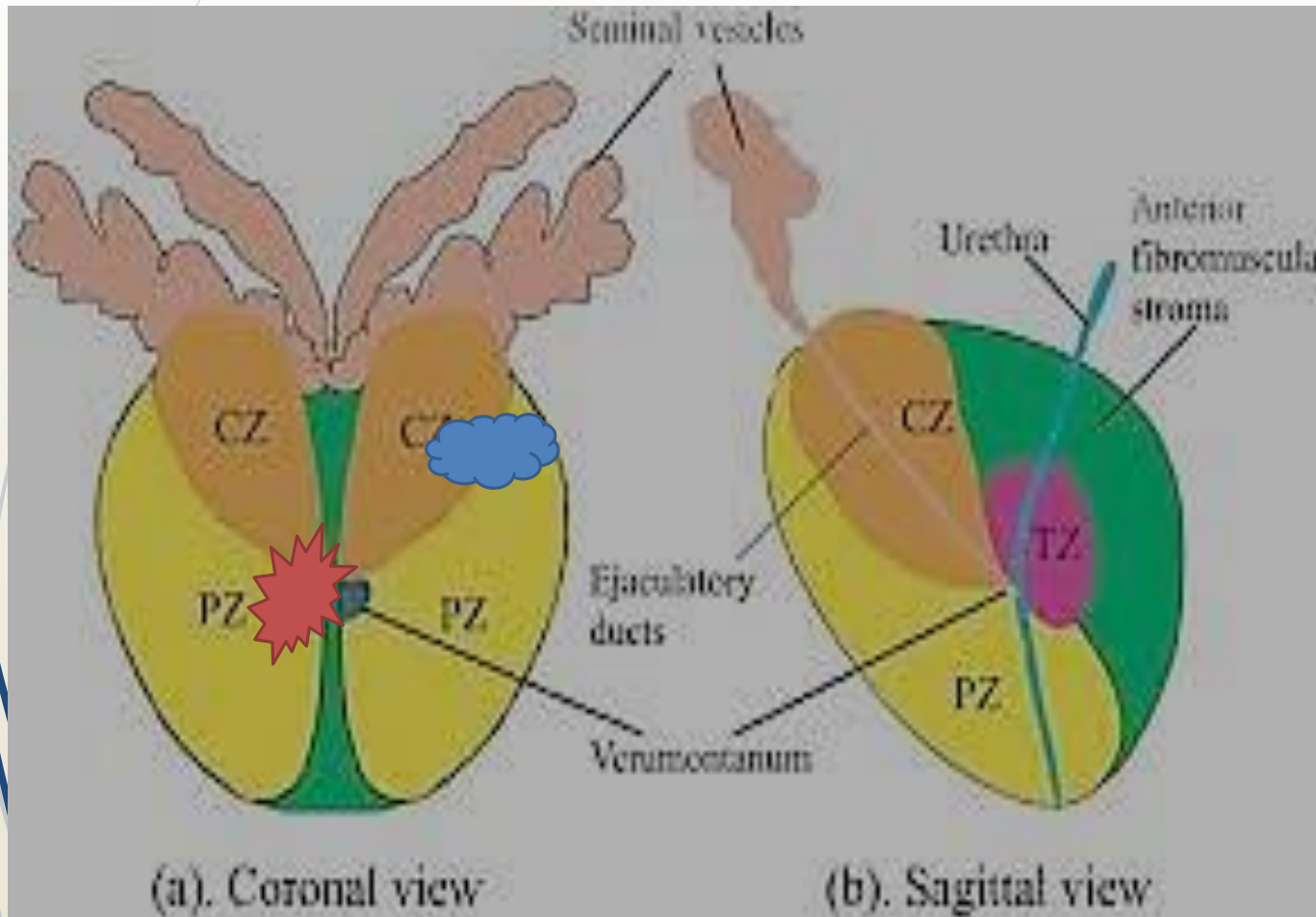
Prostate gland pathology

- 
- 1- Benign Prostatic Hyperplasia (BPH)
 - 2- Carcinoma of the Prostate

Prostate zones

BPH

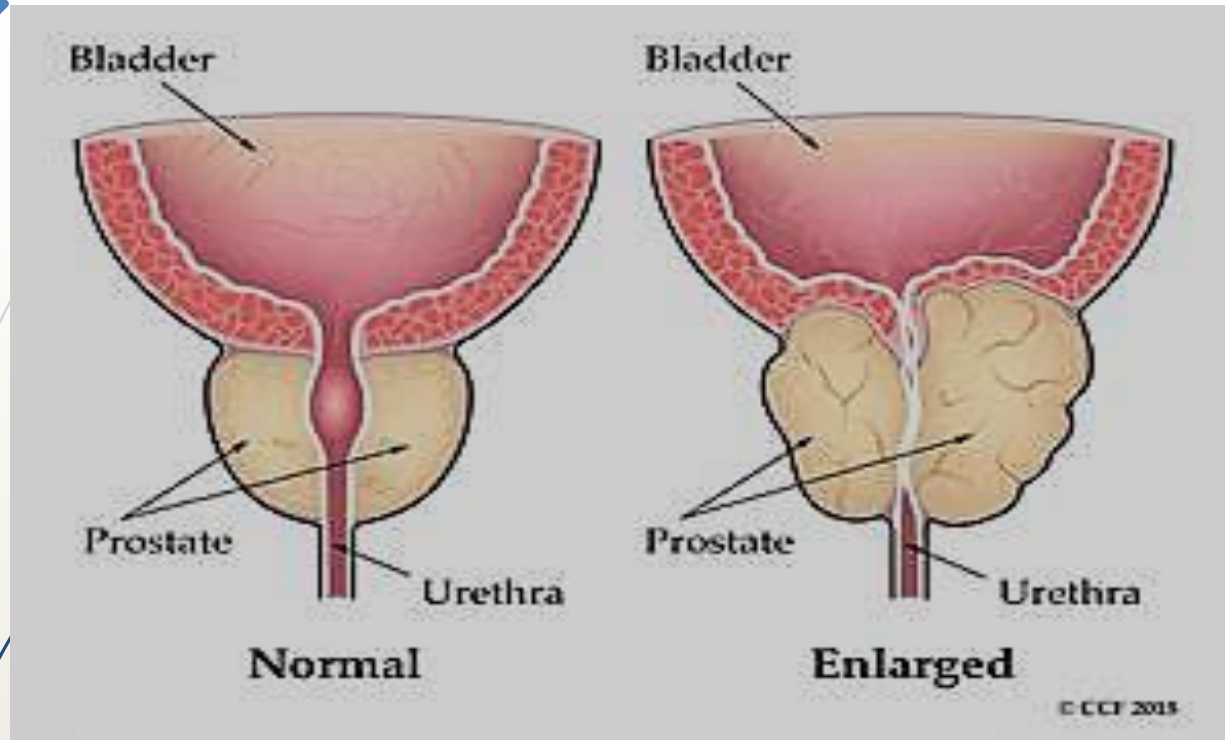
cancer



Benign Prostatic Hyperplasia (Nodular Hyperplasia)

- ▶ extremely common cause of prostatic enlargement in men ≥ 40 ; frequency rises with age.
- ▶ androgen-dependent proliferation of both stromal and epithelial elements
- ▶ does not occur in males with genetic diseases that block androgen activity.
- ▶ **Pathogenesis:**
- ▶ Dihydrotestosterone (DHT) is synthesized in prostate from circulating testosterone by enzyme **5 α -reductase**.
- ▶ DHT support growth and survival of prostatic epithelium and stroma by binding to **androgen receptors**
- ▶ **DHT is 10 times more potent.**

Benign prostatic hyperplasia

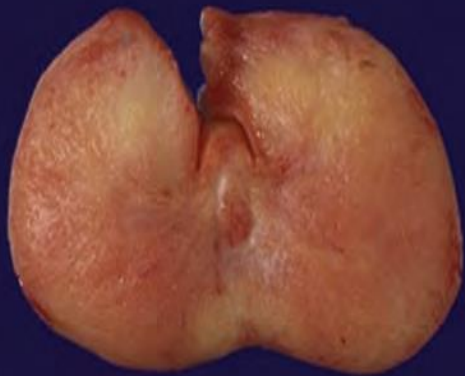


- BPH always occurs in the **inner transition zone of the prostate.**

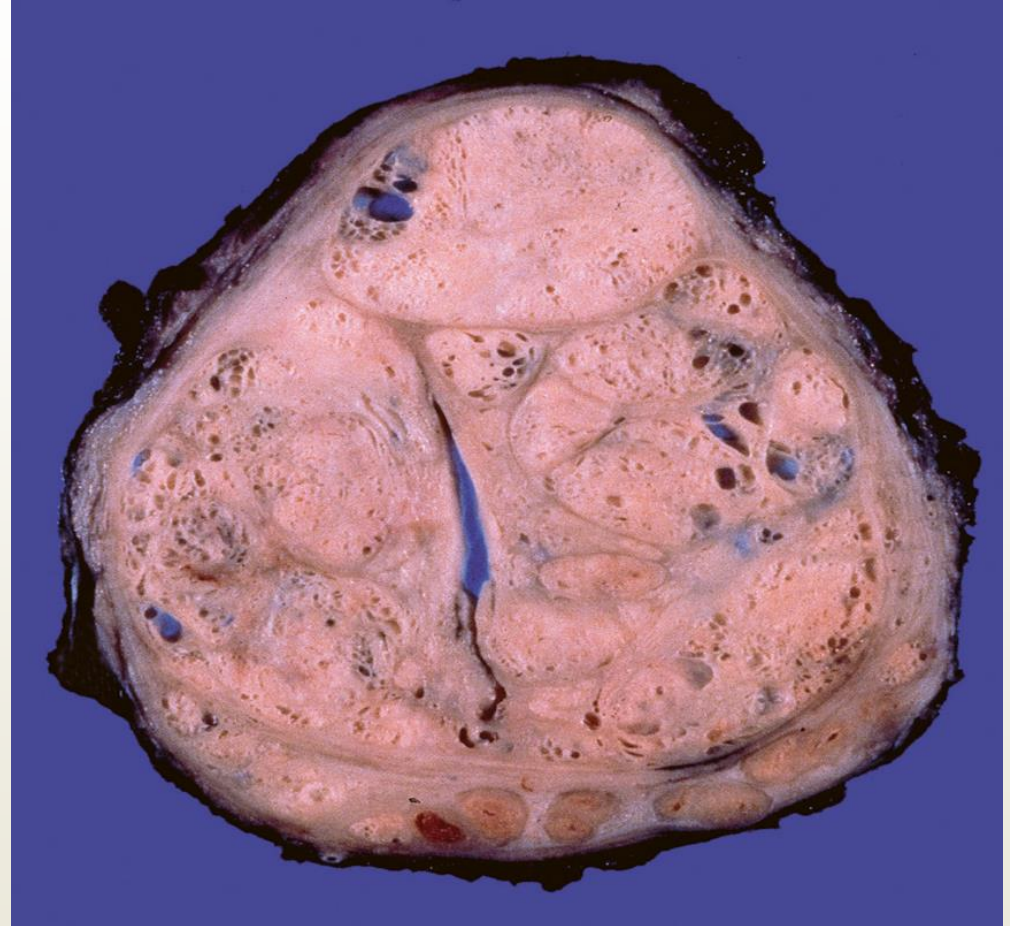
Grossly:

- Prostatic enlargement (60 to 100 g)
- many well circumscribed nodules bulging from the cut surface
- Compressed urethra

Macroscopically: enlarged gland with many well-defined nodules



Normal

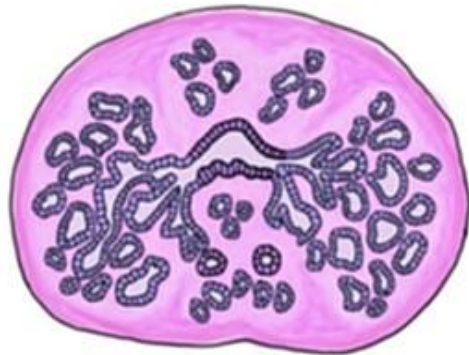


BPH

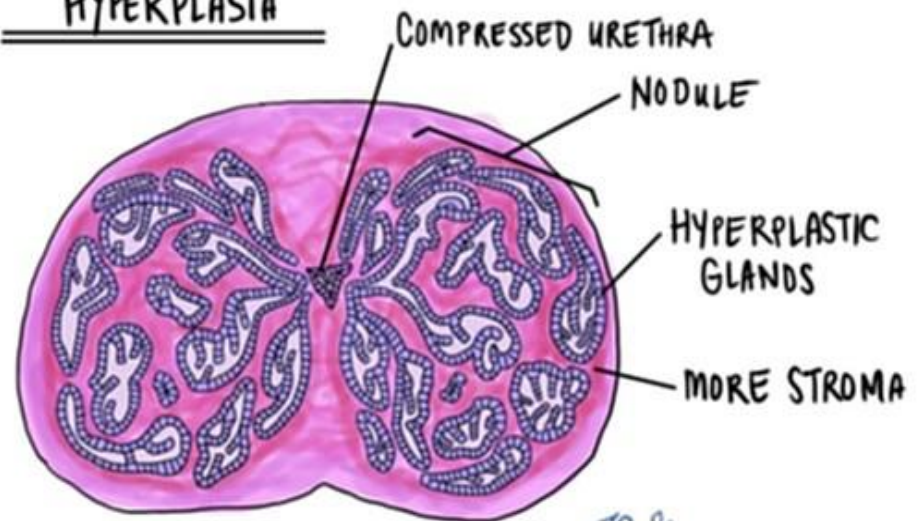
➤ Microscopically:

- hyperplastic nodules composed of proliferating glandular elements and fibromuscular stroma.
- The hyperplastic glands are lined by tall, columnar epithelial cells and a peripheral layer of flattened basal cells.

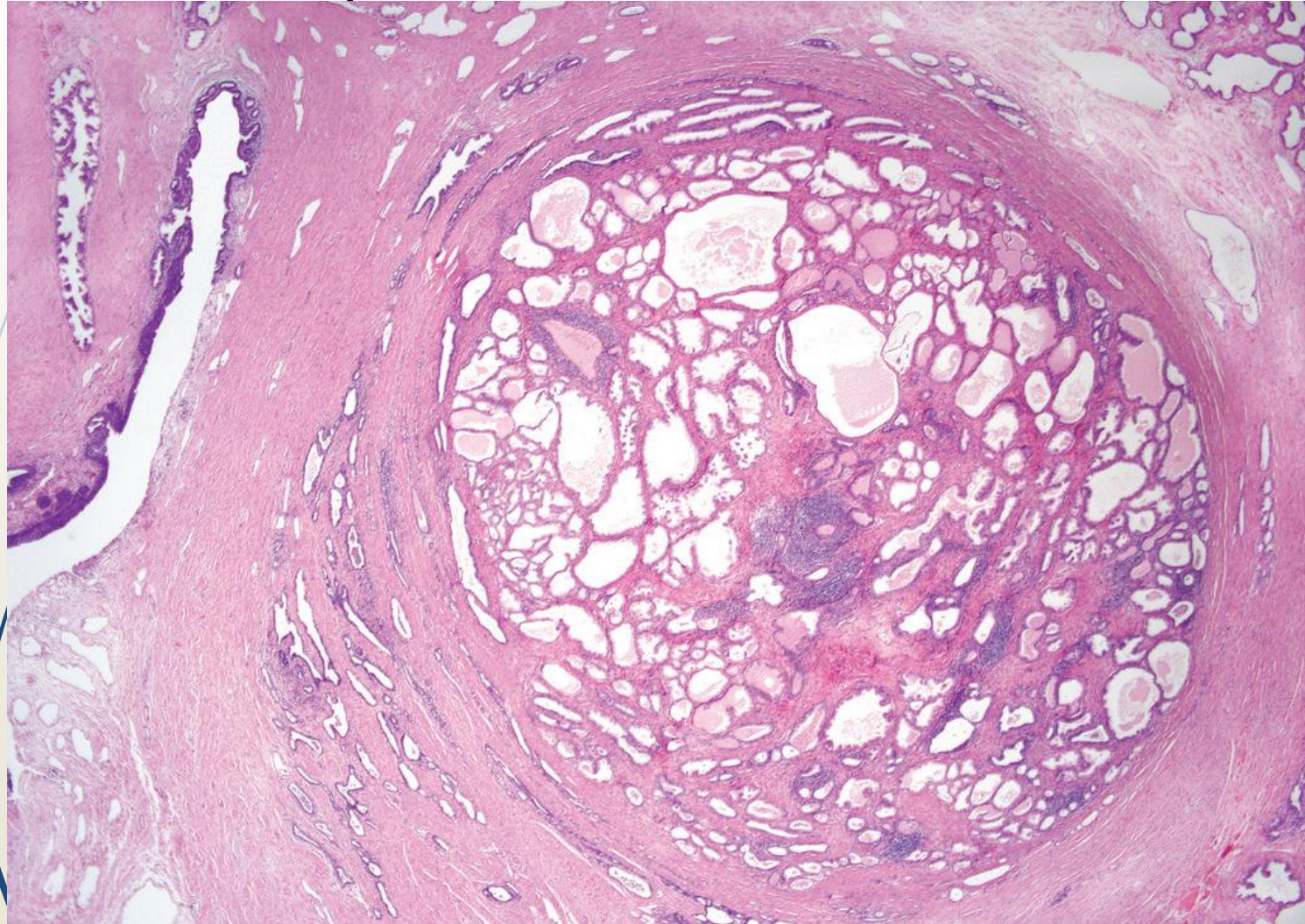
NORMAL PROSTATE



BENIGN PROSTATIC
HYPERPLASIA



Nodular hyperplasia of the prostat. → well-demarcated nodule with a portion of urethra.



BPH- Clinical features:

Because BPH involves the **inner portions of the prostate**, the most common manifestations are :

- ▶ **lower urinary tract obstruction**

 - difficulty in starting stream of urine (hesitancy)

 - intermittent interruption of urinary stream

 - urinary urgency, frequency, and nocturia (bladder irritation)

- ▶ **↑ risk of urinary tract infections**

- ▶ **TREATMENT:**

- ▶ **Drugs:**

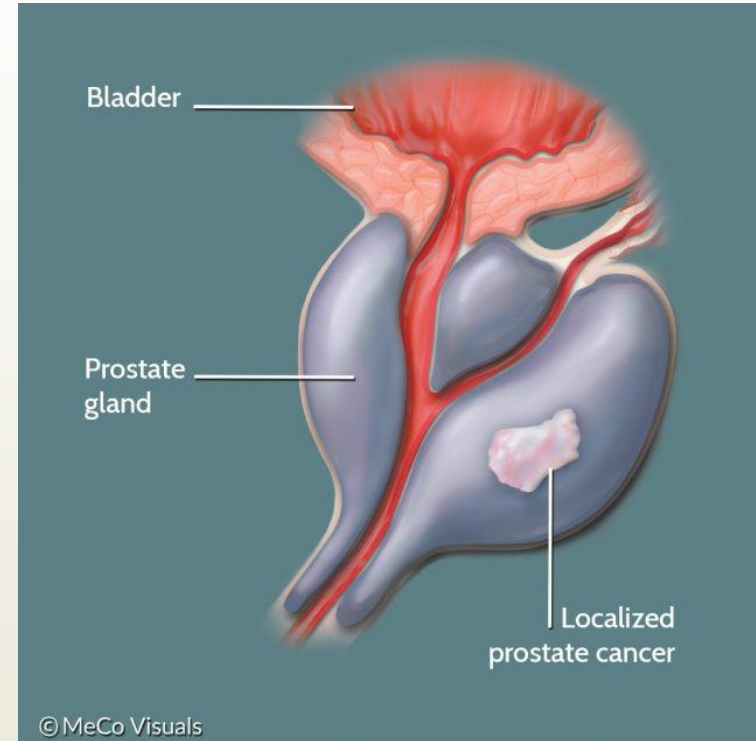
- 1- 5-alpha reductase inhibitors

- 2- agents that by blocking α 1-adrenergic receptors (relax prostatic smooth muscle)

- ▶ +/- Surgery

Carcinoma of the Prostate

- >50 years of age.
- **The most common form of cancer in men > 40**
- significant drop in prostate cancer mortality, due to increased detection of the disease through screening



PATHOGENESIS

1. Androgens.

- Cancer of prostate does not develop in males castrated before puberty.
- Cancers regress in response to surgical or chemical castration

2. Heredity:

↑risk first-degree relatives of patients with prostate cancer.

3. Environment:

- Geographical variations; diet. e.g. rise of incidence in Japanese immigrants to US

4. Acquired somatic mutations

- ***TMPRSS2-ETS* fusion genes**: most common gene rearrangements in prostate cancer (fusion genes of androgen regulated promoter ***TMPRSS2*** gene and ***ETS*** family transcription factors).

Clinical Features

- 70% - 80% in **peripheral** zones of gland (palpable as irregular hard nodules on digital rectal examination).
- **Screening test:** digital rectal examination + elevated serum prostate-specific antigen (PSA) level
- **Osteoblastic** Bone metastases (axial skeleton) (bone-producing) lesions on bone scans

Prostate cancer

