

# THE GYNAECOLOGICAL EXAMINATION

professor M BATA FRCOG

# CONTENTS

- Introduction
- General examination
- Chest examination- heart, lungs and breast examination
- Abdominal examination
- Pelvic examination - Digital and speculum examination

# INTRODUCTION

- Gynaecological examination confirms presence of pathology suspected from the gynaecological history.
- Always explain to the patient the need and the nature of the proposed examination.
- Obtain an informed verbal consent.
- The examiner (male or female) should be accompanied by another female (chaperone).
- Examination performed in a private setting, respecting patient's privacy at all times.
- Patient should be covered at all times and only relevant parts of her anatomy exposed.

# GENERAL EXAMINATION

- Observe general appearance, state of nutrition, gait, demeanour, level of consciousness, responsiveness etc.
- Height and weight - BMI
- Hands and arms- assess tobacco-stained fingers, clubbing, pulse, blood pressure, temperature.
- Head and neck- facial hair distribution (also other secondary sexual development and hair distribution), anaemia, jaundice, cyanosis, acne, lymphadenopathy, thyroid disease (enlarged thyroid gland, tremor etc)
- Legs - ankle swelling

# CHEST EXAMINATION

- Assess the heart and lungs for signs of disease

# BREAST EXAMINATION

Position patient reclining at 45 degrees with arms at the sides

- Inspection – positions at rest, arms above head, on hips
  - 1) Development and symmetry of breasts and nipples.
  - 2) Reddening of skin, ulceration or dimpling (peau d'orange)
  - 3) Retraction of nipple (CA breast)
  - 4) Nipple discharge- blood, serous or milky
- Palpation- palpate systematically for lumps with the flat part of the fingers, through all 4 quadrants. If present, describe the characteristics of the lump- location, size, shape, surface, edge, consistency and mobility in relation to deep and superficial structures.
- Palpate the axillae for lymph nodes – describe if present.

# ABDOMINAL EXAMINATION

Ensure patient lying supine, with a pillow for head rest, arms by the sides and bladder emptied.

- **Inspection:** Assess for distension, scars (operative, traumatic or scarification), distended veins, striae, pubic hair distribution.
- **Palpation:** Palpate the abdomen systematically in all 9 regions
  - 1) Superficial palpation- assess for tenderness, guarding and rebound tenderness
  - 2) Deep palpation- assess any enlargement of intra-abdominal organs (uterus, liver, spleen etc) and for any abnormal masses.

Describe any abnormal mass in terms of:

Size, shape

Position- e.g central arising out of the pelvis, or left iliac fossa

Mobility- e.g can it move from side-to-side and up-and-down or is it fixed to surrounding structures?

Surface - e.g smooth or nodular

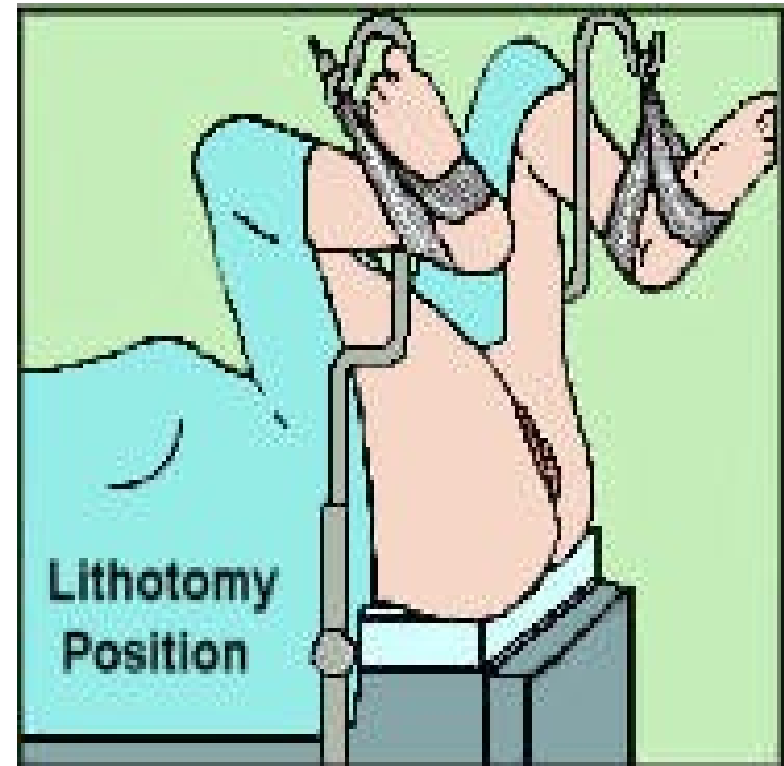
Consistency - e.g solid or cystic

Tenderness (pain on palpation)

- **Percussion:** Assess for ascites using shifting dullness and fluid thrill
- **Auscultation:** Listen for bowel sounds or for foetal heart rate in pregnancy

# PELVIC EXAMINATION

- Bear in mind the comments on privacy, respect and a female chaperone before this examination is performed.
- Best performed with patient supine in the lithotomy position (legs up in stirrups) and examiner working from the foot of the bed.
- The examination can also be done on an examination couch with patient supine, knees and hips flexed, hips abducted and feet together .The examiner stands on the patient's right side.
- A good and adjustable light source needed for inspection of the vulva and for the speculum examination.
- Examiner to wear gloves.





# PELVIC EXAMINATION

- Inspection and palpation of the vulva
- Speculum examination
- Bimanual digital examination

# INSPECTION AND PALPATION OF VULVA

Assess all structures from anterior to posterior:

**1) Mons pubis-** Describe pubic hair distribution

Female pattern-upside-down triangle

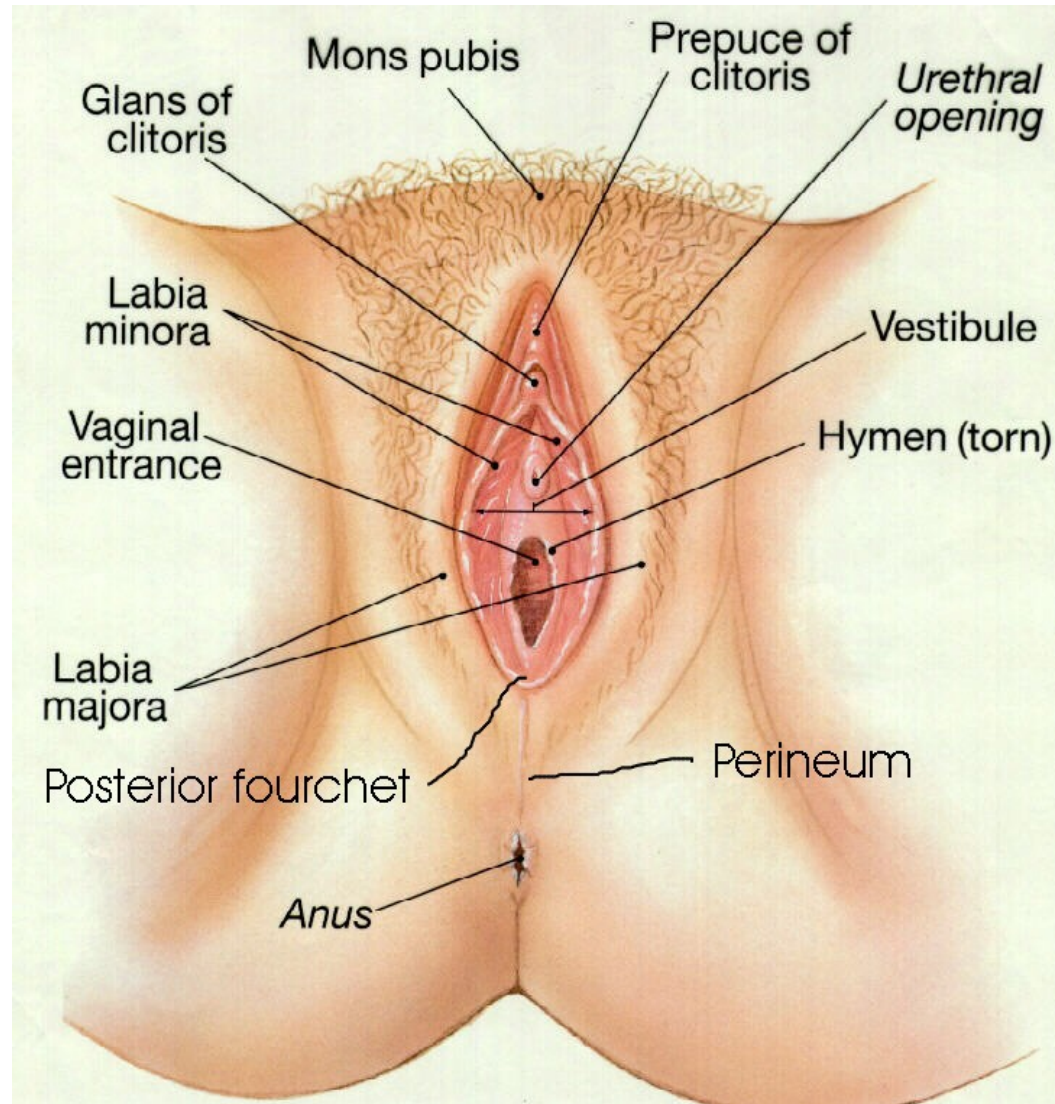
Male pattern- diamond shaped

Look for skin lesions, discolouration, excoriation, lice, ulcers and abscesses

**2) Labia majora** - lateral to the introitus (opening of vagina), covered with pubic hair. They meet anteriorly as the mons pubis.

As above.

# FEMALE EXTERNAL GENITALIA



# INSPECTION AND PALPATION OF VULVA

**3) Labia minora-** Medial to labia majora with no pubic hair covering. They meet anteriorly to cover the clitoris.

Palpate deep to the labia for enlargement of the Bartholin's gland.

**4) The perineum** - area between the fourchette and the anus (The labia minora meet posteriorly at the fourchette.)

Inspect for lesions, scars, old third degree perineal tears.

# INSPECTION AND PALPATION OF VULVA

5) **The introitus** - Separate the labia minora to expose the introitus, or vaginal opening.

Examine from anterior to posterior

- Inspect the clitoris ( size, trauma, ulcers)
- External urethral meatus (discharge, prolapse) and 2 paraurethral gland openings at 3 and 9 o'clock.
- Remnants of the hymenal ring below.
- Vaginal canal - Vaginal mucosa

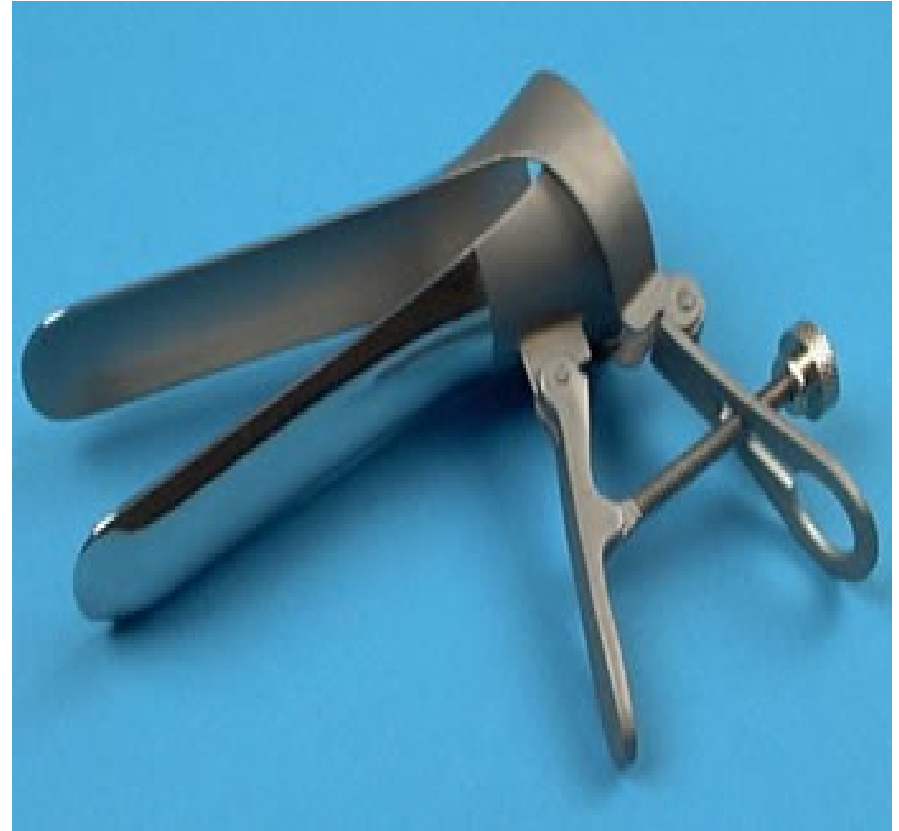Well-oestrogenised - pink colour, thick texture and rugae (folds) present.

Poorly oestrogenised - thin, pale colour and absent rugae

- Vaginal discharge- colour, texture, odour
- Older women- ask to cough to demonstrate urinary incontinence or utero-vaginal prolapse

# SPECULUM EXAMINATION

- Inform patient that the speculum will be passed to visualize the vaginal canal and the cervix.
- A sterile duck-billed/bivalve Cusco speculum checked to ensure in working order.
- Speculum assembled with blades in closed position and lock mechanism fully loosened.
- Speculum should be lubricated with KY jelly or lukewarm water before insertion (Note Pap)



# TECHNIQUE OF SPECULUM INSERTION

- Inform patient and ask her to gently bear down while speculum is passed, to relax the levator ani muscles.
- The labia are separated with the index finger and thumb of left hand.
- The lubricated closed speculum (correct size) is inserted through the introitus into the vaginal canal in one of the following ways:
  - Nulliparous, young woman: closed speculum blades inserted vertically with speculum handles on patients right side. Rotate through 45 degrees, bringing the speculum handles to the posterior position if using lithotomy position, or the anterior position if using the examination couch.
  - Multiparous women: The introitus is more patulous as they have given birth previously. The speculum may be inserted without any rotation i.e. closed blades are horizontal with speculum handles pointing posteriorly in the lithotomy position or anteriorly if using the examination couch.

# SPECULUM EXAMINATION

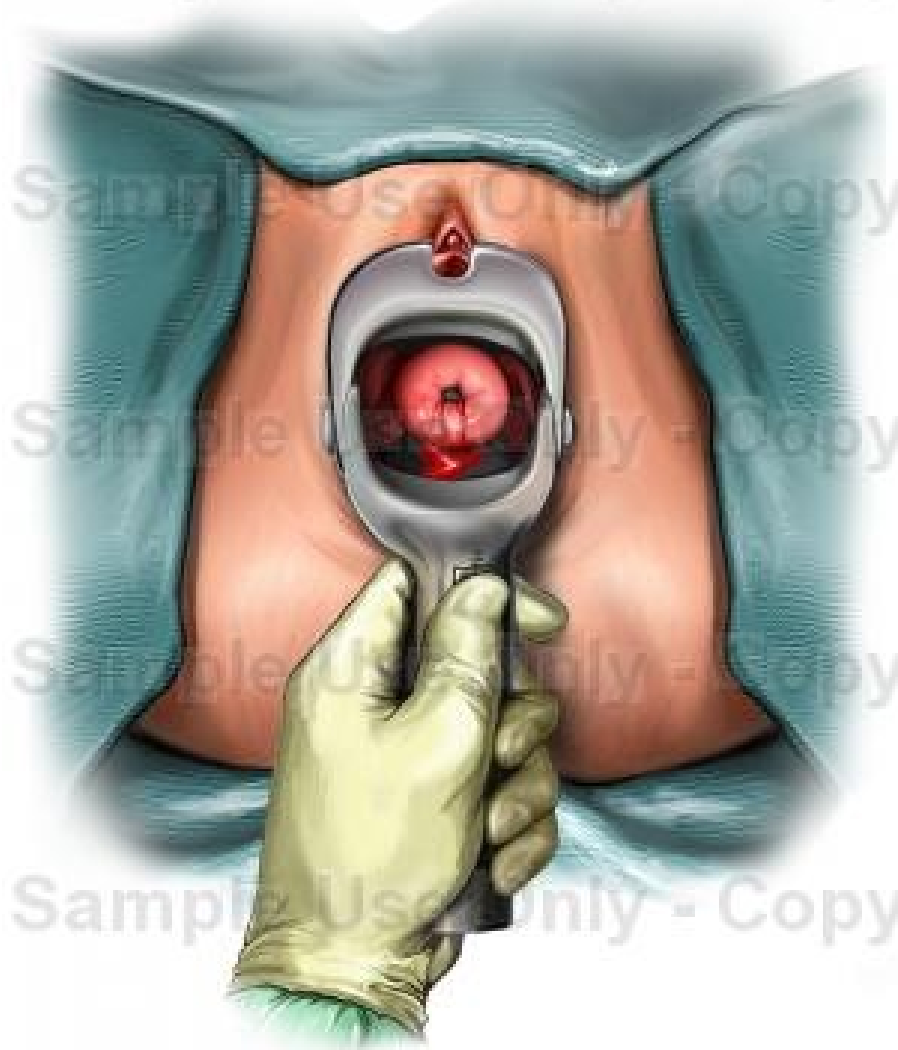
## 1) Visualisation of the cervix

- The full length of speculum is inserted up the length of the vaginal canal. Pushing the handles together opens the blades of the speculum which is manoeuvred so that the cervix is fully visualized.
- The screw adjuster on the handle is then locked so that the speculum is maintained in place.
- The cervix is then inspected.



# SPECULUM EXAMINATION – Note that speculum in illustration is not a Cusco....

Sample Use Only - Copy



## Inspect the cervix:

- Type of cervical os- small round dimple (nulliparous os) or os in the shape of a smile (multiparous os)
- Colour- normally pink, may be a redder area around the os, known as cervical ectropion, or tinged blue if pregnant, red in cervicitis
- Secretions/ discharge - observe colour (eg cervical mucus if ovulating, blood if menstruating)
- Presence of growths/ tumours- usually cauliflower-like and friable, i.e. bleeds on touch ( indicates malignancy)
- Ulcerations, scars and retention cysts (Nabothian follicles)
- The cervical smear/"Pap" smear is taken at this stage

# SPECULUM EXAMINATION

## Papanicolau/"Pap" smear:

Indications:

Cervical cancer screening-

Within 5 years of becoming sexually active

Annually in high-risk groups such as patients with recurrent STI's and HIV

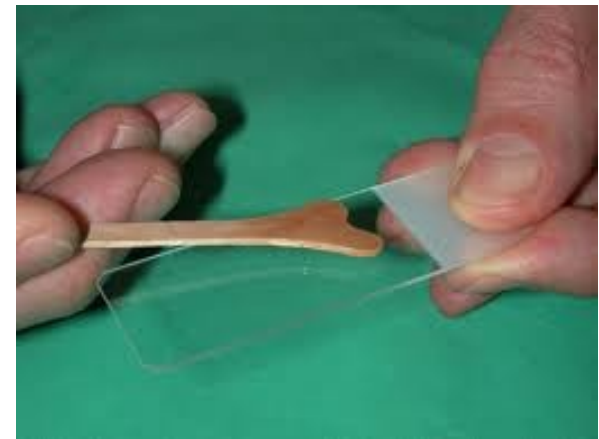

Post-coital bleeding

Postmenopausal bleeding

1<sup>st</sup> trimester of pregnancy

## Additional equipment required

- Ayres spatula or an endocervical brush eg Craigbrush
- Swabs
- Fixative spray
- Two glass slides labeled with patient's name



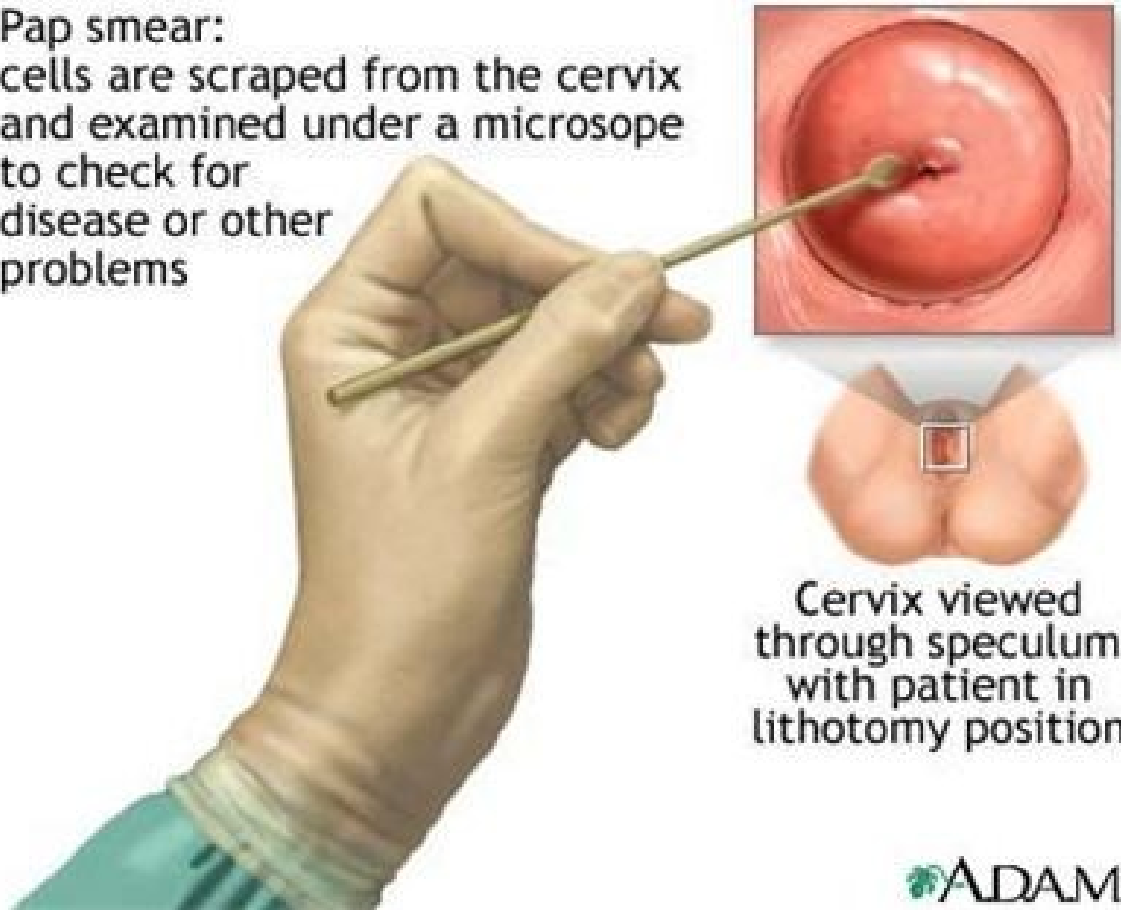
# PAP SMEAR

## Procedure (Pap smear):

- Gently clean discharge or blood from the cervix, if present, with a cotton swab.
- Insert the spatula with the endocervical tip ( the longest part), into the endocervical canal and turn 360 degrees. This allows removal of the surface cells from the whole of the squamocolumnar junction. Apply the smear onto the slide – 2 strokes.
- The Craigbrush is superior to the spatula if the transition zone is high and you cannot see it. Turn it gently in five complete circles and apply the smear to the slide in gentle strokes.
- Within 20 seconds of taking it, apply the smear onto the glass slide with a light sweeping motions. Spray immediately with one spray of fixative, holding the spray bottle upright at about 30cm from the slide, to prevent drying and decay of the cells.
- Complete the pathology request form, recording any findings about the appearance of the cervix and send the smear to the laboratory.
- It is crucial to contact the patient with the results, hence ensure her address and contact tel. nos are complete and correct.

# PAP SMEAR — this is not an Ayre's spatula...

Pap smear:  
cells are scraped from the cervix  
and examined under a microscope  
to check for  
disease or other  
problems



Cervix viewed  
through speculum  
with patient in  
lithotomy position

# SPECULUM EXAMINATION

## 2) Inspecting the vagina

- With the speculum in this position, inspect the vaginal side-walls for any ulcers, discolouration, discharge or growths.
- The handles of the speculum are then unlocked and the blades allowed to close but not completely, leaving a 1cm gap between the tips.
- Withdraw the speculum gently whilst inspecting the anterior and posterior walls of the vagina, again looking for any ulcers, discolouration, discharge or growths.
- The speculum is placed in a bowl with disinfectant, for later cleaning and re-sterilization (autoclave).

# BIMANUAL DIGITAL EXAMINATION

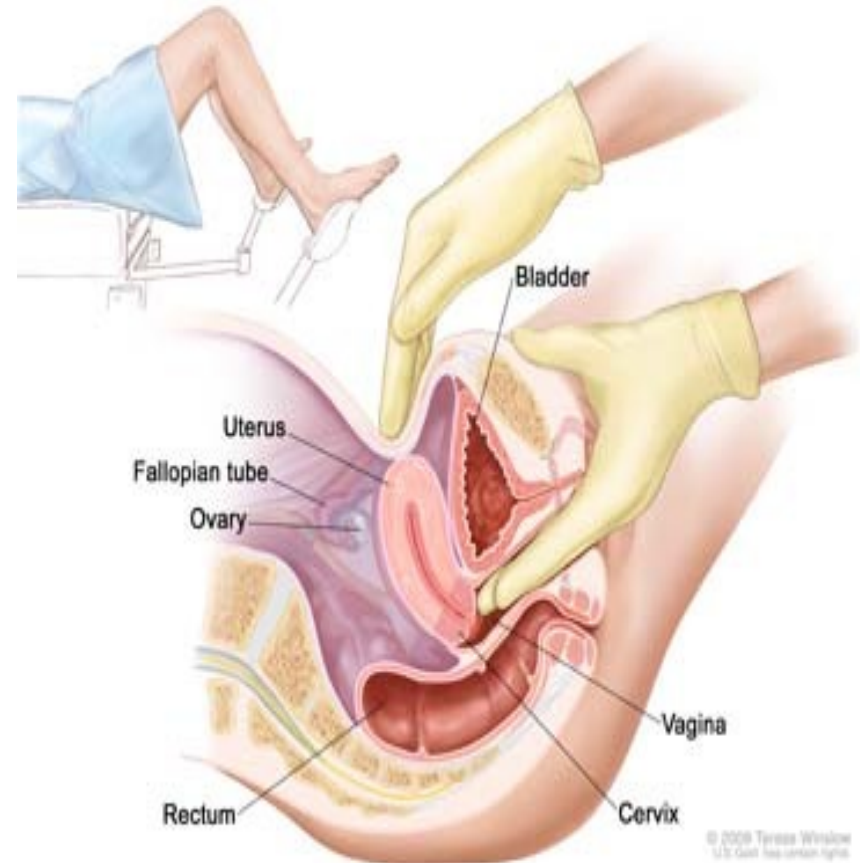- Explain every step to the patient and reassure her - inform her that an internal examination is to be performed.
- The labia are gently parted with the gloved index finger and thumb of the left hand.
- Initially the lubricated index finger of the examiner's right hand is inserted through the introitus into the vaginal canal.
- If patient is comfortable with this, the lubricated middle finger of the same hand is also inserted. If not, due to pain, a limited bimanual examination with one finger can be performed.
- The full length of the finger is introduced, assessing the vaginal walls in transit until the cervix is located.

# BIMANUAL DIGITAL EXAMINATION

## 1) Assessing the cervix:

Vaginal fingers locate the cervix and the external cervical os:

- Determine whether it is **open or closed**
- Determine the **length** of the cervix
- Directed posteriorly when the uterus is anteverted
- **Consistency** usually firm when normal, but hard due to fibrosis or carcinoma, and soft in pregnancy
- Gently and minimally move the cervix from side-to-side while watching patient's face to ascertain whether this is painful = **cervical excitation tenderness** - positive in the presence of pelvic inflammation and ectopic pregnancy.



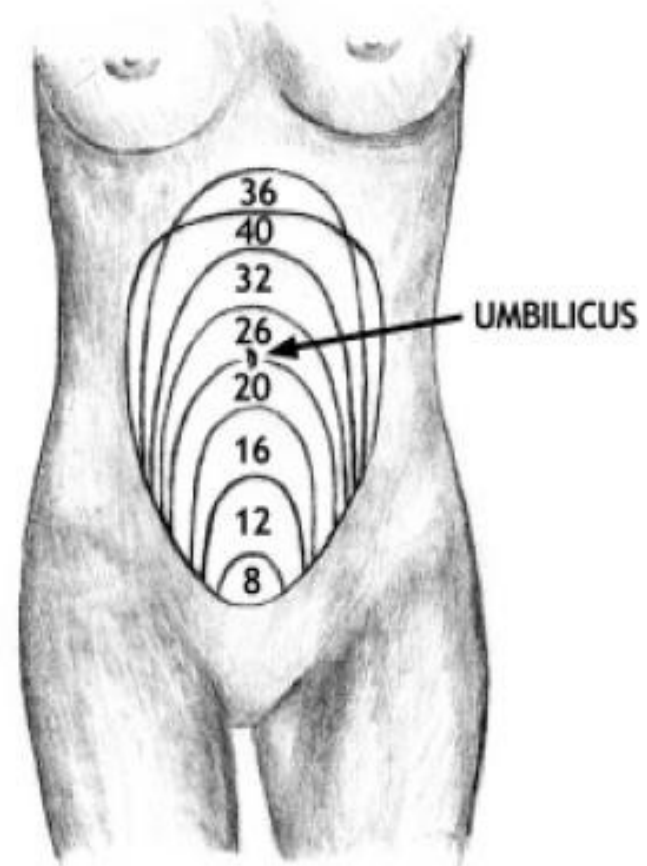
# BIMANUAL DIGITAL EXAMINATION

## 2) Assessing the uterus:

The vaginal fingers then push on or behind the cervix to elevate the uterus upwards towards the anterior abdominal wall, while the left hand is placed supra-pubically to palpate the uterus between the two hands (bimanual).

- Assess **size** of uterus (in gestational weeks)
- **Shape** (globular is almost round and smooth, while bossellated means lumpy as in a tumour)
- **Consistency** (normally firm, soft in early pregnancy, hard if a tumour present)
- **Position** of uterus (if anteverted it is angled/ tipped towards the ant. abdominal wall, while if retroverted, it is angled backwards away from the ant. abdominal wall)
- Presence of any **tenderness**
- **Mobility** (mobile or fixed)

Figure 1. Uterine Size Based On Weeks Of Gestation.



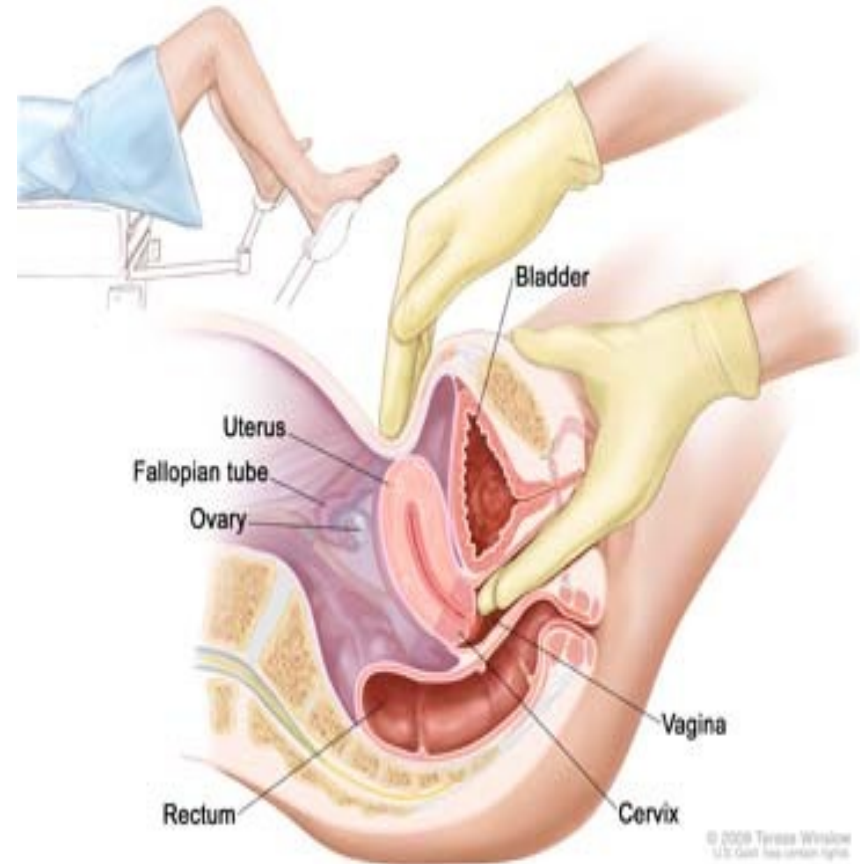

# BIMANUAL DIGITAL EXAMINATION

## 3) Assessing the adnexae:

The vaginal fingers are now moved into one of the **lateral fornices** with the abdominal hand moving to the corresponding iliac fossa.

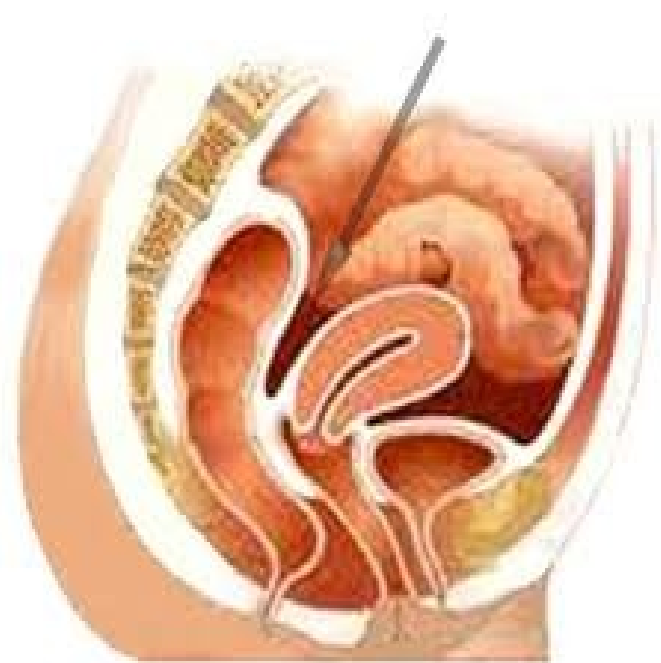Assess for any **adnexal masses** (ovaries and fallopian tubes) on both sides - size, shape, **tenderness**, etc.



# BIMANUAL DIGITAL EXAMINATION

## 4) Assessing the Pouch of Douglas (recto-uterine pouch):

- The vaginal fingers now placed into the **posterior fornix** of the vagina and its shape is assessed (normally concave away from the fingers, but may be convex towards the fingers if there is a mass in the Pouch of Douglas).
- The fingers are now removed from the vagina.
- Clean the vulva, cover and help the patient to sit up.
- Thank her and make her comfortable.



# Record your findings in the chart

- Vaginal examination – often abbreviated as PV (per vaginum) or VE (vaginal examination)
- Describe each of the following, plus any abnormalities noted:
  - **Vulva and vagina**
  - **Cervix**
  - **Uterus**
  - **Adnexae**
  - **Any additional significant findings**

Example – for a routine check-up may see notes recorded as follows:

PV: V&V: NAD

Cervix: Closed, non-tender, no visible abnormality (Pap taken)

Uterus: Bulky, non-tender, approximately 6 week size

Adnexae: NAD

# References

- Skills protocol from Dept of Obstetrics and Gynaecology
- Hutchison's Clinical Methods, Michael Swash
- South African Family Practice Manual, Mash & Lindeque
- Google Images