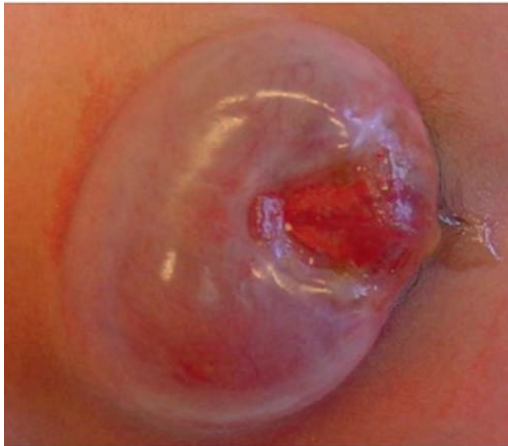

Spinal dysraphism (spina bifida)

Dr.Qussay Alsabbagh

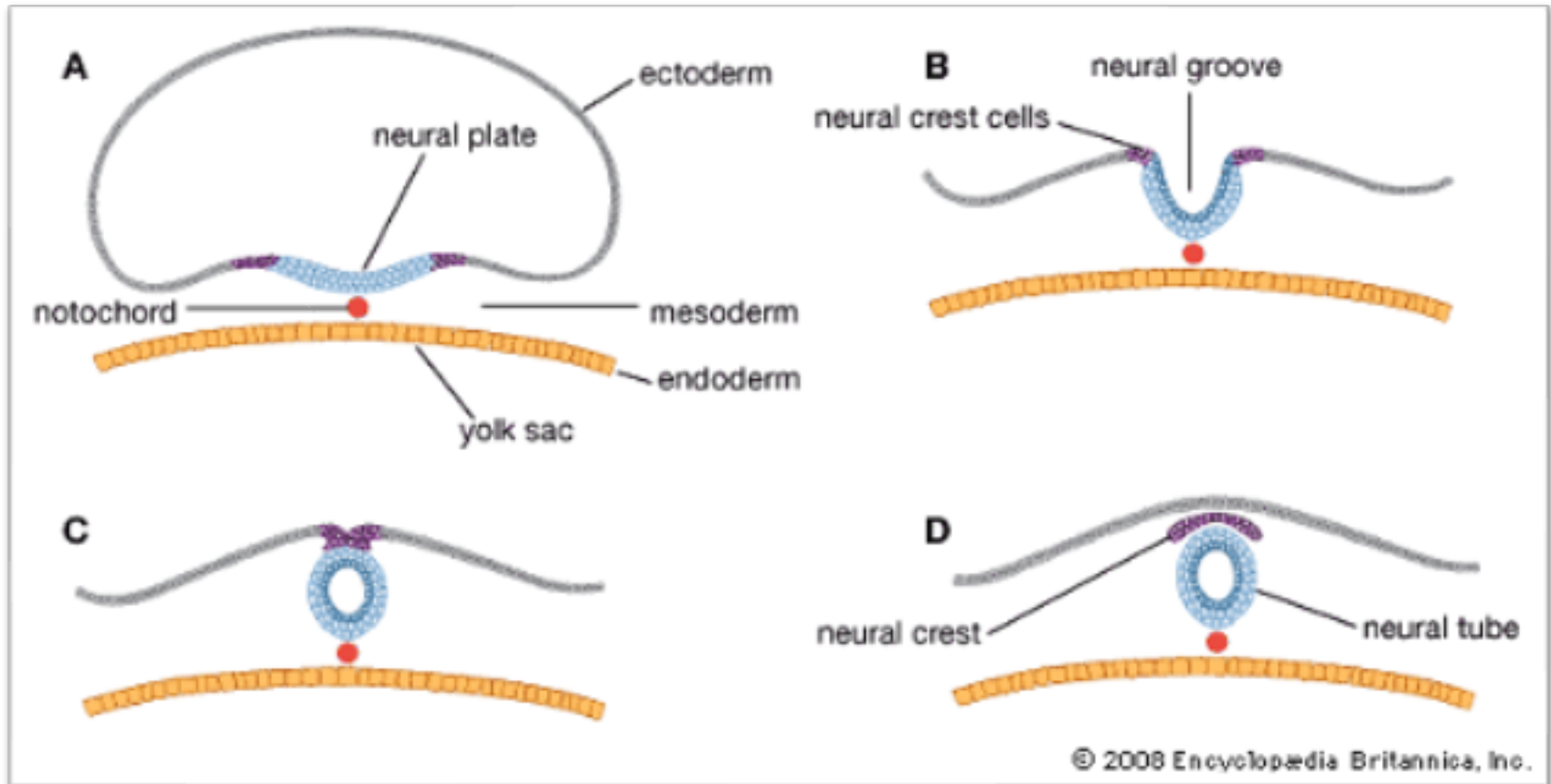
Definition



- A major birth defect and a type of neural tube defect that involves an opening in the vertebral column caused by the failure of the neural tube to close properly during embryonic development
- The term 'spina bifida' was first used in *Observationes Medicae* in 1685

Embryology

- The process of primary neurulation occurs in the first month of gestation. Neural development begins quite early, neural plate and groove appear at 18 days and complete closure of neural tube by the end of the 4th week.



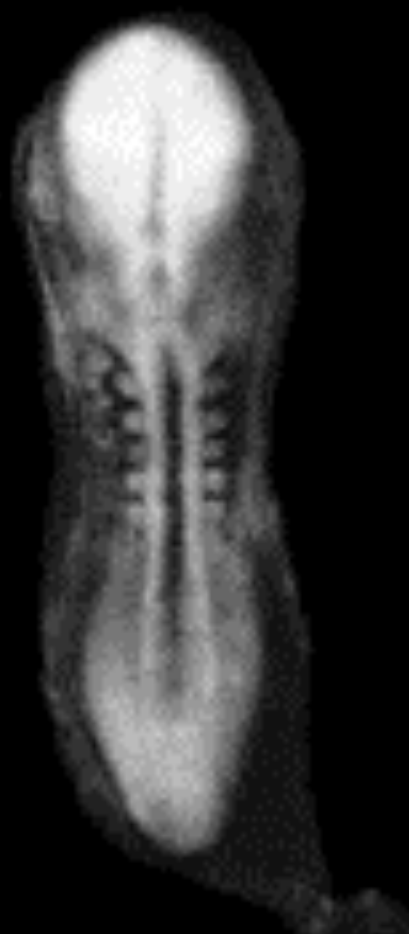- The early central nervous system begins as a simple [neural plate](#) that folds to form a [neural groove](#) and then [neural tube](#). This early neural is initially open initially at each end forming the [neuropores](#)(cranial and caudal).
- Failure of these opening to close contributes a major class of neural abnormalities (neural tube defects)

- Within the neural tube stem cells generate the 2 major classes of cells that make the majority of the nervous system : neurons and glia.
- Both these classes of cells differentiate into many different types generated with highly specialized functions and shapes.

stage 10

brain
fold

neural
groove

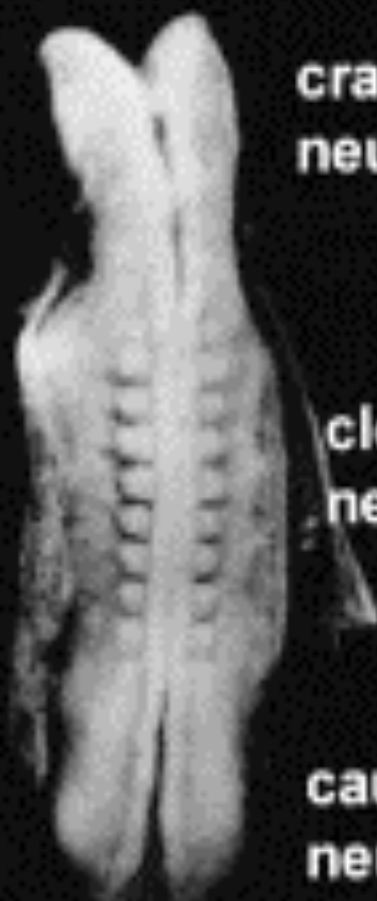

early

cranial
neuropore

closing
neural tube

caudal
neuropore



late

Types of spina bifida

- **Spina bifida occulta**

Congenital absence of a spinous process and variable amounts of lamina. No visible exposure of meninges or neural tissue .

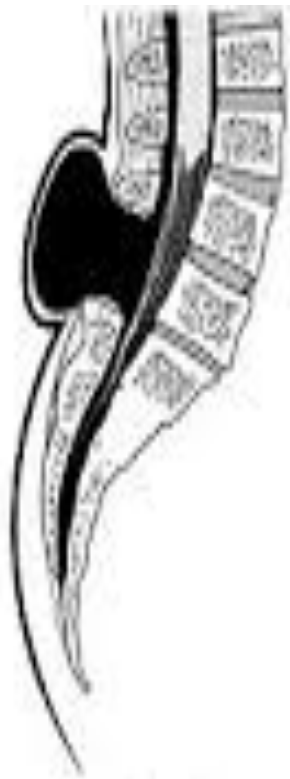- **Spina bifida aperta** (*aperta* from the Latin for “open”) or **spina bifida cystica**.



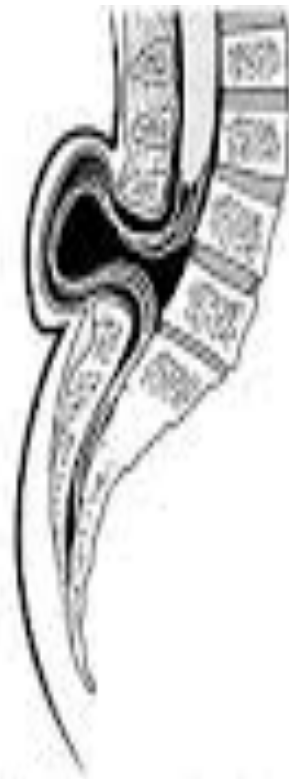Normal



Occulta



Meningocele



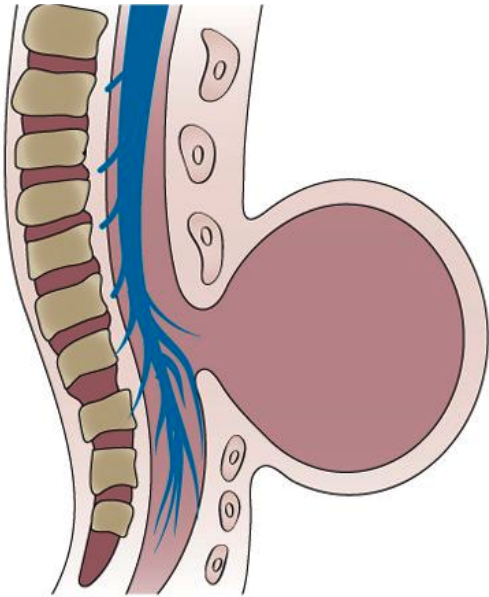
Myelomeningocele

(a)

Spina bifida cystica

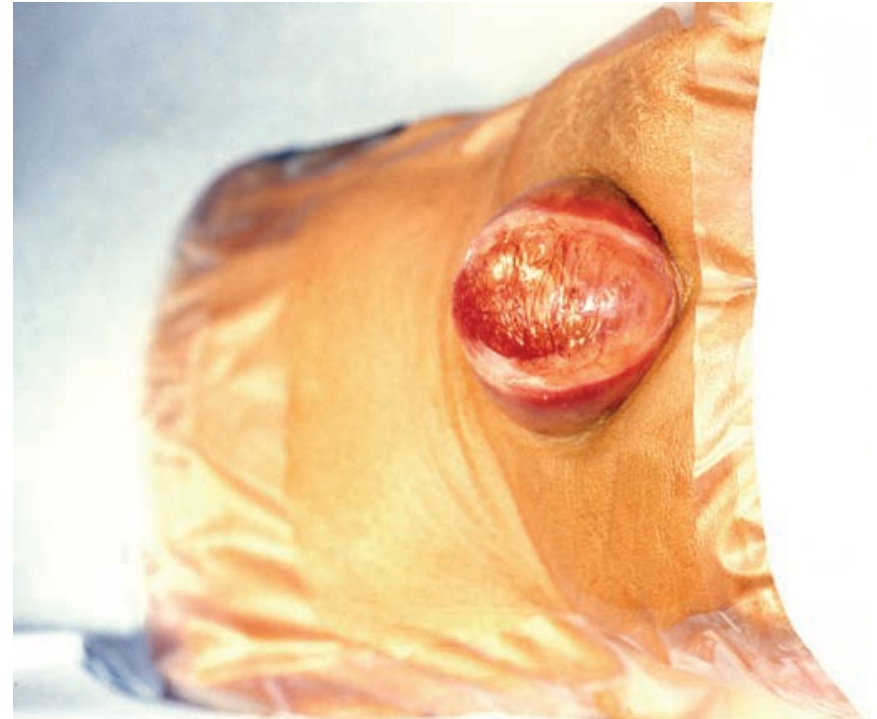- Meningocele :Congenital defect in vertebral arches with cystic distension of meninges, but no abnormality of neural tissue. One third have some neurologic deficit.
- Myelomeningocele :Congenital defect in vertebral arches with cystic dilatation of meninges and structural or functional abnormality of spinal cord or cauda equina .
- MM is the most common anomaly of the CNS that is compatible with life and has a mortality rate of approximately 10%

Meningocele

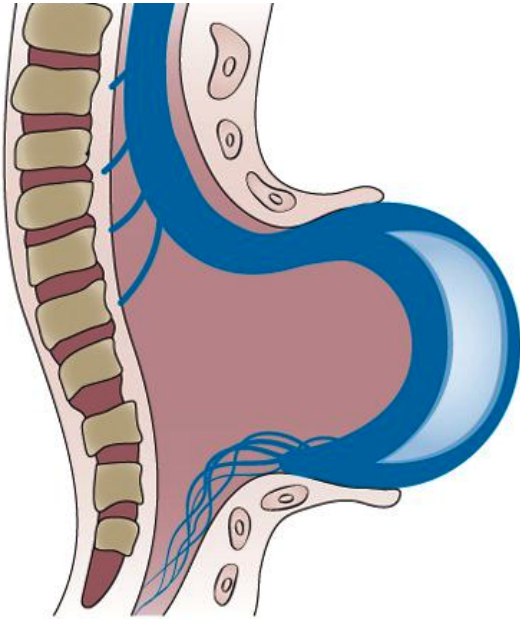


Meningocele

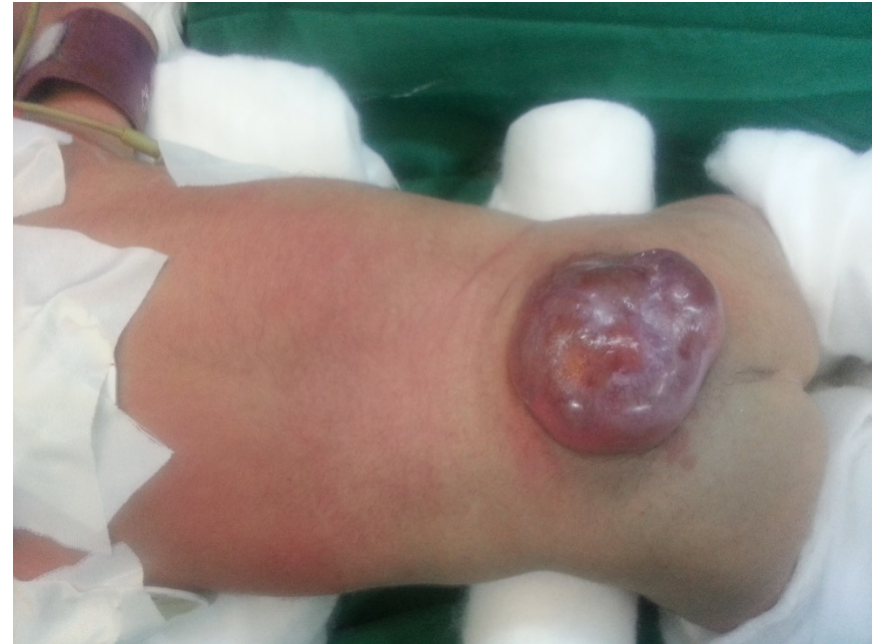Protrusion of the meninges (filled with CSF) through a defect in the skull or spine



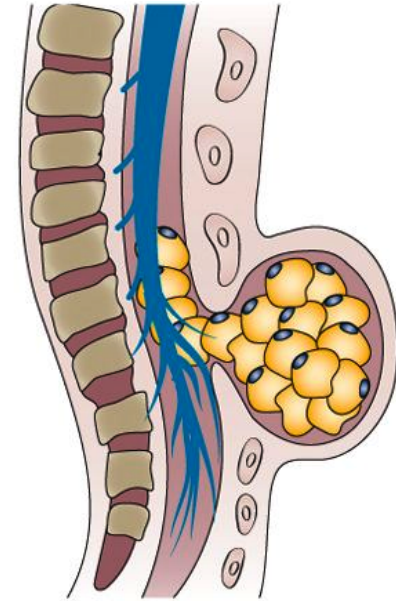
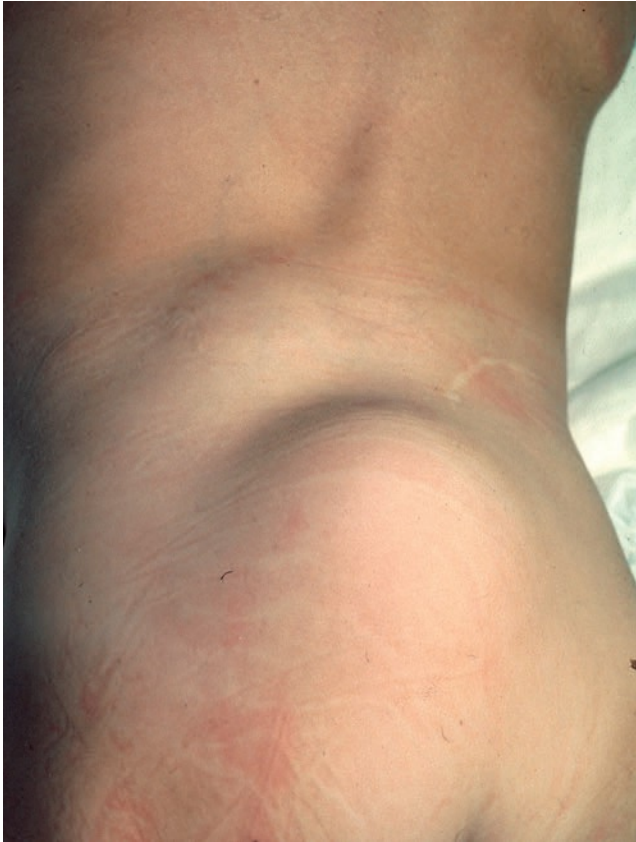
Myelomeningocele



Myelomeningocele
Open spinal cord
(with a meningeal cyst)



Lipomyelomeningocele



Closed spinal dysraphism
Deficiency of at least two vertebral arches, here covered with a lipoma

Etiology

- Unknown cause but some predisposing factors are:
 - Genetic factors: Family history —> if a woman bears child with Spinal Bifida, there is a chance that of another child having spinal bifida(**0.36 and 1.7 per 1000 live births. The risk of recurrence is 2–5% in couples with one previous child with MM, and up to 15% in cases with two previous affected children)***
 - However, 90–95% of MM cases occur in pregnancies of so-called low-risk couples that do not have a history of affected children.
 - More common in females than males
- ✘ *(Gynecologists ACoOa 1986; Kallen et al. 1994)

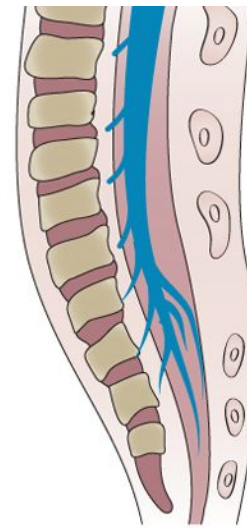
- Nutritional deficiency of Folic Acid
supplementation of folic acid at a dose of 4 mg/day
in women with a history of children with MM
reduced the risk of recurrence by approximately 70%
(Lumley et al. 2001).
- Medications like. Anticonvulsants(valproate)
- Conditions like:. Diabetes, obesity and fever
also increases the chances of delivering of a
baby with a spina bifida

SPINA BIFIDA OCCULTA (SBO)

Reported prevalence range of SBO: 5-30% of North Americans (5-10% is probably more realistic).

The defect may be palpable, and there may be overlying cutaneous manifestations

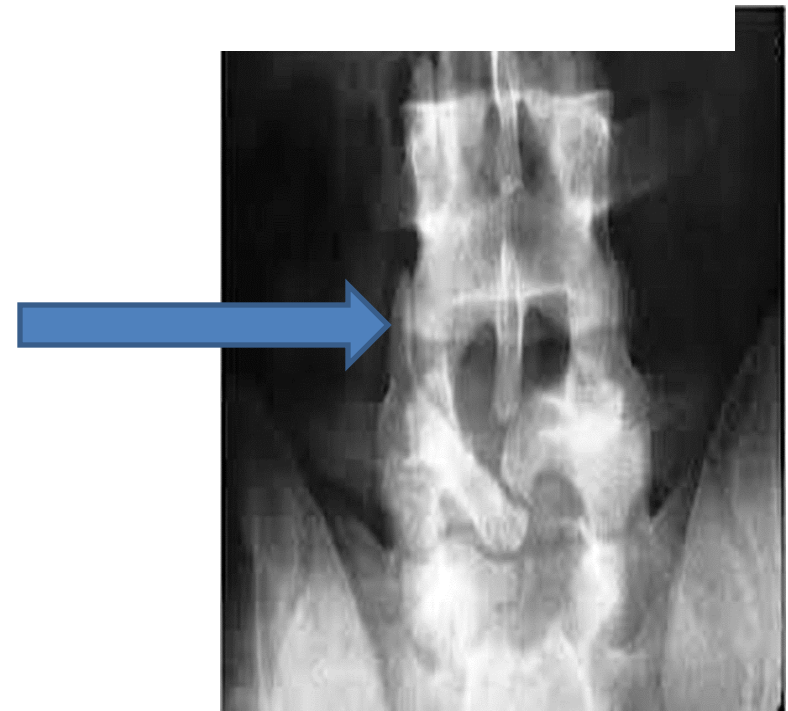
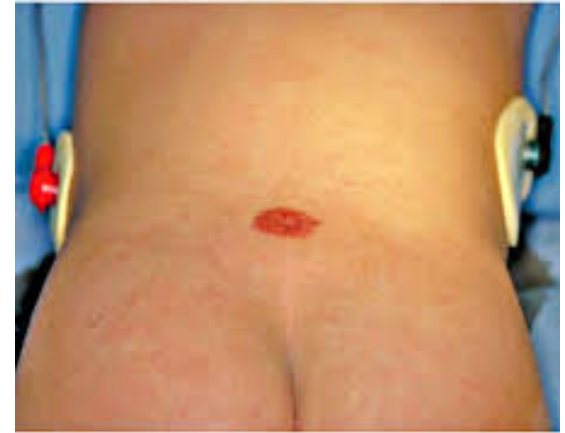Often an incidental finding, usually of no clinical importance when it occurs alone.



Spina bifida occulta

Closed asymptomatic NTD in which some of the vertebrae are not completely closed

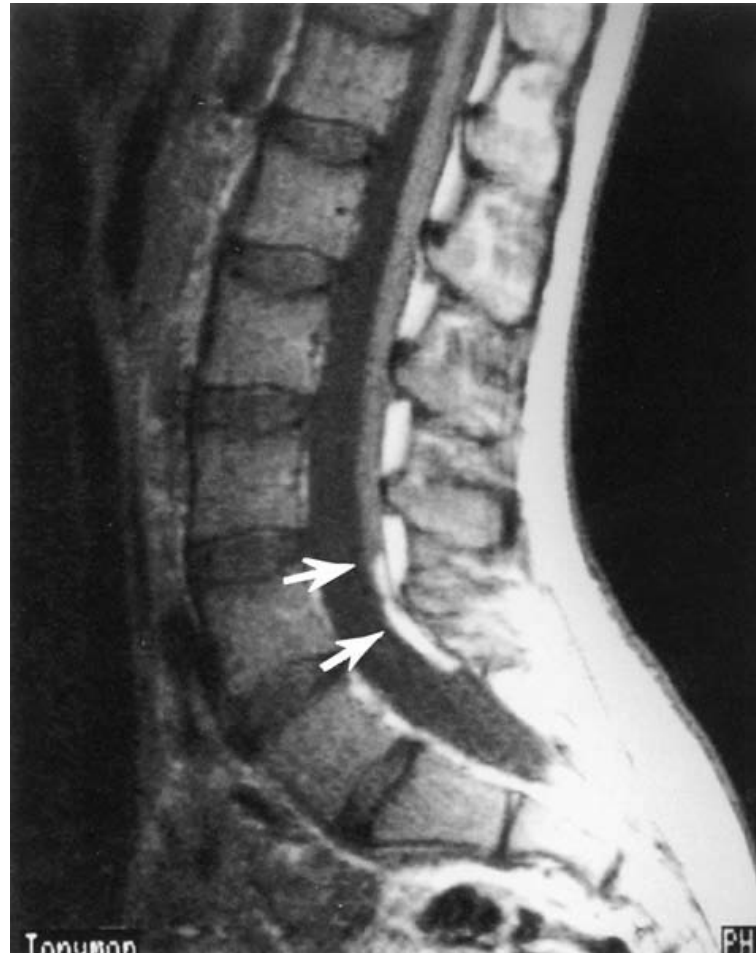- ✓ Numerous reviews have shown no statistical association of SBO with nonspecific Low back pain. An increased incidence of disc herniation was shown in one study.
- ✓ SBO may occasionally be associated with diastematomyelia, tethered cord, lipoma, or dermoid tumor.
- ✓ When symptomatic from one of these associated conditions, the presentation is usually that of tethered cord (gait disturbance, leg weakness and atrophy, urinary disturbance, foot deformities...).



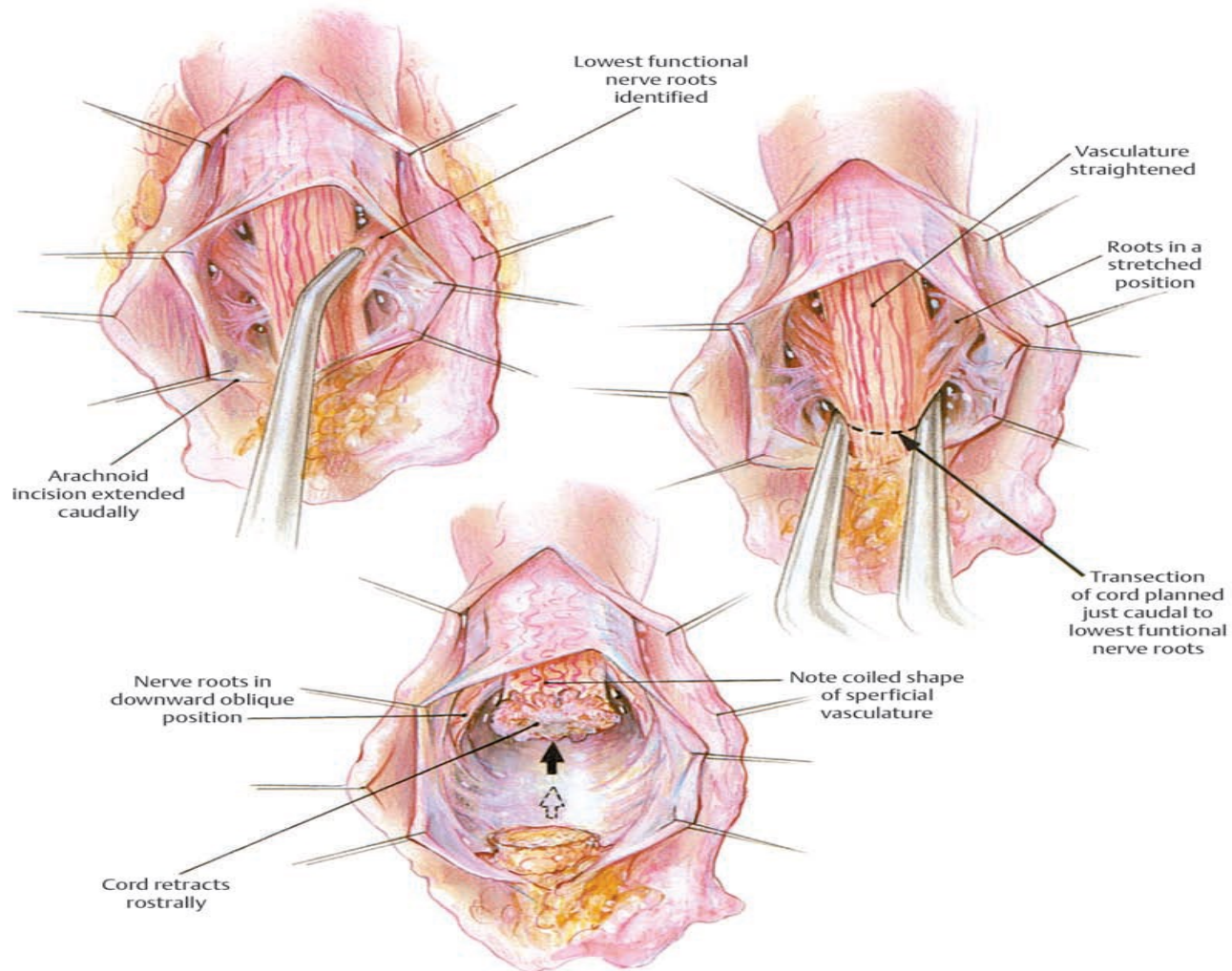
Tethered cord syndrome

Abnormally low conus medullaris. Usually associated with a short, thickened filum terminale, or with an intradural lipoma (other lesions, e.g. lipoma extending through dura, or diastematomyelia are considered as separate entities). Most common in myelomeningocele (**MM**).

A sagittal T1-weighted magnetic resonance image through the lumbar region demonstrates a thickened filum terminale. The hyperintensity (*arrows*) indicates fatty infiltration of the filum



Detethering (release of the tethered cord)



Myelomeningocele

EMBRYOLOGY

The anterior neuropore closes at gestation day 25. The caudal neuropore closes at day 28.

EPIDEMIOLOGY/GENETICS

- Incidence of spina bifida with meningocele or myelomeningocele (**MM**) is 1-2/1000 live births (0.1-0.2%).
- Risk increases to 2-3% if there is one previous birth with MM, and 6-8% after two affected children.
- The risk is also increased in families where close relatives (e.g. siblings) have given birth to MM children, especially when on the mother's side of the family.
- Incidence may increase in times of war, famine or economic disasters, but it may be gradually declining overall.

Transmission follows non-Mendelian genetics, and is probably multifactorial.

PRENATAL DETECTION OF NEURAL TUBE DEFECTS

❖ Serum alpha-fetoprotein (AFP)

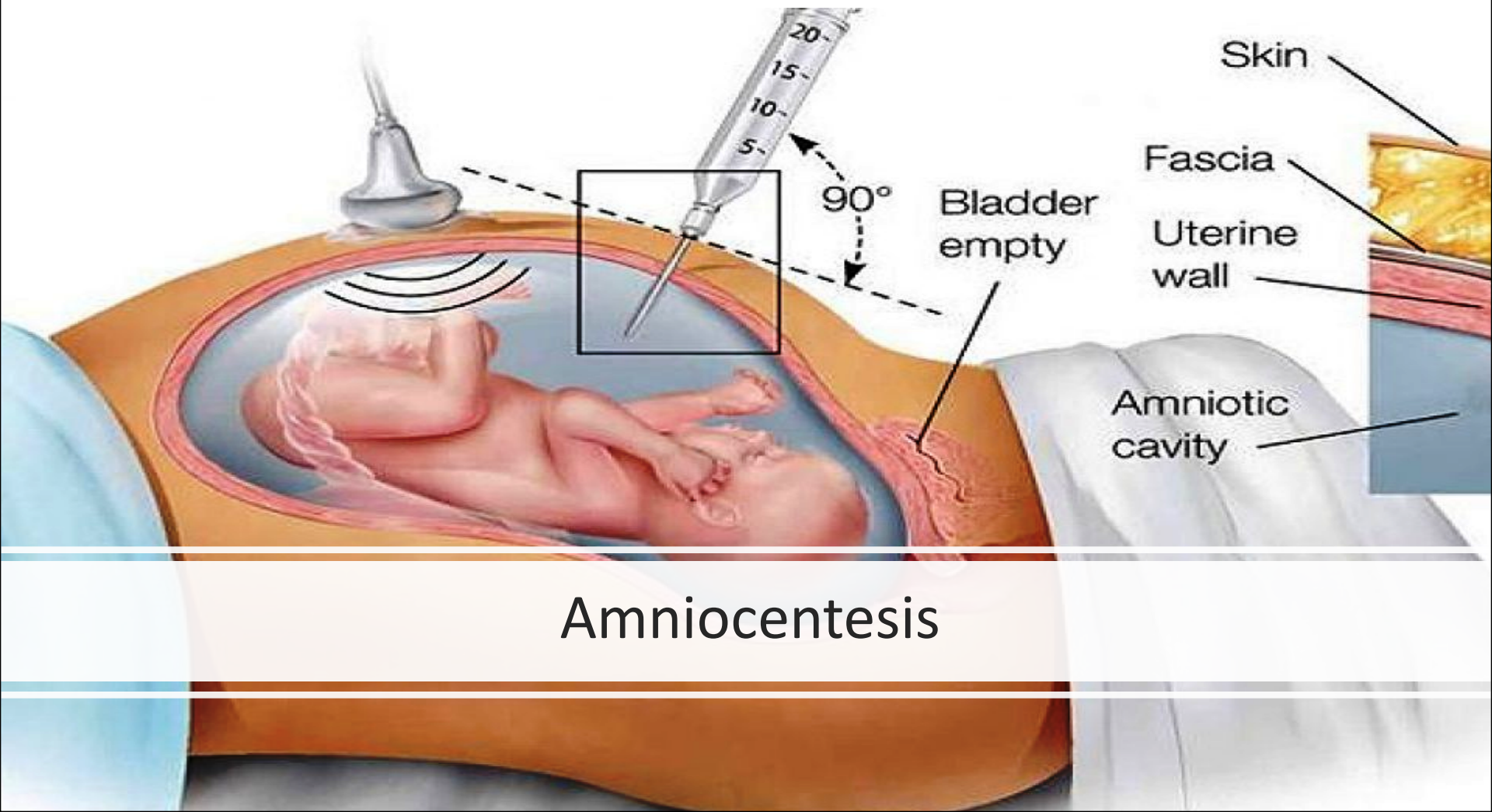
A high maternal serum AFP (≥ 2 multiples of the median for the appropriate week of gestation) between 15-20 weeks gestation carries a relative risk of 224 for neural tube defects.

❖ Ultrasound

Prenatal ultrasound will detect 90-95% of cases of spina bifida, and thus in cases of elevated AFP, it can help differentiate NTDs from non-neurologic causes of elevated AFP (e.g. omphalocele), and can help to more accurately estimate gestational age.

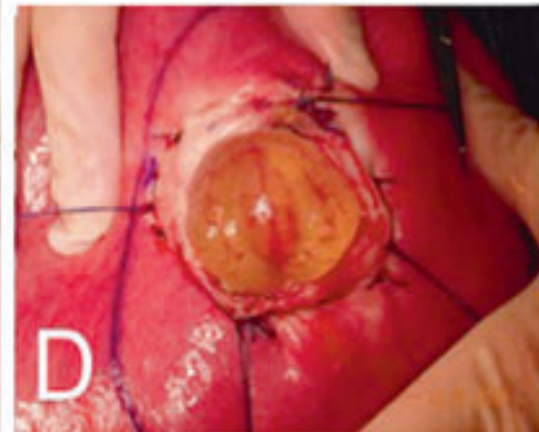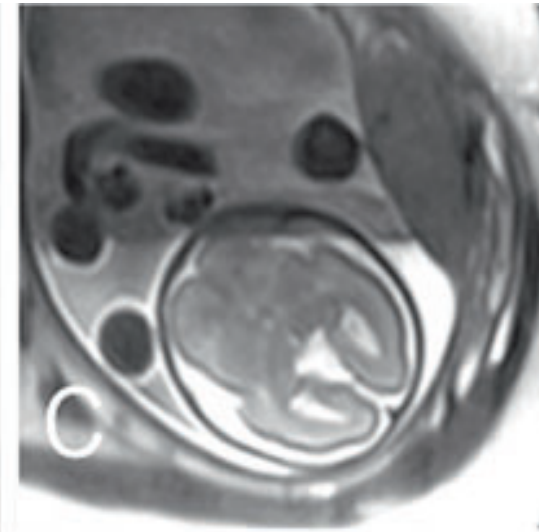
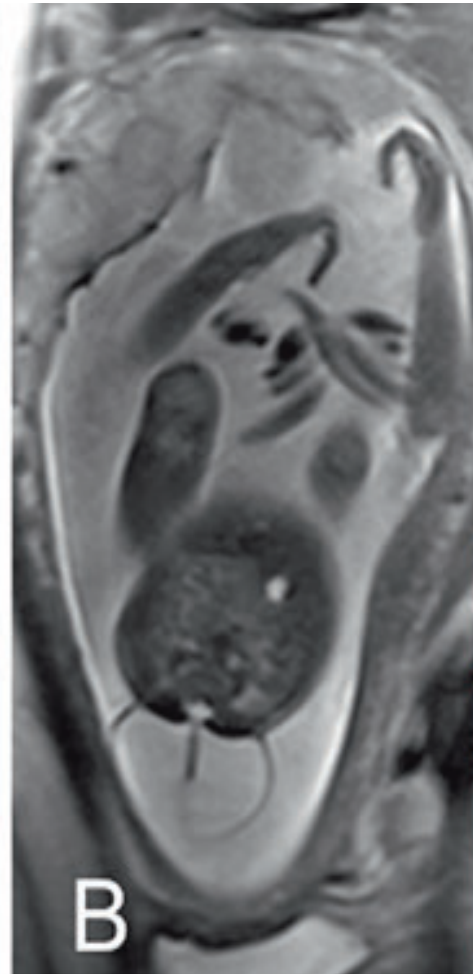
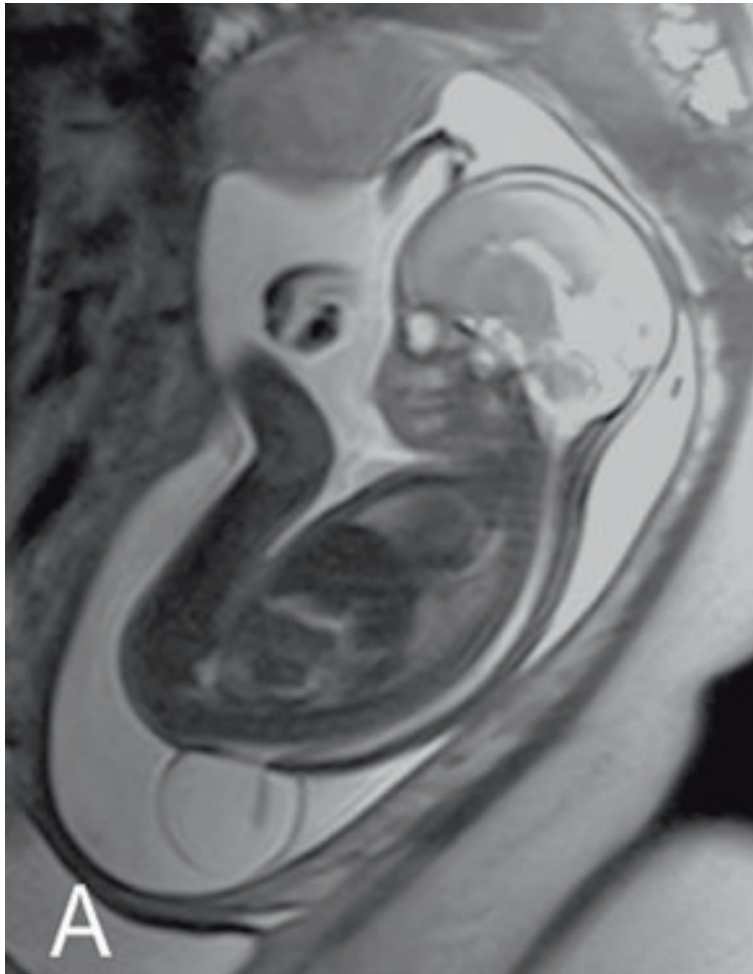
❖ Amniocentesis

For pregnancies subsequent to a MM, if prenatal ultrasound does not show spinal dysraphism, then amniocentesis is recommended (even if abortion is not considered, it may allow for optimal post-partum care if MM is diagnosed). Amniocentesis also carries a $\approx 6\%$ risk of fetal loss in this population.



Amniocentesis

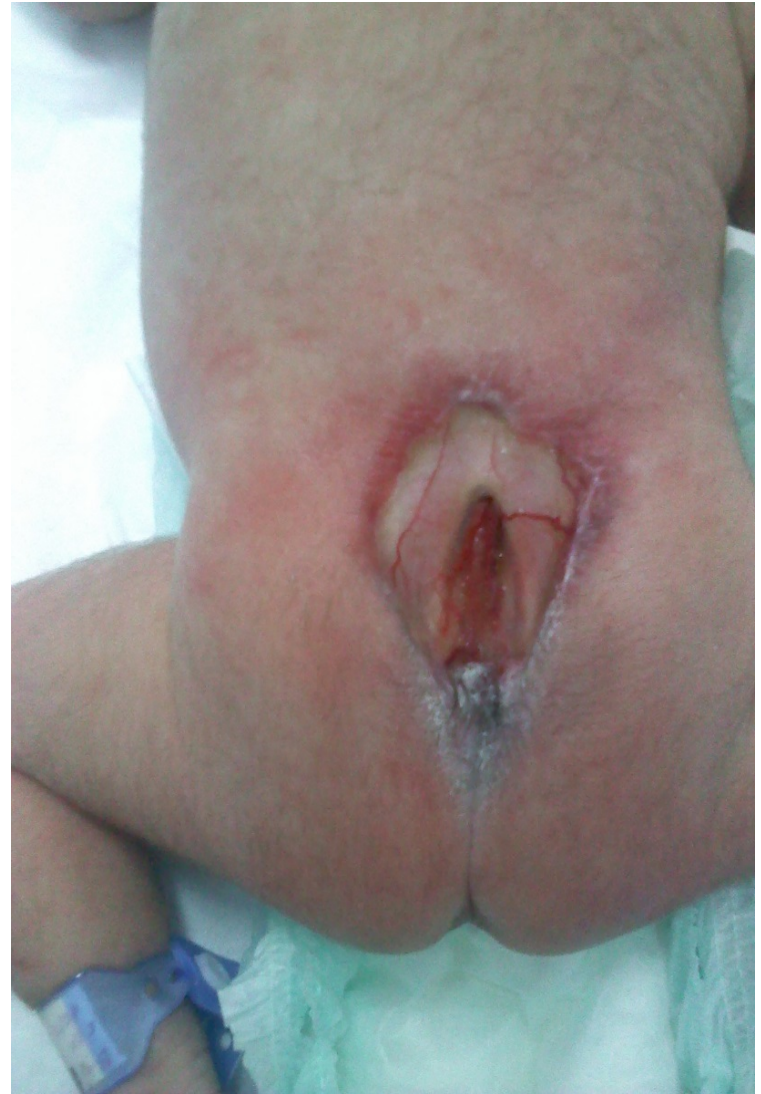Fetal Magnetic Resonance- complementary.



Clinical presentation

Neurological assessment :

- Items related to spinal lesion
 1. Watch for spontaneous movement of the LLs
 2. Assess lowest level of neurologic function by checking response of LLs to painful stimulus:..
- Items related to the commonly associated Chiari type 2 malformation:
 1. Measure OFC(occipitofrontal circumference): risk of developing hydrocephalus.
 2. Head U/S within \approx 24 hrs
 3. Check for inspiratory stridor, apneic episodes



Ancillary assessment and management:

- ❖ Evaluation by neonatologist to assess for other abnormalities, especially those that may preclude surgery (e.g. pulmonary immaturity). There is an average incidence of 2-2.5 additional anomalies in MM patients
- ❖ Bladder: start patient on regular urinary catheterizations, obtain urological consultation(non-emergent)
- ❖ AP & lat spine films: assess scoliosis (baseline)
- ❖ Orthopedic consultation for severe kyphotic or scoliotic spine deformities and for hip or knee deformities

Management

ADMISSION

- assessment and management of lesion:
 - measure size of defect
 - assess whether lesion is ruptured or unruptured
 1. ruptured: start antibiotics
 2. unruptured: no antibiotics necessary
 - cover lesion with telfa or wet dressing , to prevent desiccation
 - Trendelenburg position.
 - perform surgical closure within 36 hrs unless there is a contraindication to surgery

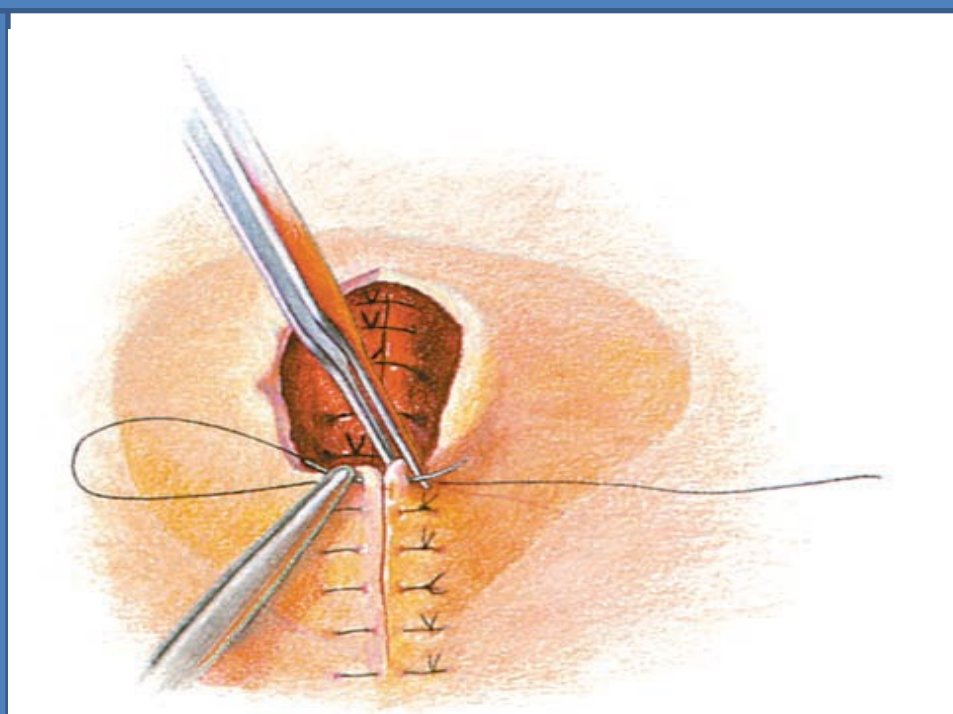
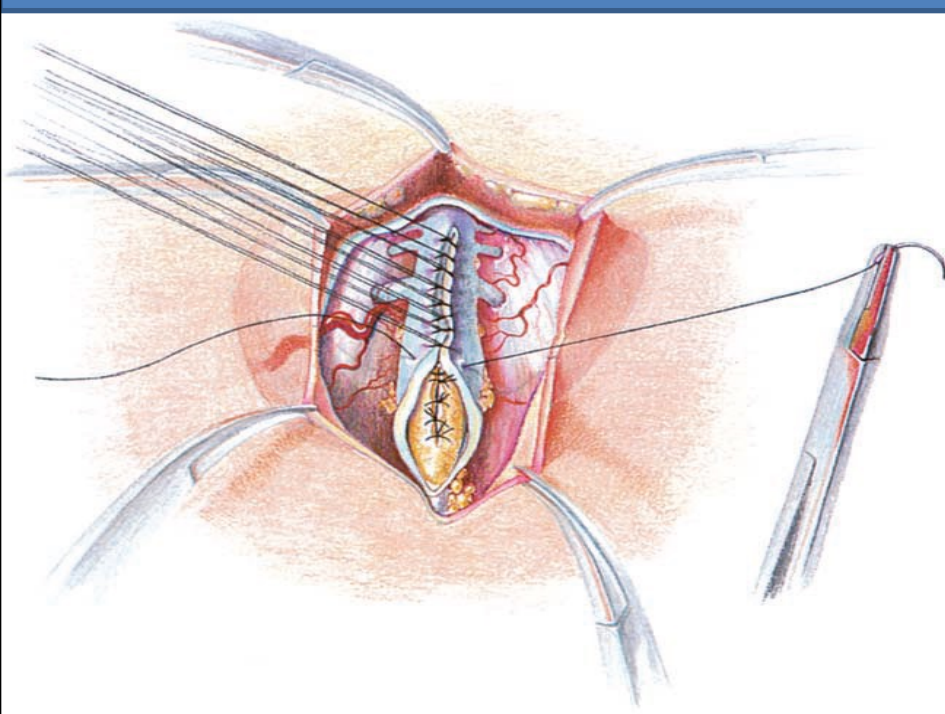
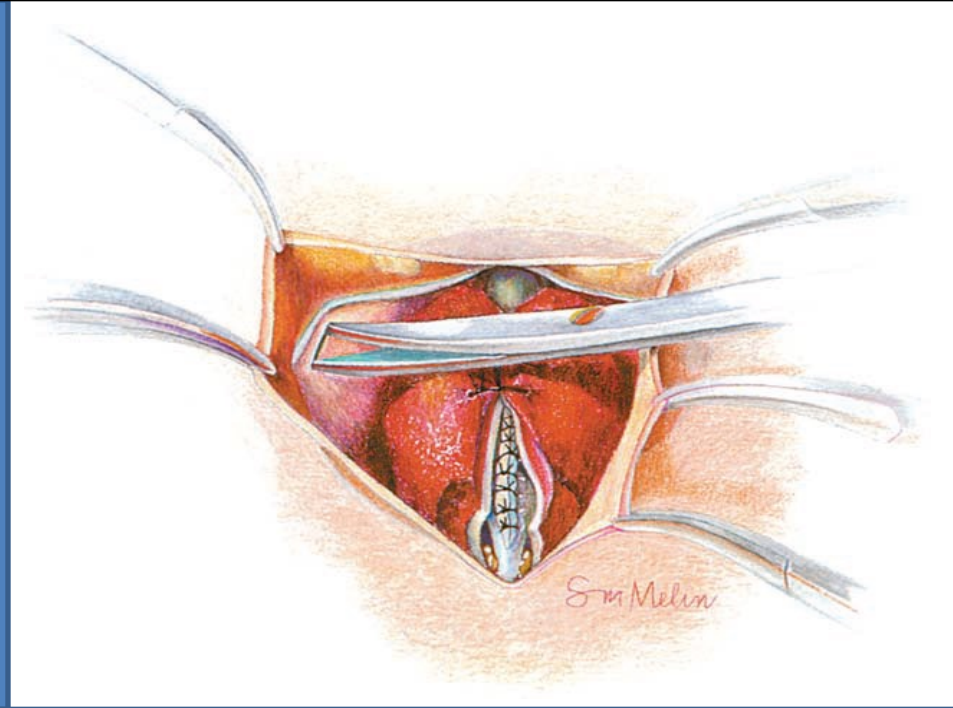
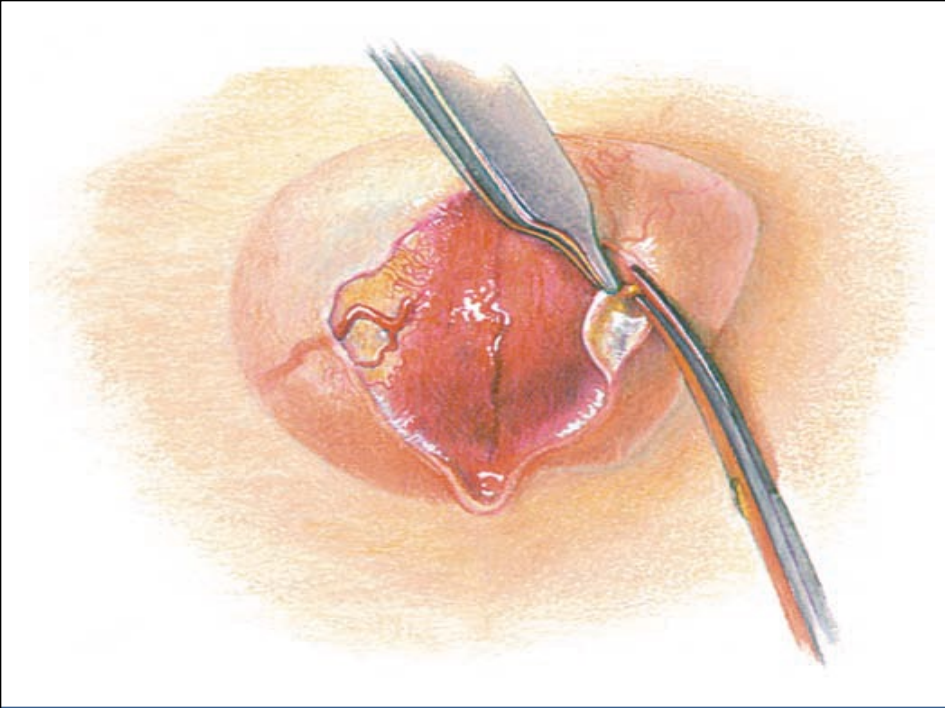
SURGICAL REPAIR

➤ Van Forestus (1610).

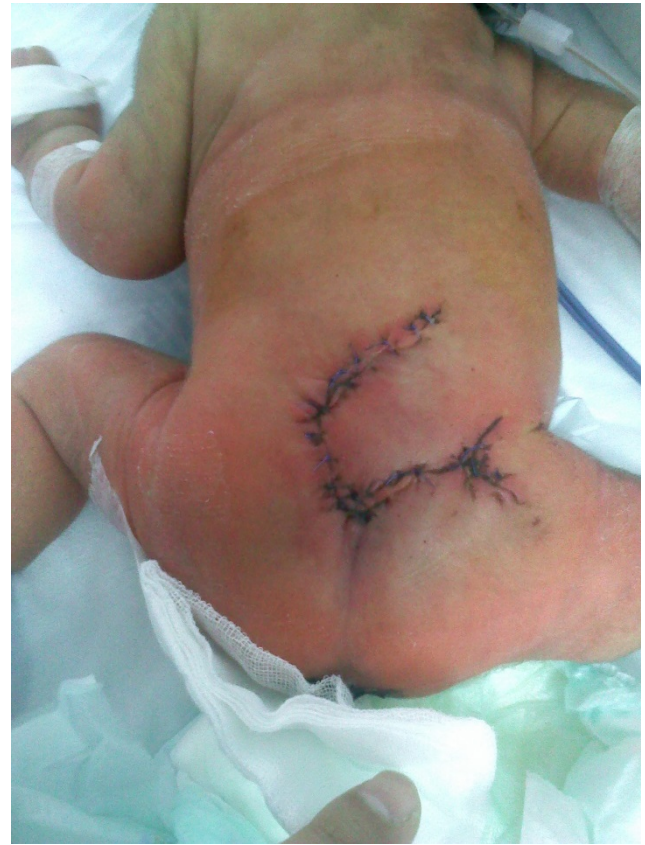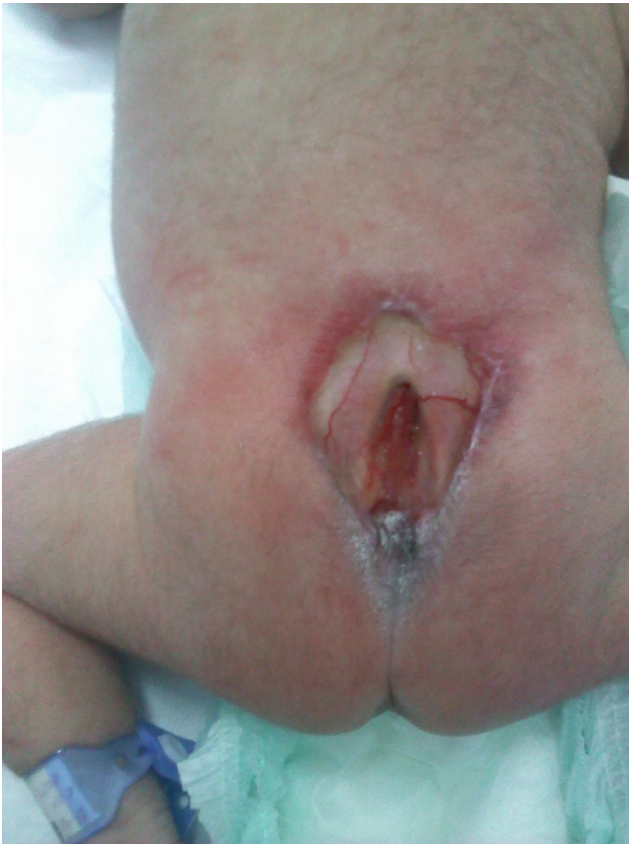➤ *TIMING OF CLOSURE:*

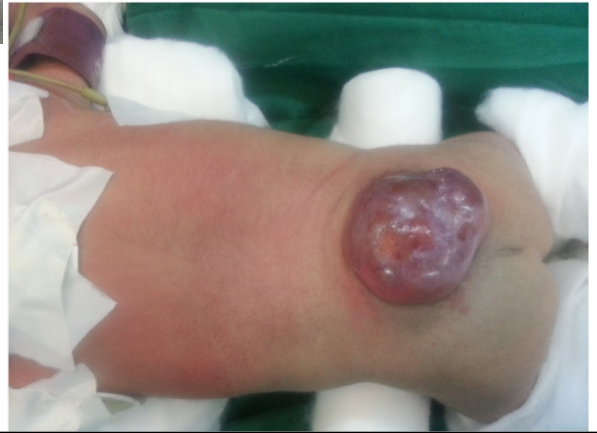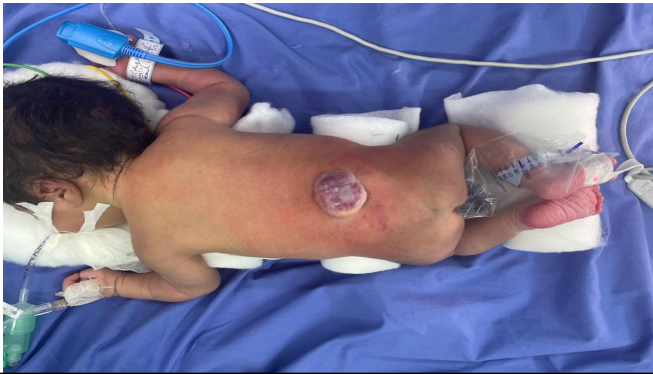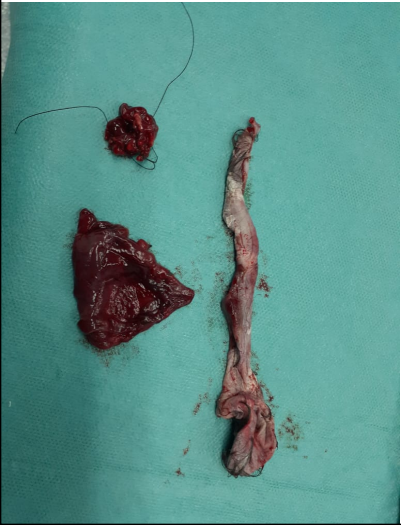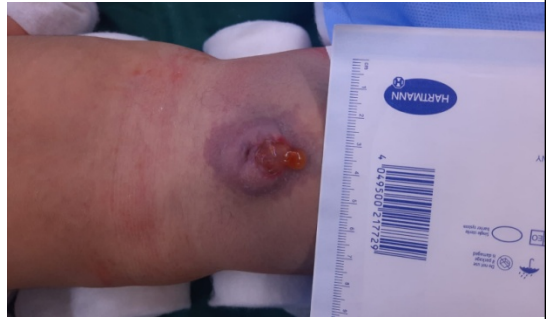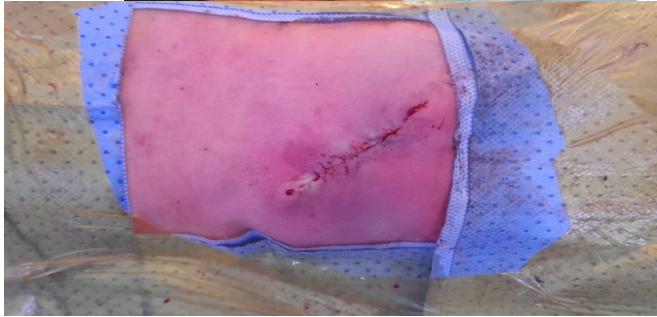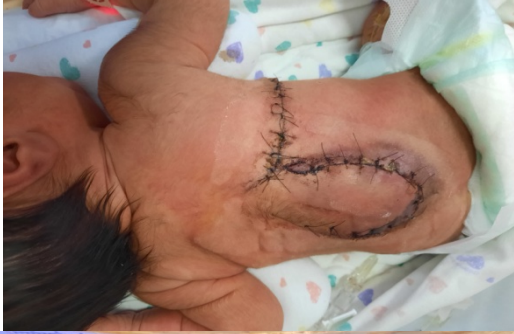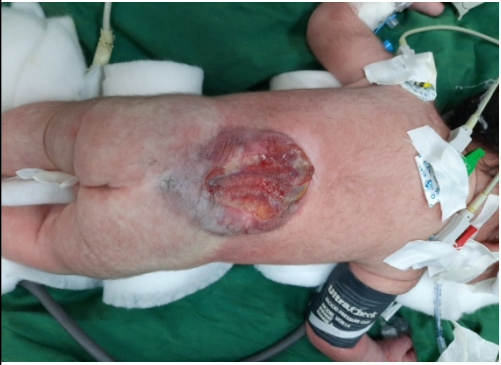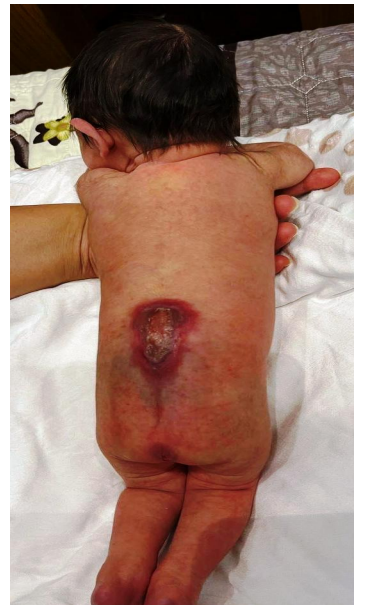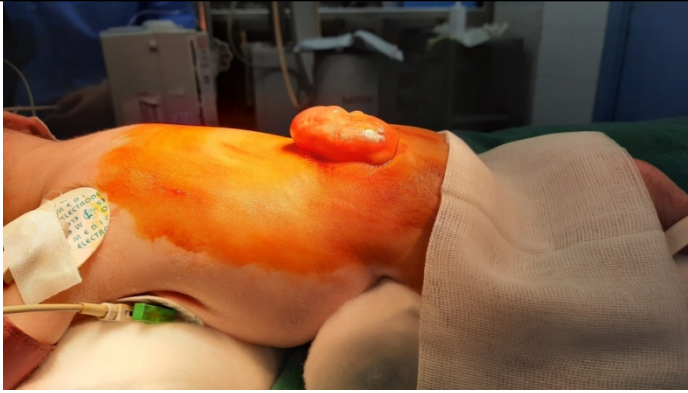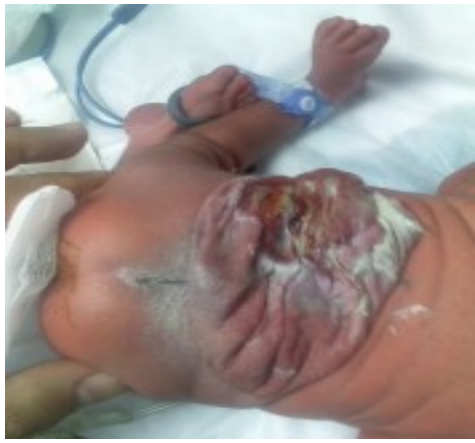Early closure of MM defect is not associated with improvement of neurologic function, BUT evidence supports lower infection rate with early closure.

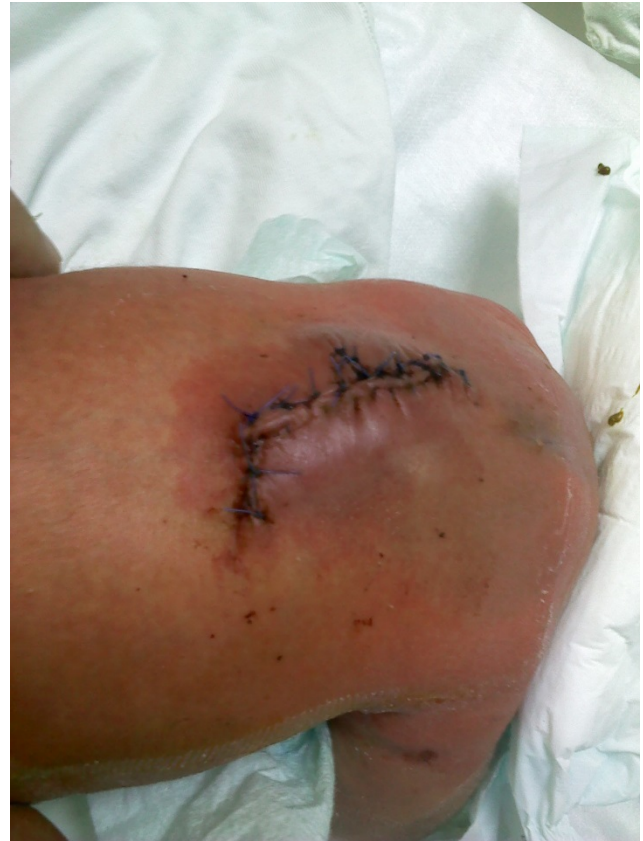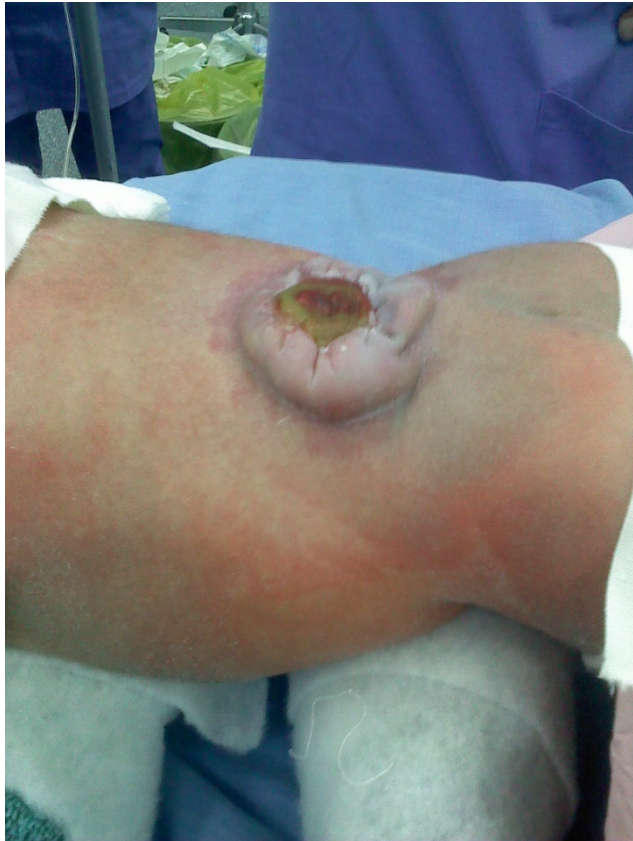MM should be closed within 24 hrs whether or not membrane is intact (after ≈ 36 hrs the back lesion is colonized and there is increased risk of postoperative infection).



MMC repair-from our series









RESEARCH ARTICLES | OCTOBER 13 2015

Fasciocutaneous Flap Reconstruction after Repair of Meningomyelocele: Technique and Outcome

Subject Area: [Neurology and Neuroscience](#), [Surgery](#), [Women's and Children's Health](#)

[Samir Jabaiti](#); [Khaled R. Al-Zaben](#); [Qussay Saleh](#); [Mohammad Abou Alrob](#); [Abdul Rahman Al-Shudifat](#)

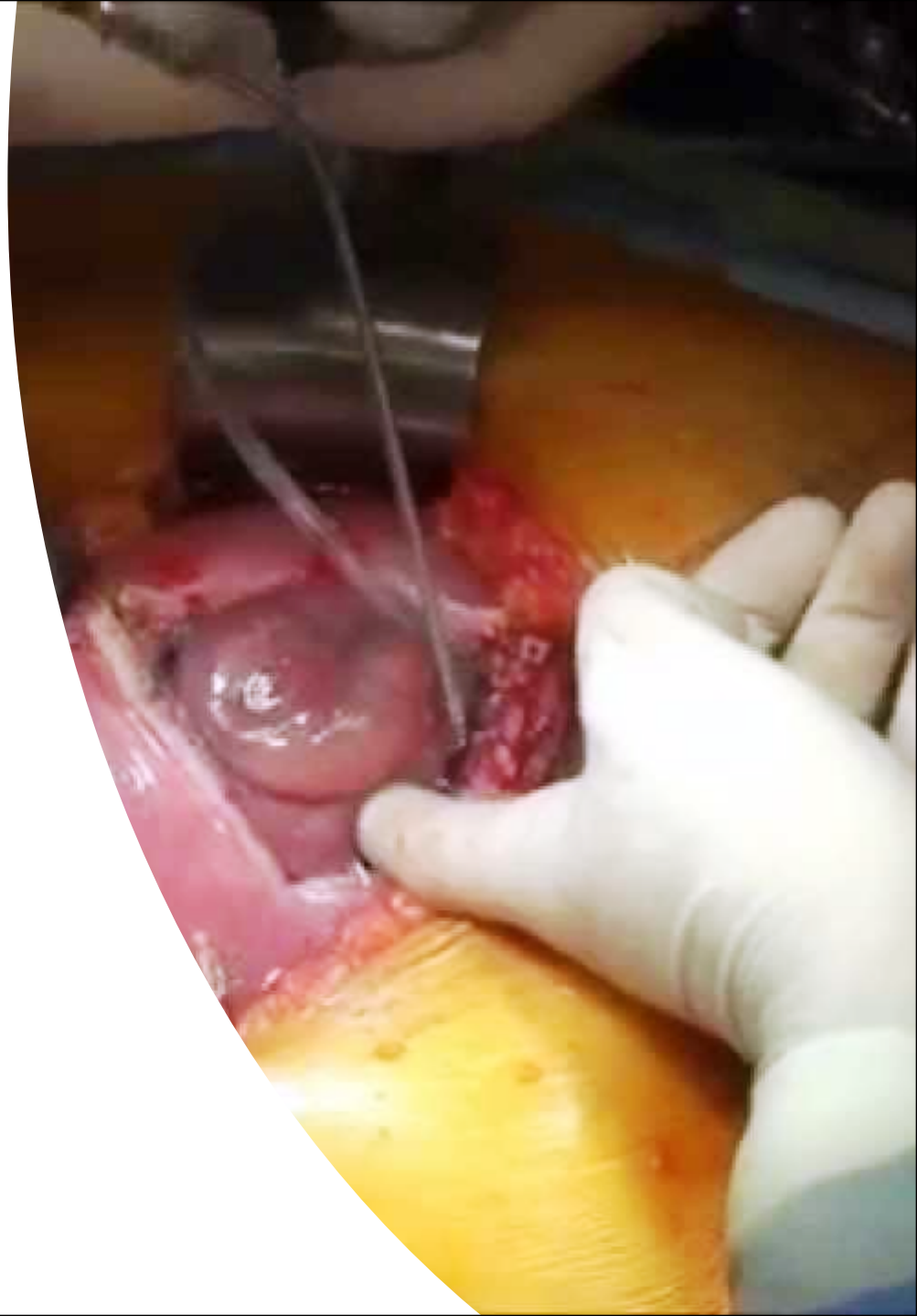Pediatr Neurosurg (2015) 50 (6): 344–349.

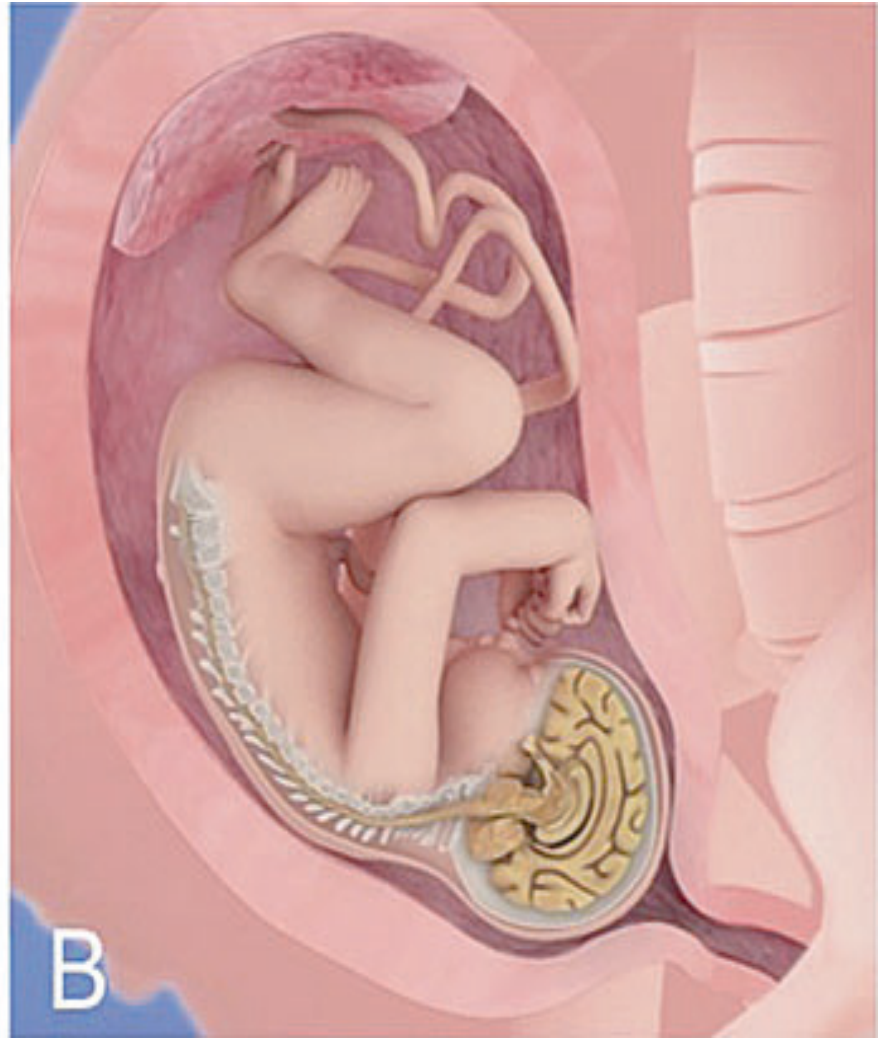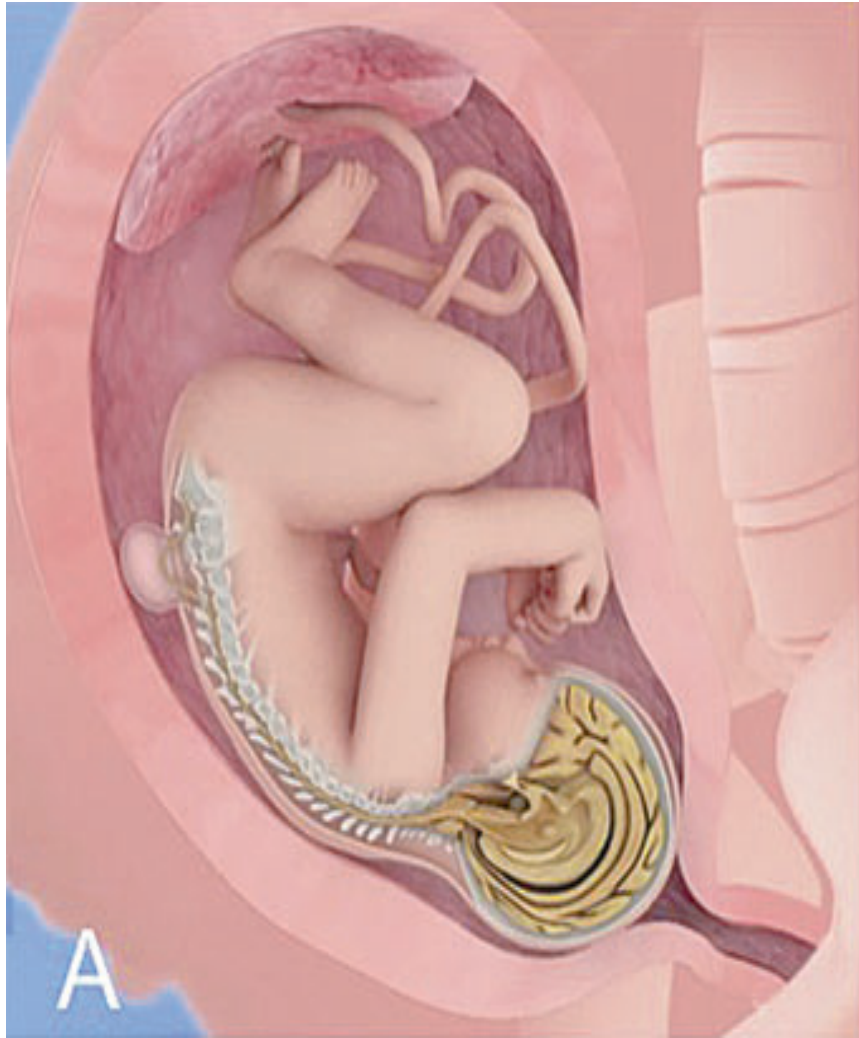<https://doi.org/10.1159/000439283> [Article history](#)

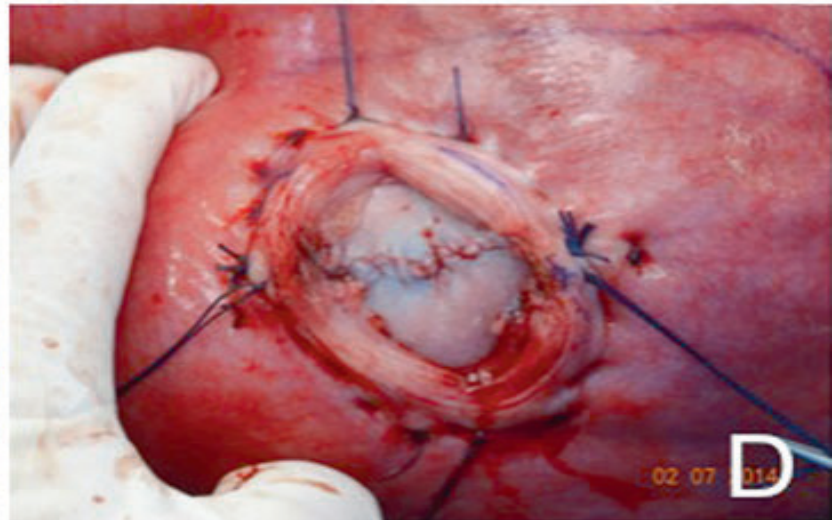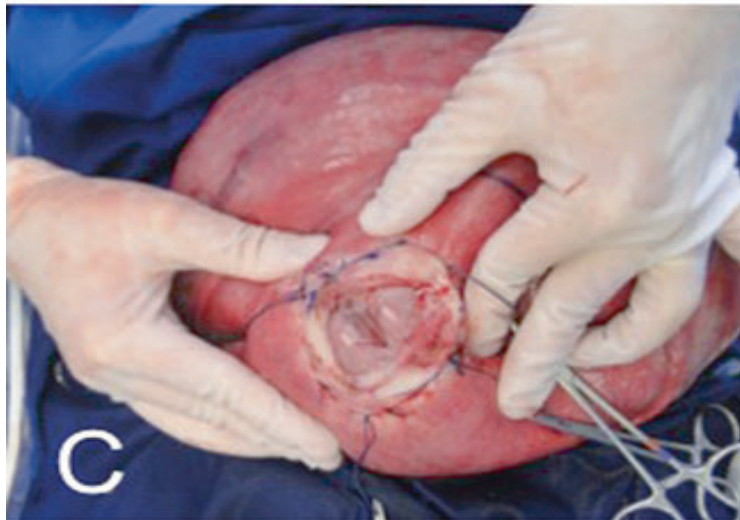
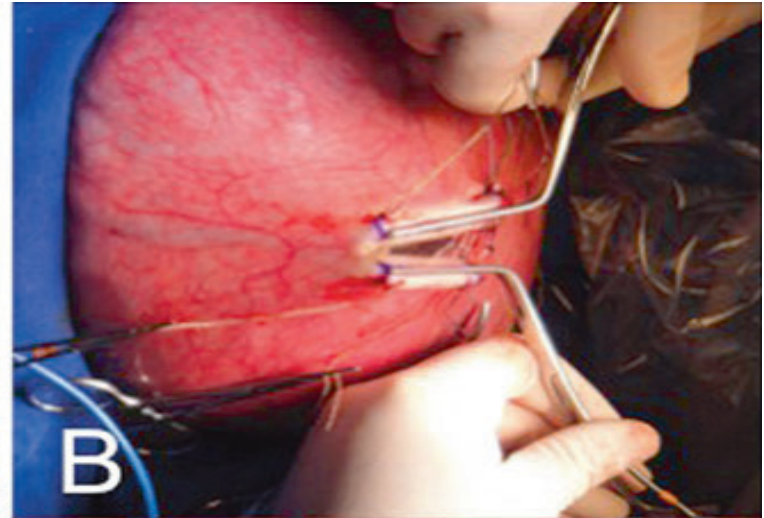
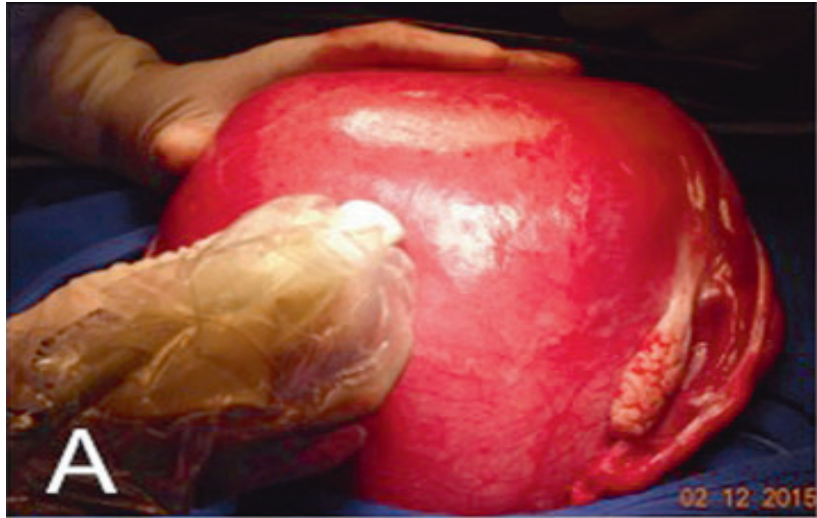
Share Tools

Intrauterine closure of MM defect

-
- Controversial.
 - Does reduce incidence of Chiari II defect, but it has not been determined if this is clinically significant.
 - Argued whether this reduces incidence of hydrocephalus.
 - Does not improve distal neurologic function.







MMC and hydrocephalus

- Incidence of hydrocephalus is 85-90% of all cases of myelomeningocele.
- Usually it is a part of type 2 (arnold)-chiari malformation.
- May not be apparent after birth immediately, may be seen as far as 2 years ,but most cases will need shunt by the age of 6 months.

Simultaneous MM defect closure and VP shunting

- In patients without hydrocephalus, most surgeons wait at least ≈ 3 days after MM repair before shunting.
- In MM patients with clinically overt HCP at birth (ventriculomegaly with enlarged OFC and/or symptoms), MM repair and shunting may be performed in the same sitting without increased incidence of infection, and with shorter hospitalization.

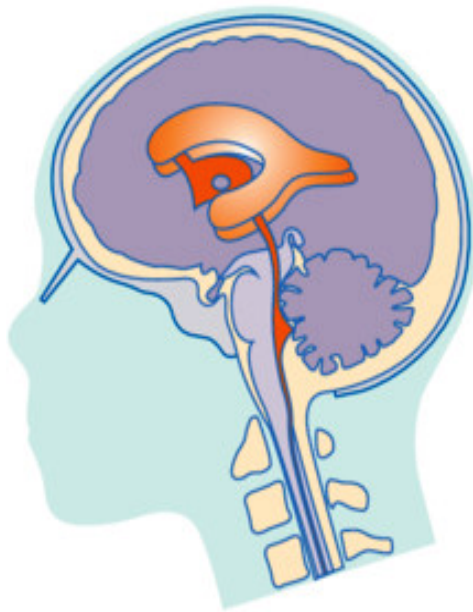
Chiari malformations

- Basically they are hindbrain malformations, with associated anomalies that may involve the rest of the CNS.
- The term “Chiari malformation” (after pathologist, Hans Chiari) is preferred for type 1 malformations, with the commonly used term “Arnold-Chiari malformation” reserved for type 2 malformation.

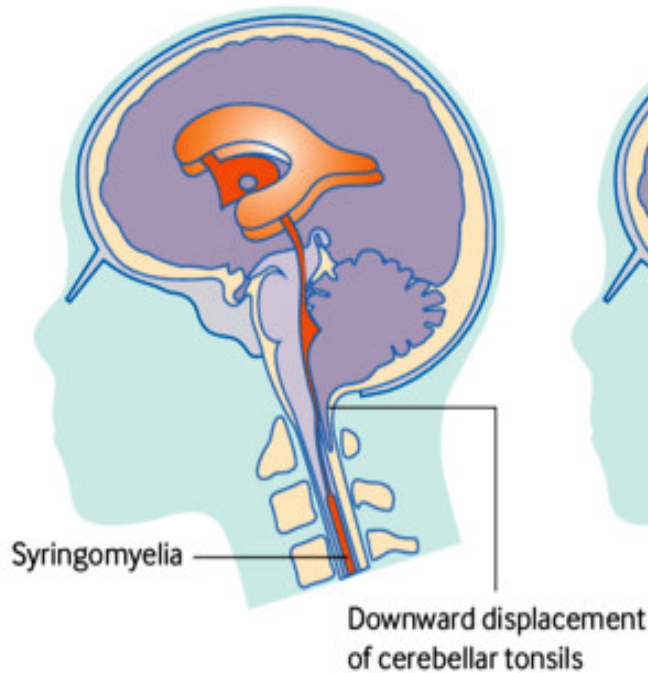
➤ The Chiari malformations consists of four types of hindbrain abnormalities, probably unrelated to each other.

The majority are types 1 or 2), a very limited number of cases comprise the remaining types

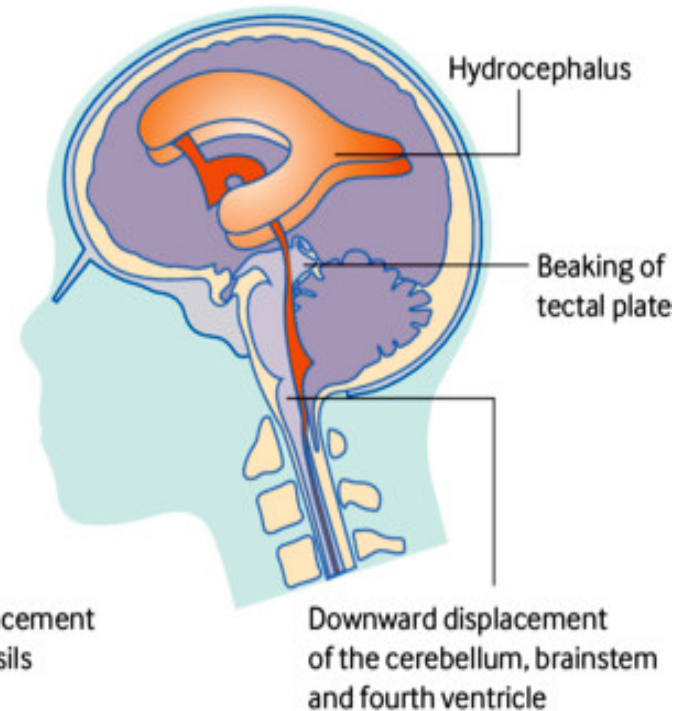
Normal



Chiari 1 malformation



Chiari 2 malformation



Finding	Chiari type 1 (<i>see below</i>)	Chiari type 2 (<i>see page 238</i>)
caudal dislocation of medulla	unusual	yes
caudal dislocation into cervical canal	tonsils	inferior vermis, medulla, 4th ventricle
spina bifida (myelomeningocele)	may be present	rarely absent
hydrocephalus	may be absent	rarely absent
medullary "kink"	absent	present in 55%
course of upper cervical nerves	usually normal	usually cephalad
usual age of presentation	young adult	infancy
usual presentation	cervical pain, suboccipital H/A	progressive hydrocephalus, respiratory distress

LATE PROBLEMS/ISSUES

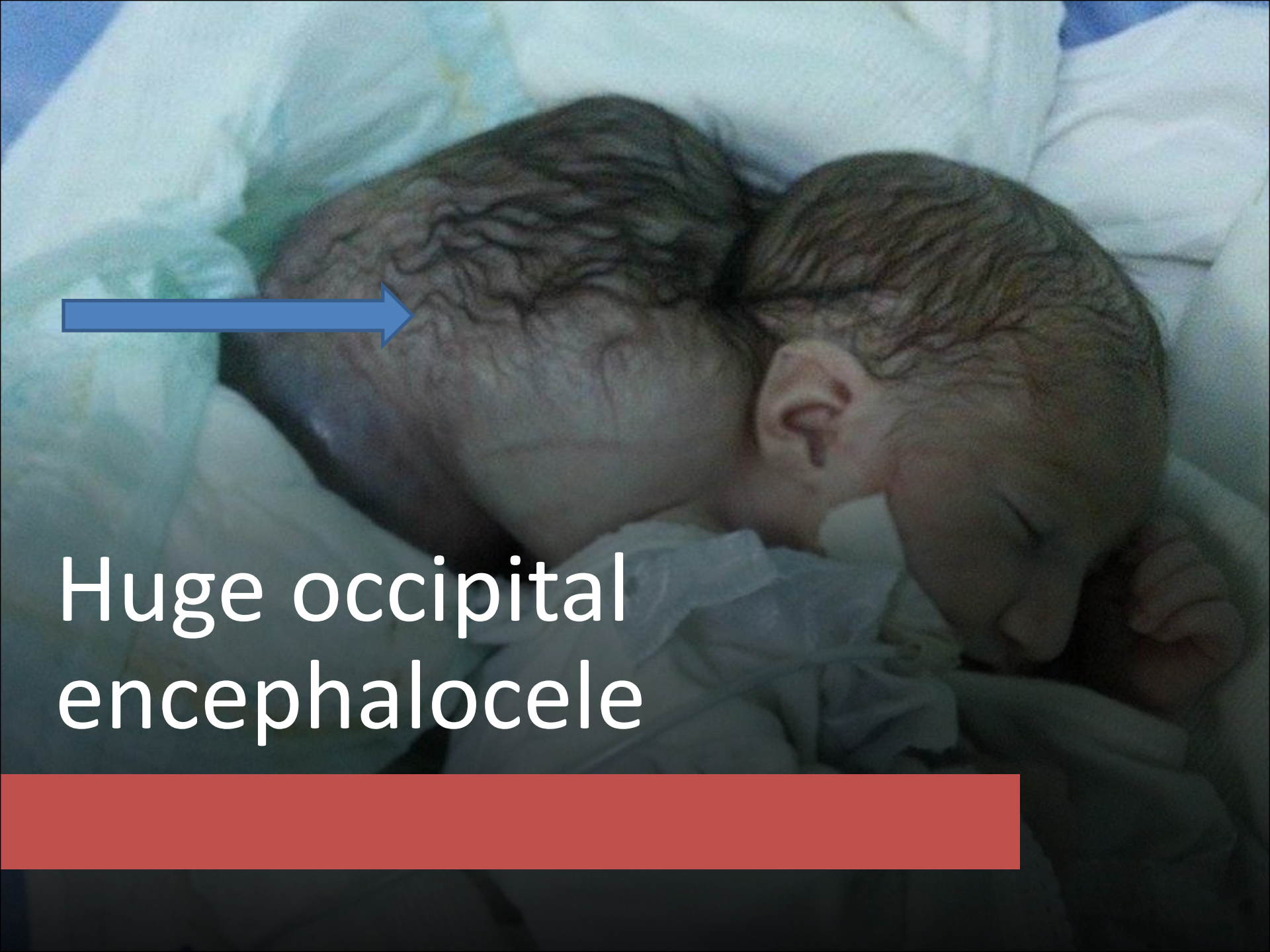Include:

- 1. Hydrocephalus: may mimic ≈ anything listed below. always rule out shunt malfunction when a MM patient deteriorates
- 2. Syringomyelia (and/or syringobulbia):
- 3. Tethered cord as many as 70% of MM patients have a tethered cord radiographically (some quote 10-20%), but only a minority are symptomatic.
- 4. Dermoid tumor at the MM site¹³¹: incidence ≈ 16% .
- 5. Medullary compression at foramen magnum (symptomatic Chiari II malformation).

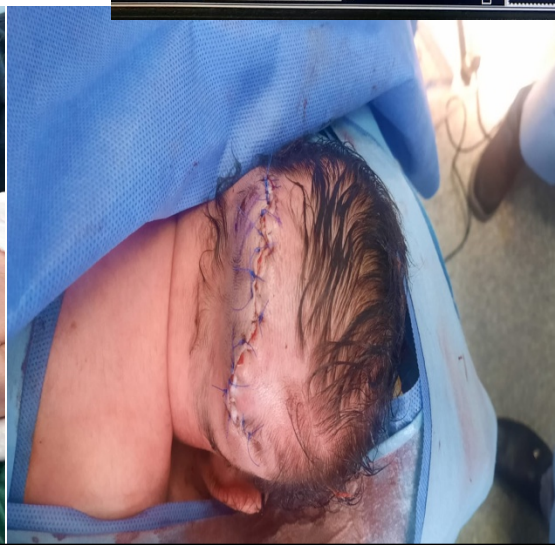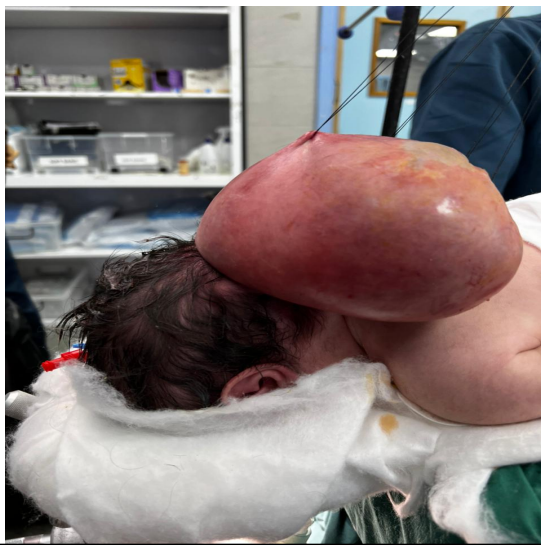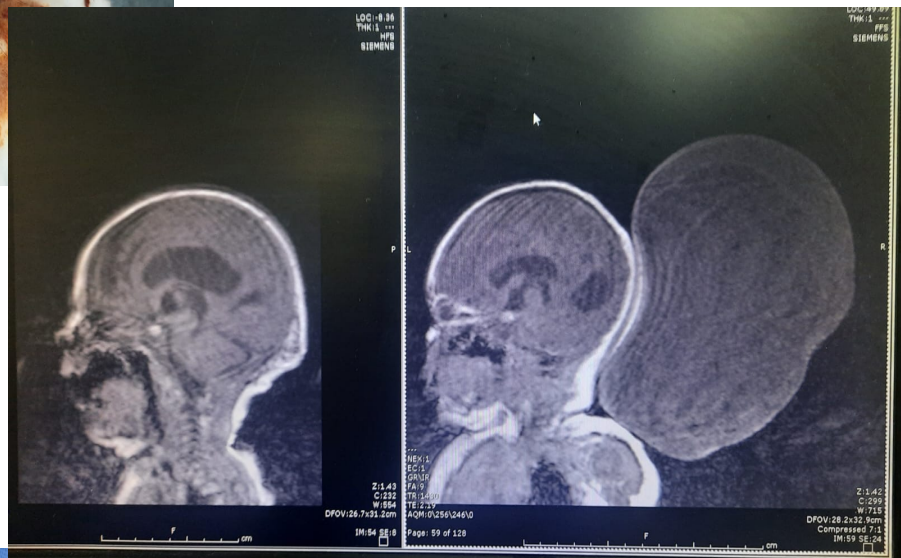
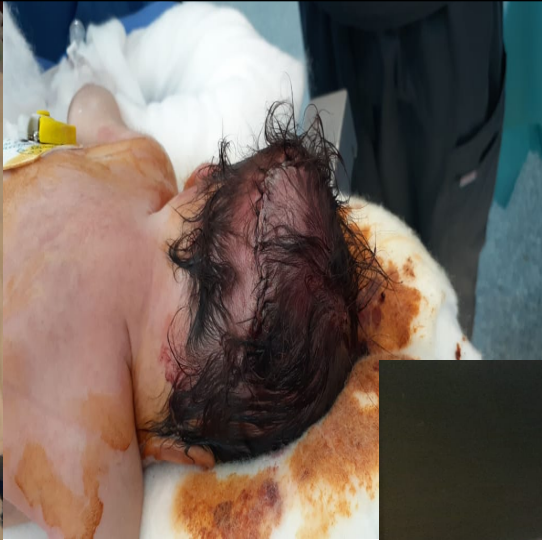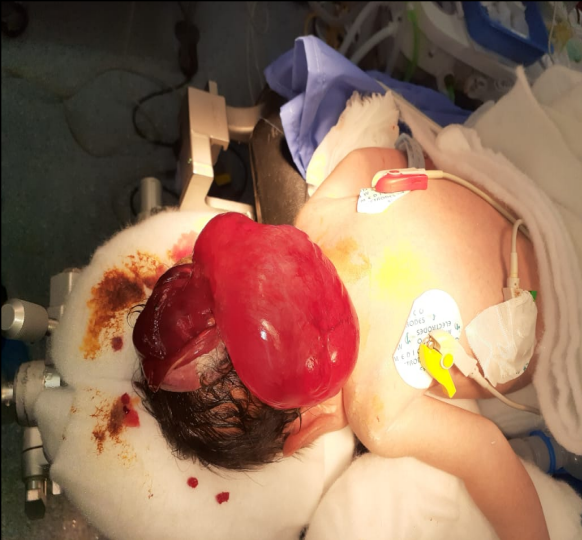OUTCOME

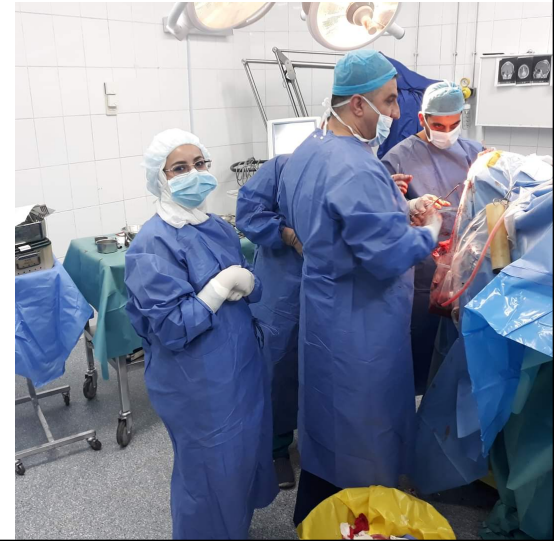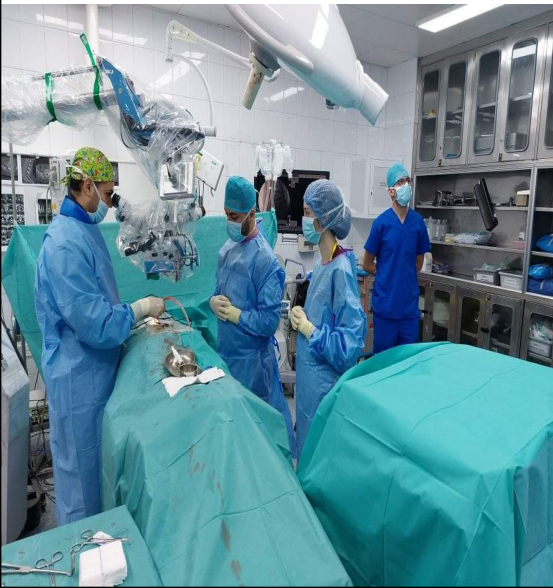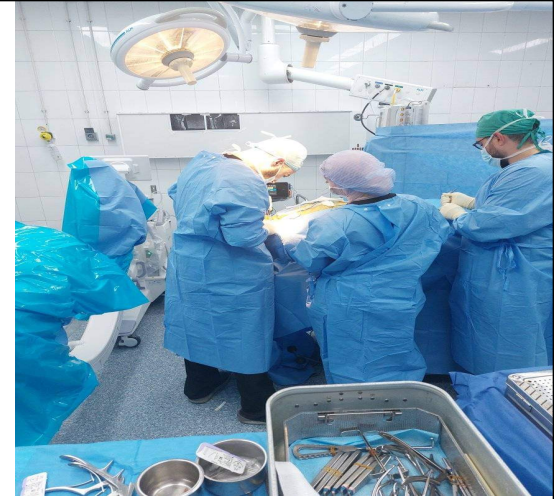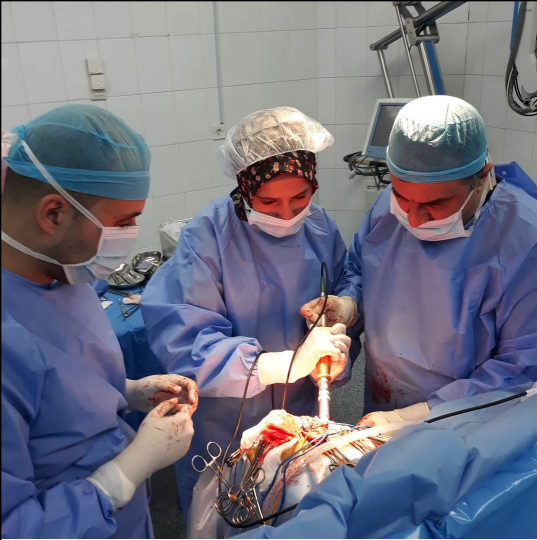- Without any treatment, only 14-30% of MM infants survive infancy; these usually represent the least severely involved.
- With modern treatment, \approx 85% of MM infants survive.
- The most common cause of early mortality are complications from the Chiari malformation (respiratory arrest, aspiration...), where late mortality is usually due to shunt malfunction.

- 80% will have normal IQ. Mental retardation is most closely linked to shunt infection. 40-85% are ambulatory with bracing, however, most choose to use wheelchairs for ease.
- 3-10% have normal urinary continence, but most may be able to remain dry with intermittent catheterization.



Huge occipital
encephalocele





And here we
come to the:

THE END

