

Obstetrics and Gynecology clinical skills

Dr. Fida Thekrallah

April-2020

- Obstetric examination
- Clinical pelvimetry
- Engagement diameters
- Speculum examination
- IUCD insertion
- Pap smear

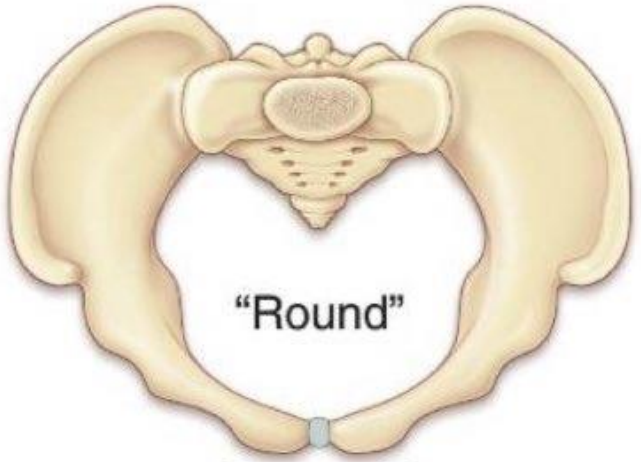Obstetric examination

- Obstetric examination
- <https://youtu.be/xb12lkpbfTQ>
- <https://youtu.be/oaPdQHkuOyc>
- https://youtu.be/clUR_EuVxdA
- <https://youtu.be/aPWrXA57rZ8>

Clinical pelivmetry

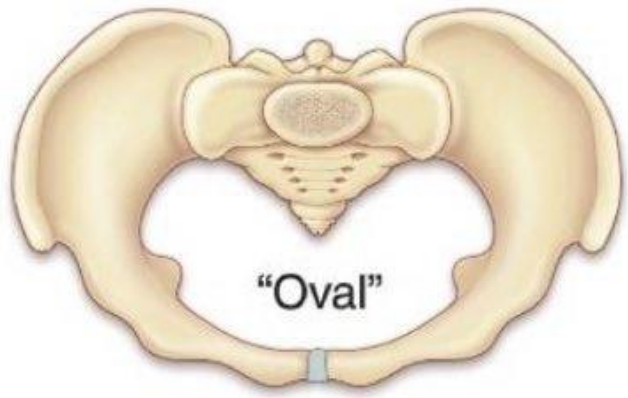
- <https://youtu.be/Y5REgaAFfFE>
- <https://youtu.be/kTwxNFTP-YA>
- <https://youtu.be/1whFvJ3wCYE>

Types of female pelvis



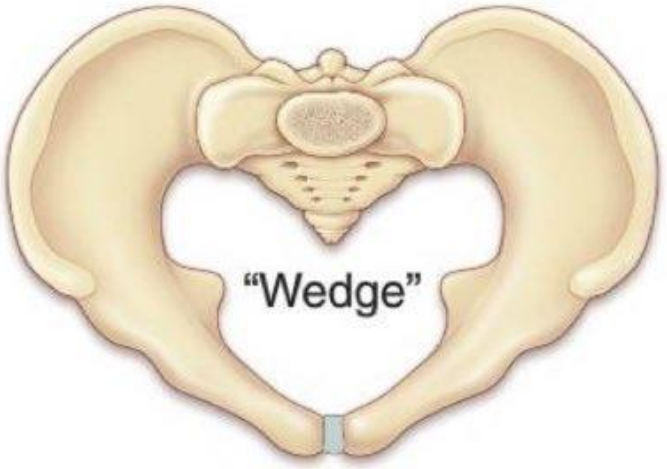
"Round"

Gynecoid



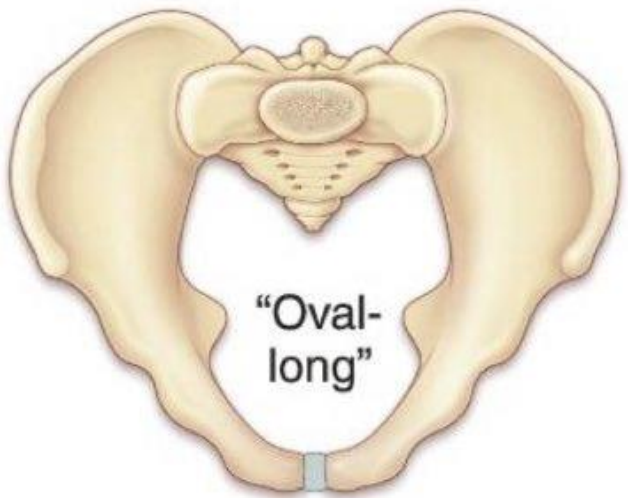"Oval"

Platypelloid



"Wedge"

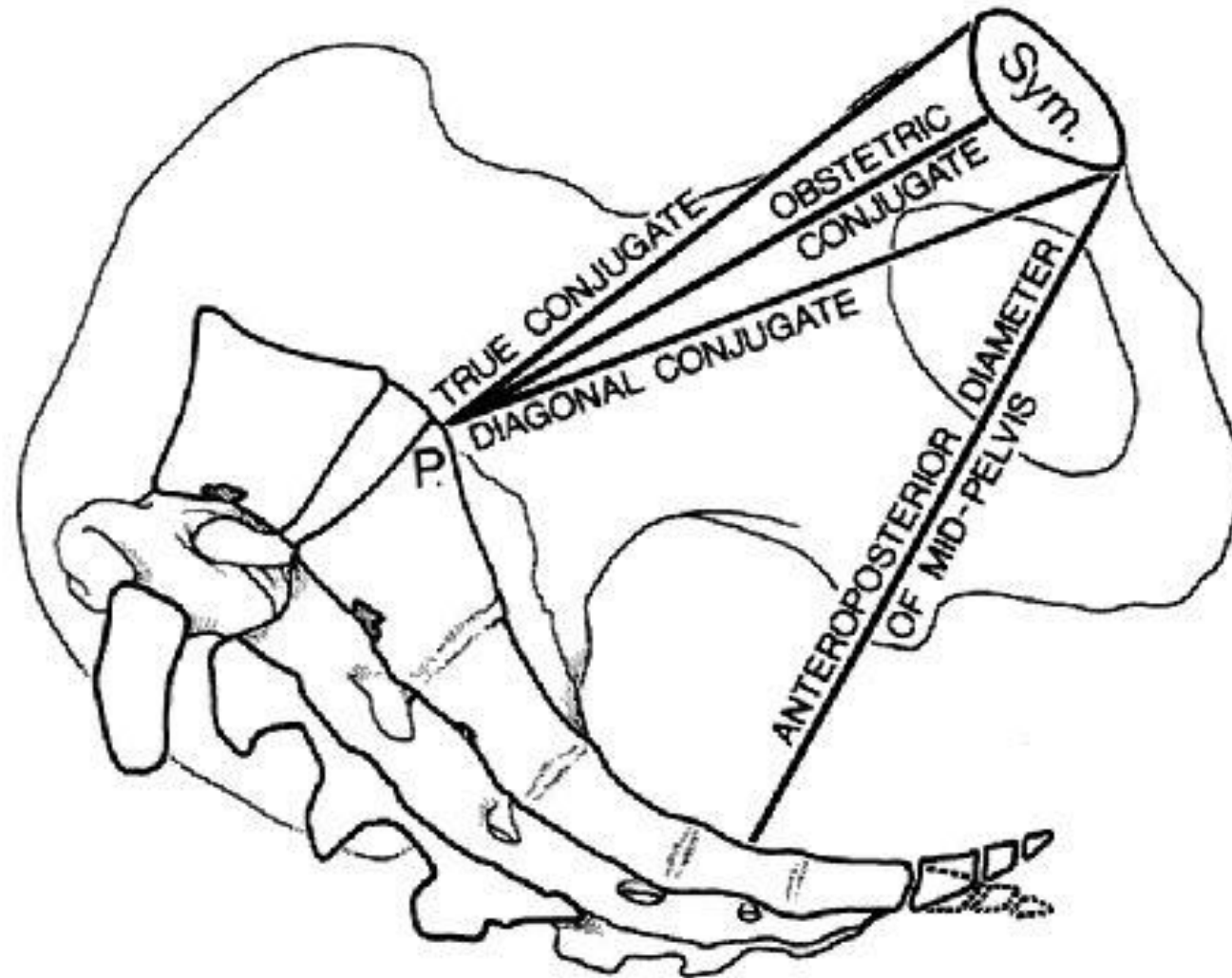
Android



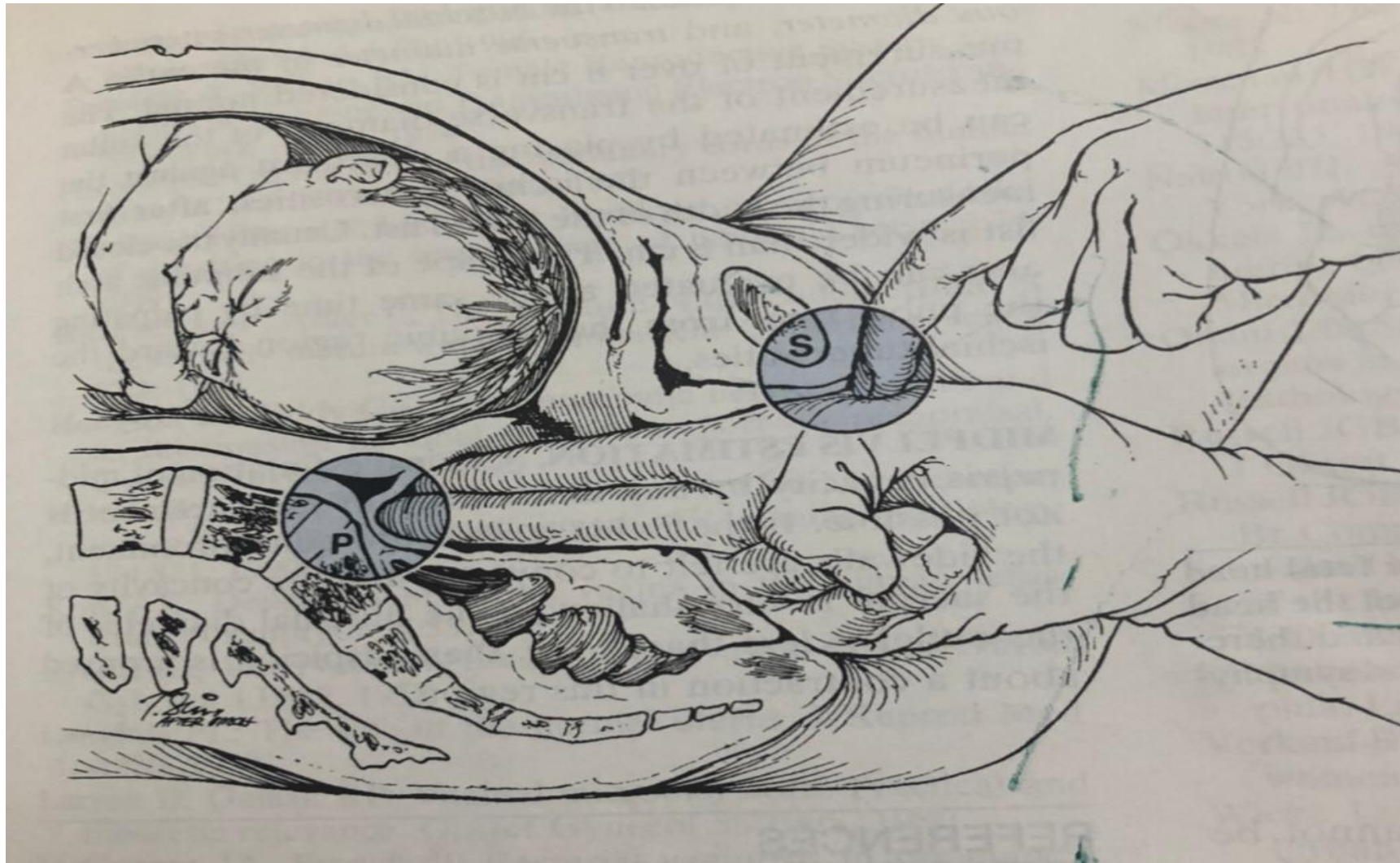
"Oval-long"

Anthropoid

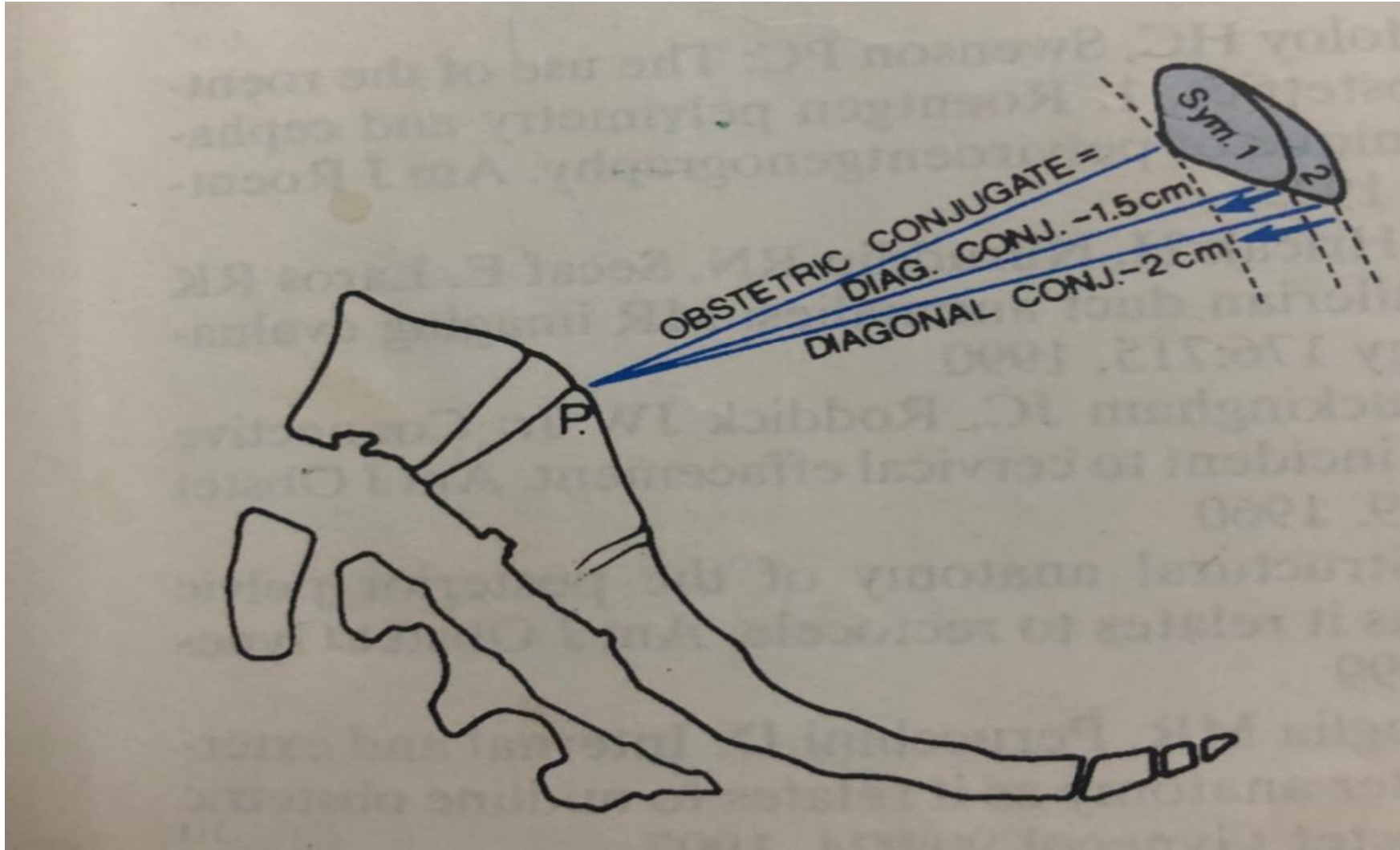
Clinical pelvimetry



Diagonal conjugate

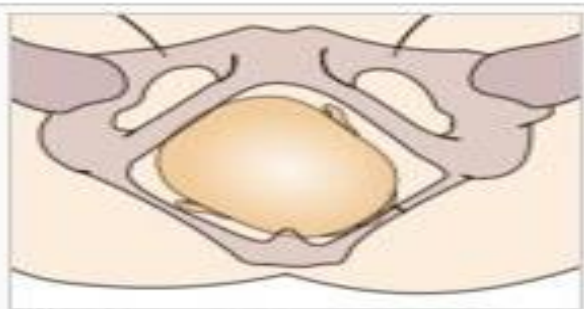


Clinical pelvimetry

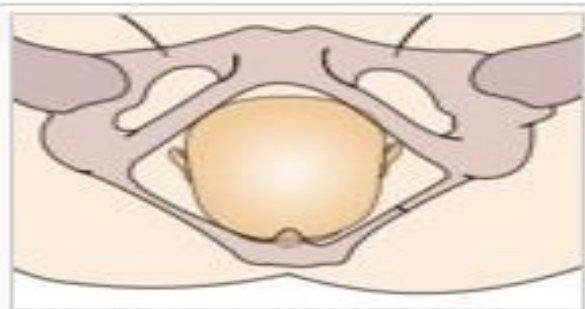


Fetal skull

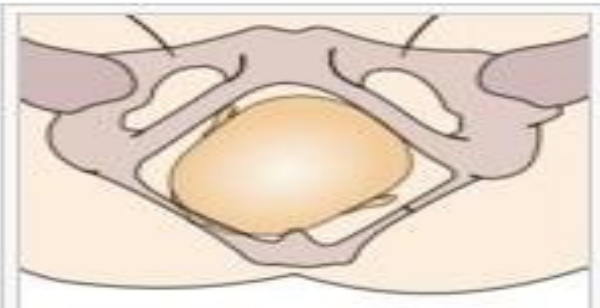
- <https://youtu.be/k4AfEzVC9a8>



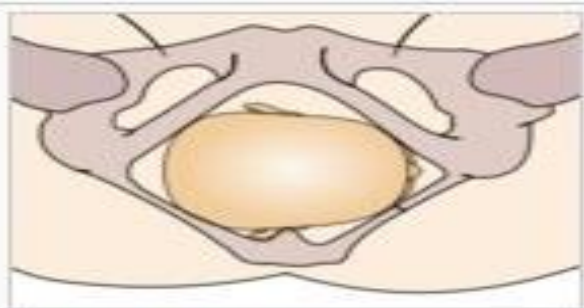
Right occipito-anterior



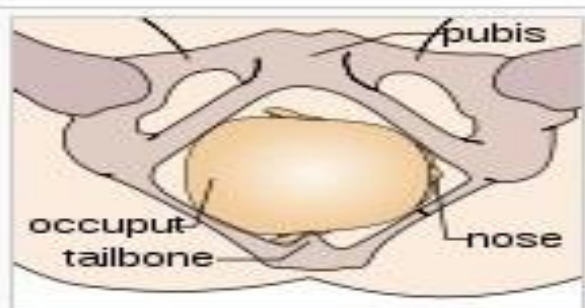
Straight occipito-anterior



Left occipito-anterior

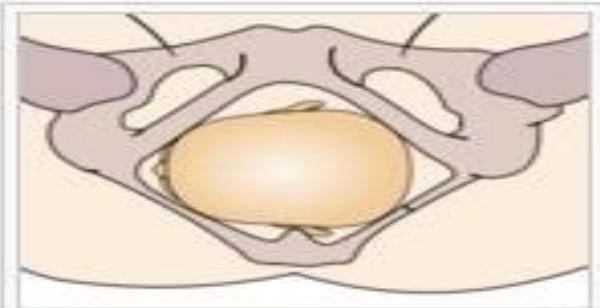


Right occipito-transverse

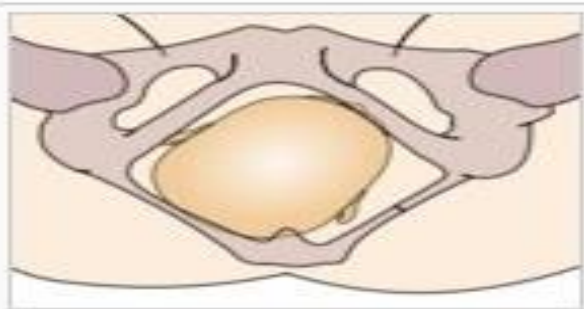


occiput
tailbone

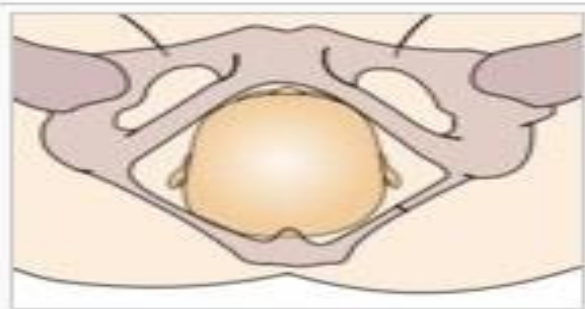
nose



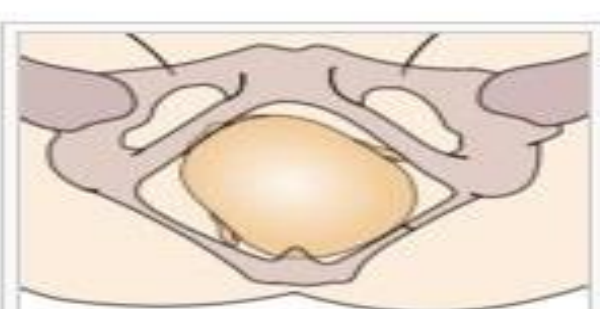
Left occipito-transverse



Right occipito-posterior

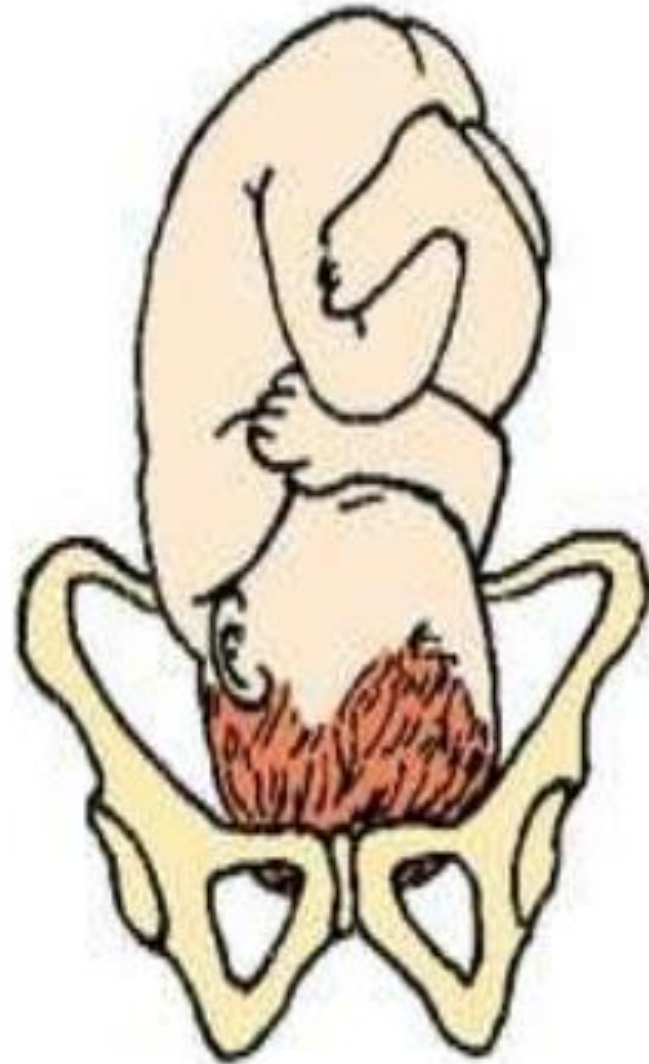
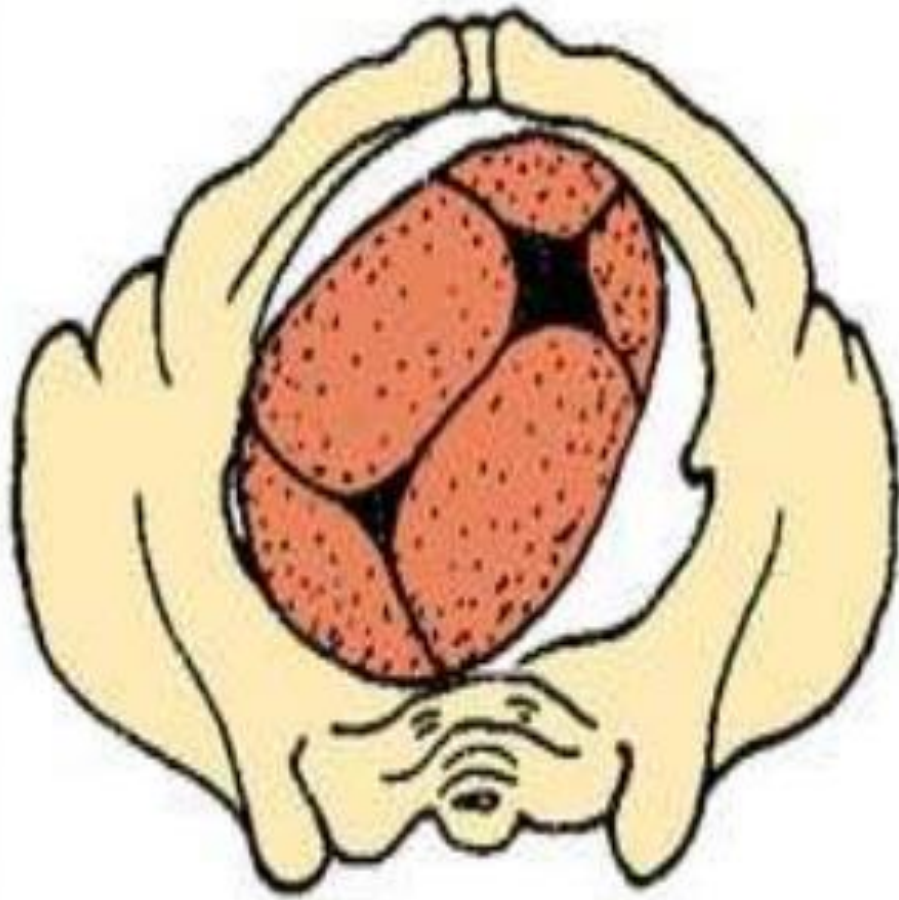


Straight occipito-posterior



Left occipito-posterior

ROP



Fetal skull

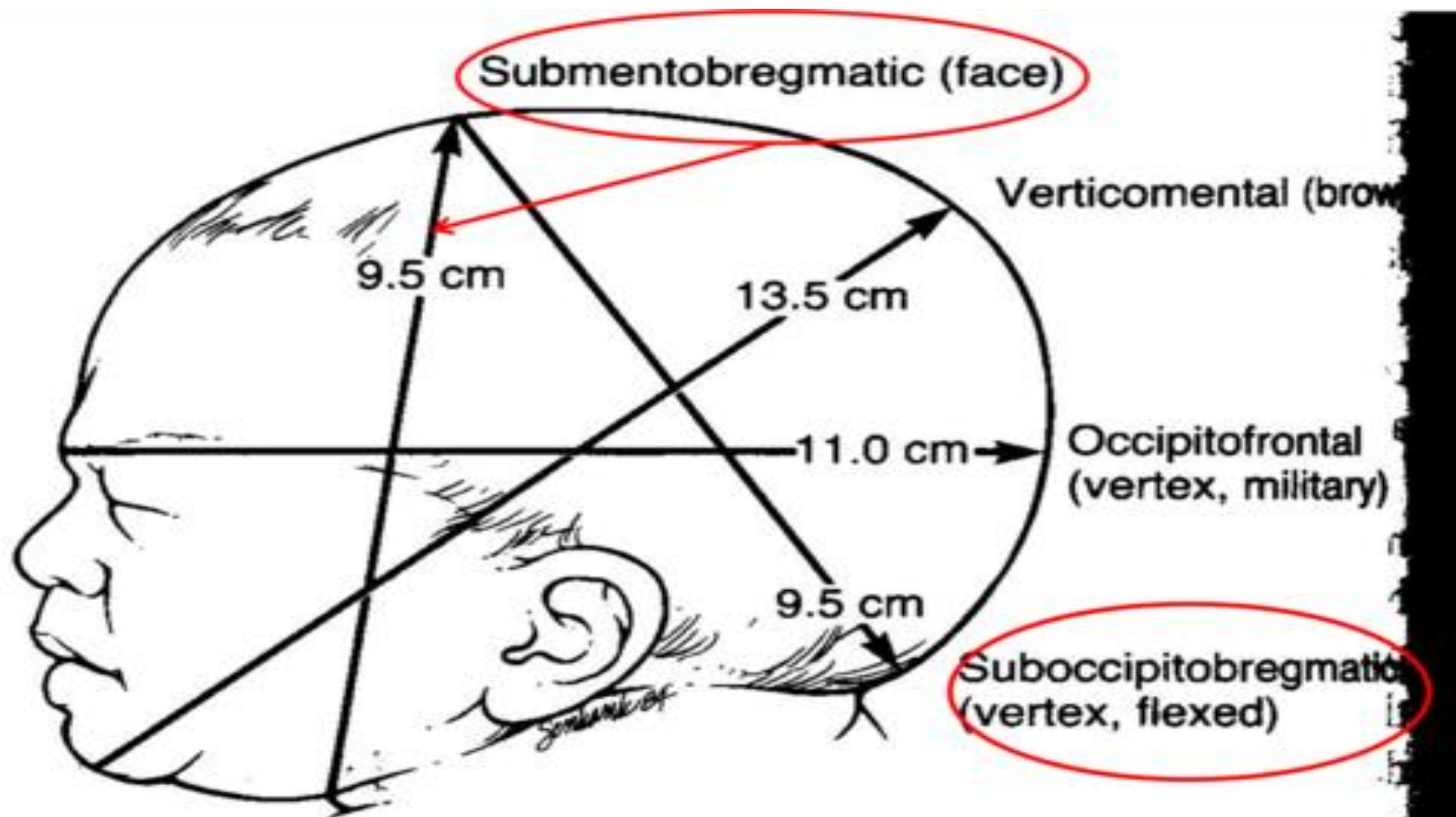


Fig. 13-2 Possible presenting diameters of the average term fetal skull.

Gynecology examination

- Prerequisite

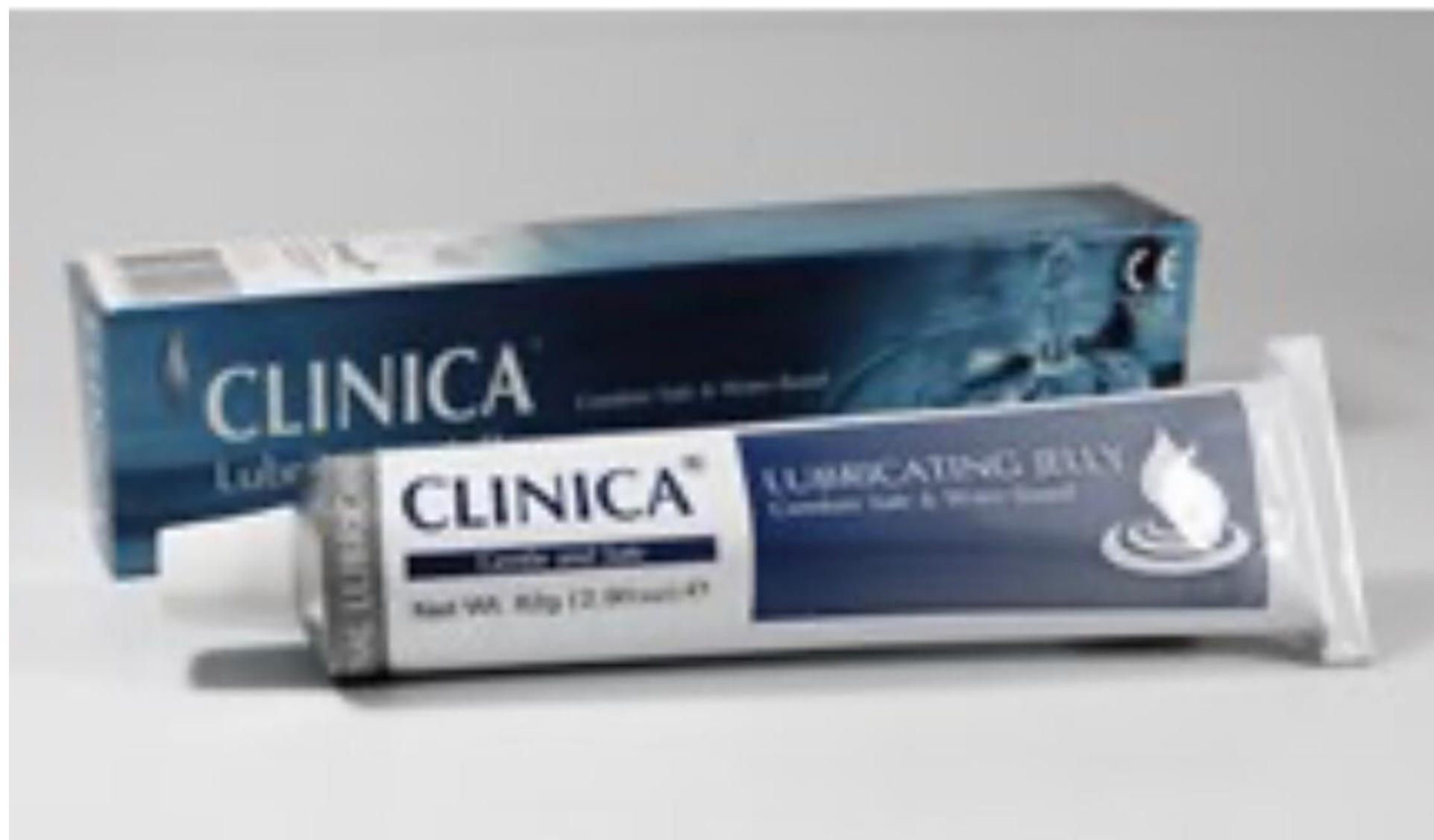

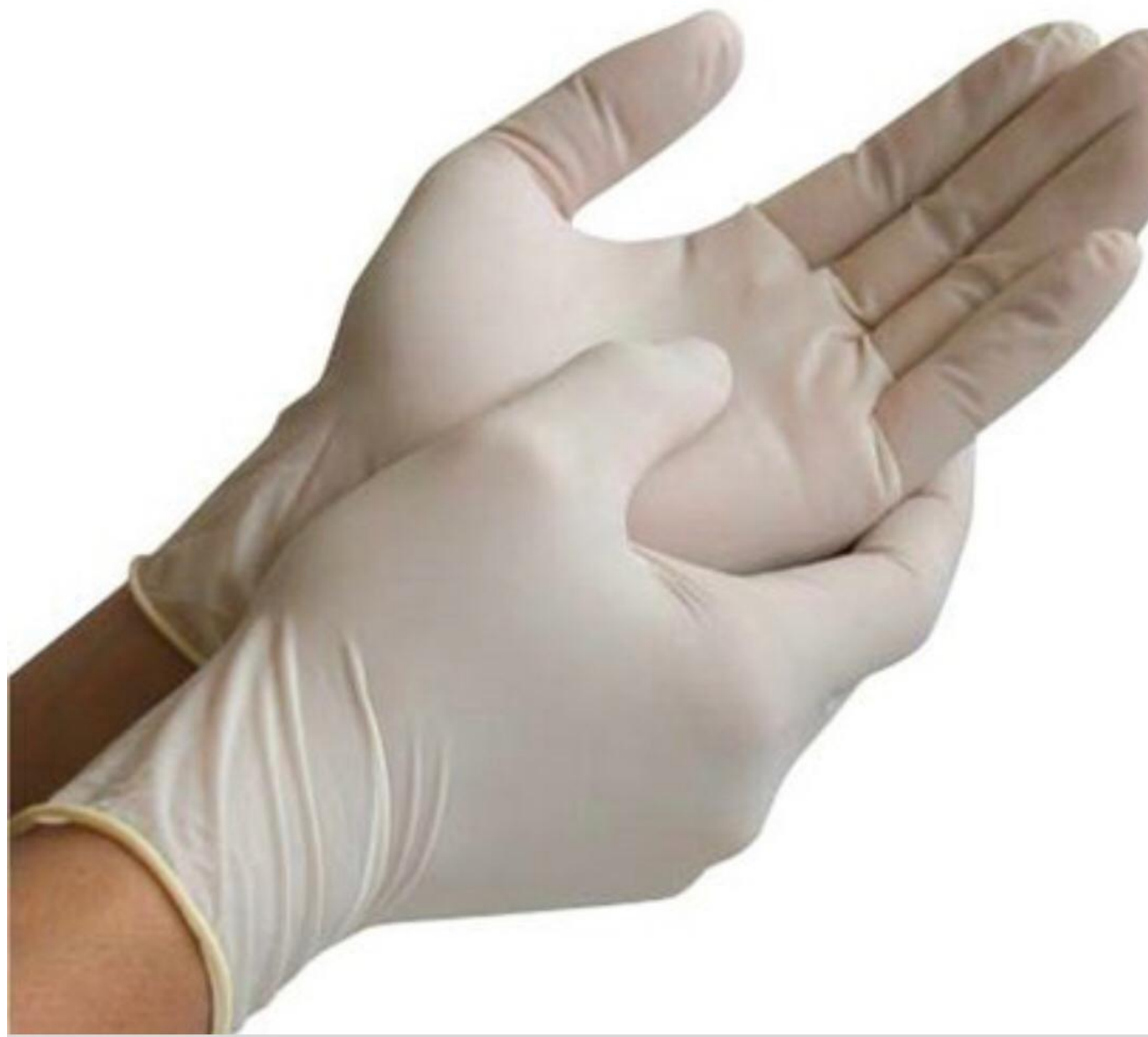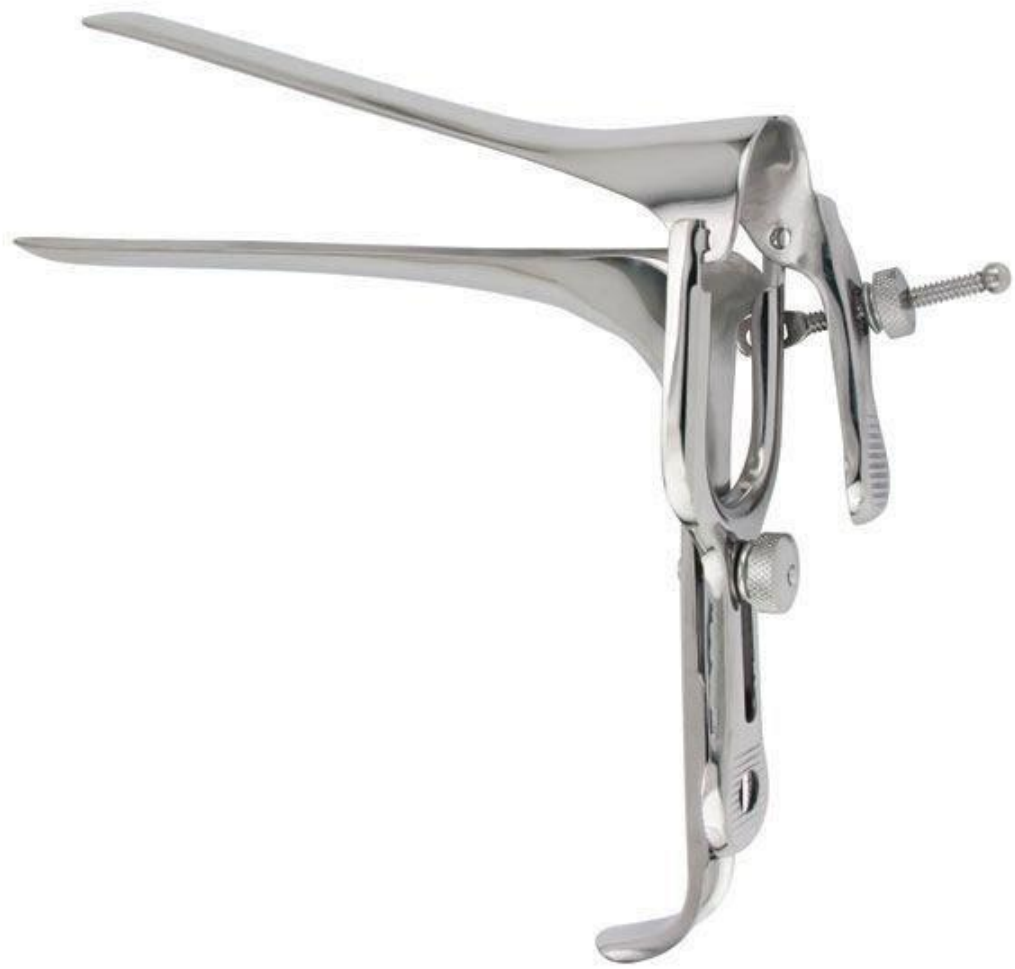**DO NOT
ENTER**

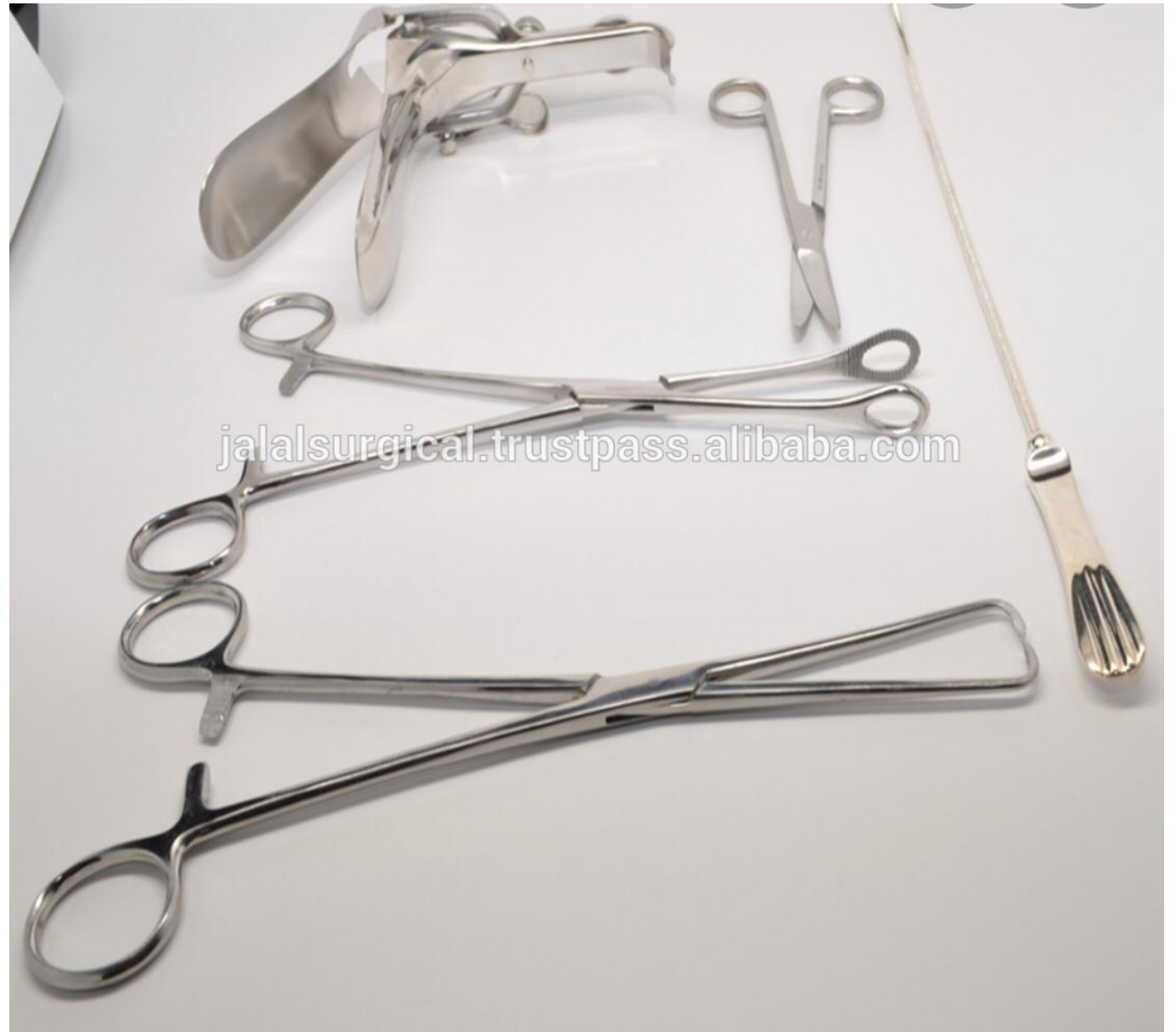

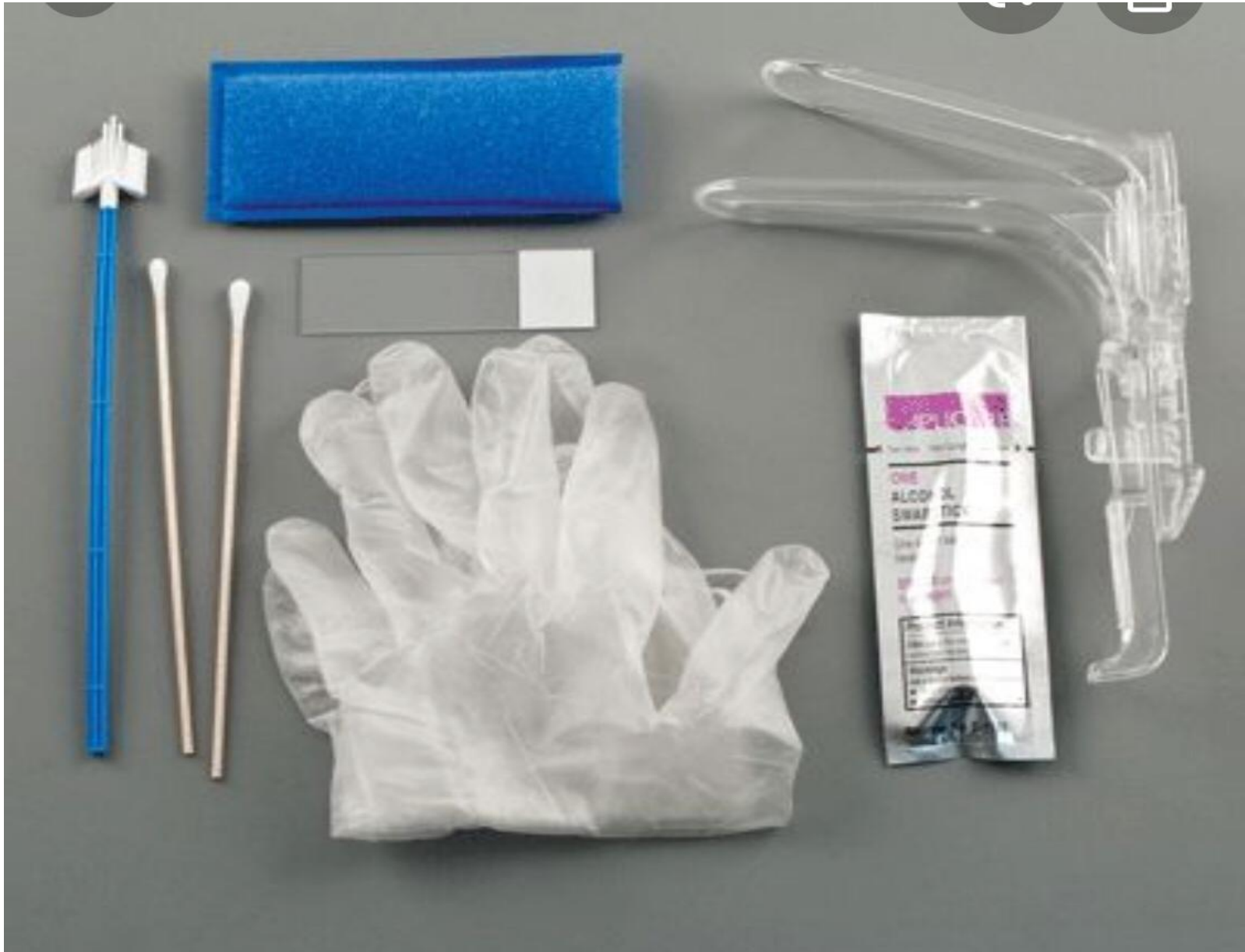CONSENT



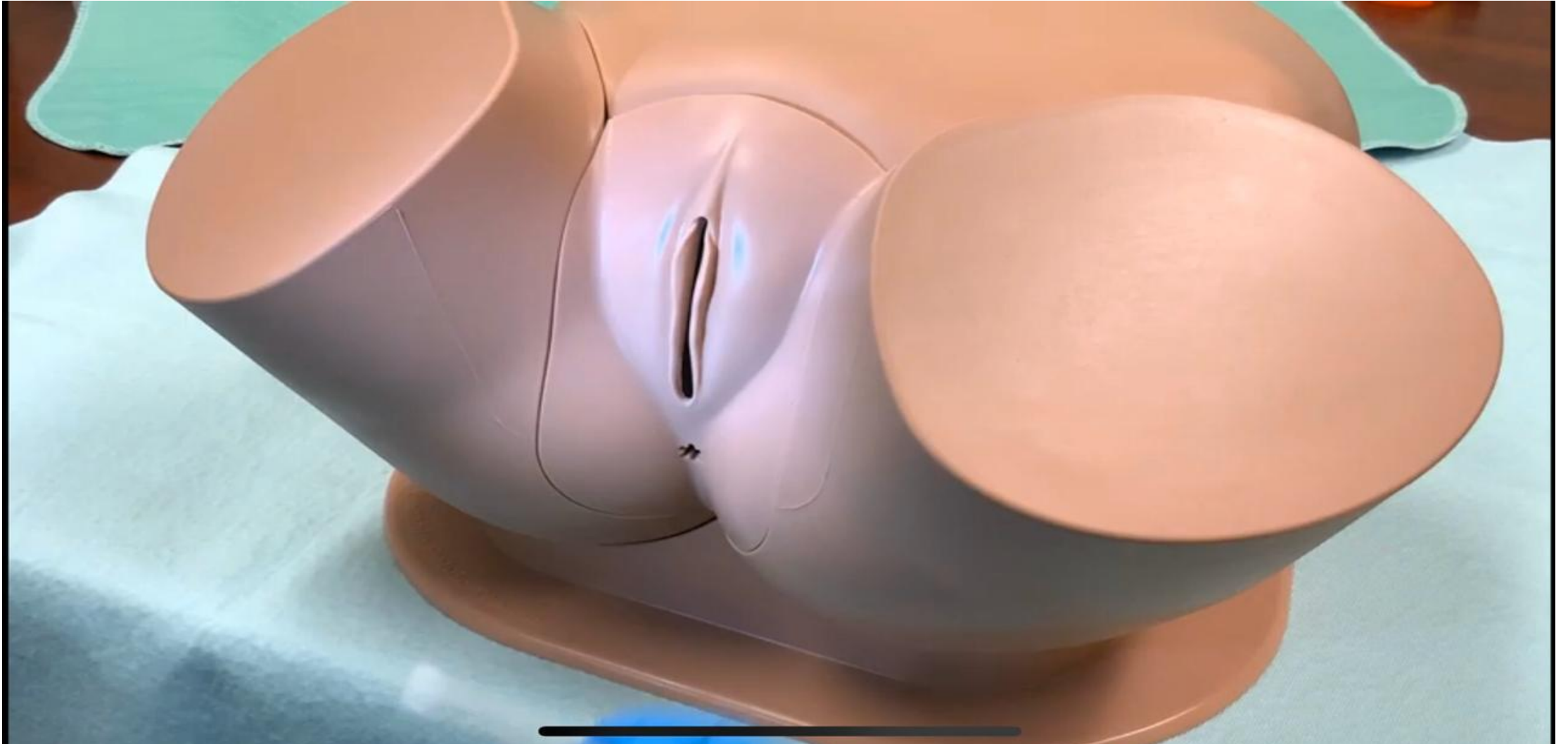








inspection



Gynecology examination

- https://youtu.be/Yb_LeorfFhg
- <https://youtu.be/v8k2jvkyc38>

- IUCD
- <https://youtu.be/NFAH03pZdac>
- <https://youtu.be/unMoohI0MEA>

- Pap smear
- <https://youtu.be/wTEpDaOvgkw>
- <https://youtu.be/eCjUBcWayYE>

Thank you