

# Pediatric Spinal Deformity

- In our vertebrae, we have two naturally occurring curves:

1. Lordosis (in cervical and lumbar regions)
2. Kyphosis (in thoracic and sacral regions)

Any exaggeration of the normal curvature can be defined as an abnormality.

## Scoliosis:

- It is a 3-dimensional deformity of the spine with lateral deviation more than 10 degrees, sagittal plane deformity (change of the normal kyphosis/lordosis ratios) and rotation of the vertebrae.
- Scoliosis is a medical condition in which a person's spine has a sideways curve. The curve is usually "S"- or "C"-shaped. In some the degree of curve is stable, while in others it increases over time. Mild scoliosis does not typically cause problems, while severe cases can interfere with breathing. Pain is present in up to 1/3 of patients.
- The commonest form of scoliosis is actually a triplanar deformity with lateral, anteroposterior and rotational components.
- Risk factors include other affected family members.
- Diagnosis is confirmed with plain X-rays.
- Scoliosis is typically classified as either structural in which the curve is fixed or functional in which the underlying spine is normal
- Signs and symptoms
  - Symptoms associated with scoliosis can include:
    - Pain in back, shoulders, and neck and buttock pain → 1/3 of pts
    - Respiratory and/or cardiac problems in severe cases
    - Constipation due to curvature causing "tightening" of stomach, intestines, etc.
    - Limited mobility secondary to pain or functional limitation in adults
    - Painful menstruation
  - The signs of scoliosis can include:
    - Uneven musculature on one side of the spine
    - Rib prominence or a prominent shoulder blade, caused by rotation of the rib cage in thoracic scoliosis
    - Uneven hips, arms or leg lengths
    - Slow nerve action
    - Heart and lung problems in severe cases
- More common in females
- It could be either:
  - Postural
  - Structural
    - Idiopathic (70-80%)
    - Congenital
    - Neuromuscular
    - Syndromic

## Postural Scoliosis

- One dimensional deformity, A secondary or compensatory deformity to a condition originating outside of the spine, such as:
- A short leg or a pelvic tilt due to contracture of the hip.
- Usually presented with thoracolumbar 'curvature'. When the patient bends forwards (upon flexion), the deformity disappears; this is typical of postural scoliosis.
- Short-leg scoliosis disappears when the patient sits (which cancel leg length asymmetry).
- This is a false deformity, and on x-ray: no rotation of pedicles, transverse processes or spinous processes.

## Structural Scoliosis

- Causes: (idiopathic, congenital, neuromuscular, syndromic)
- Idiopathic (infantile, juvenile, adolescent)
- It is a non-correctable 3D deformity.
- A True leg length discrepancy is present and gets worse upon flexion.
- Rotation of the spinous processes and the transverse processes.
- It is an asymptomatic disease, incidental finding, most common type is idiopathic adolescent scoliosis.
- If painful scoliosis present, think of underlying etiology like osteoid osteoma
- Scoliosis is a progressive disease.

### Adam's Forward Bending Test: → to see if functional vs structural

- The patient needs to bend forward, starting at the waist until the back comes in the horizontal plane, with the feet together, arms hanging and the knees in extension. The palms are held together. The examiner stands at the back of the patient and looks along the horizontal plane of the spine, searching for abnormalities of the spinal curve in addition to a prominent rib hump and asymmetry of the trunk. This test is important to look for the rotational component of the spine which typically accompanies the structural curves. Flexible curves don't usually have a rotational component.

### There are 3 types of structural scoliosis:

- **Congenital scoliosis**
  1. Failure of formation (wedge shaped /hemi vertebrae)
  2. Failure of segmentation (congenital bar/block vertebrae)
  3. Mixed
    - Progression depends on the type of the deformity affecting the vertebrae.
    - Defect is present at birth
    - Treatment is surgical.
- **Neuromuscular Scoliosis**
  - Also known as secondary scoliosis.
  - Occurs due to imbalance between sides of the spine as result of muscle spasticity.

- Probably caused by Poliomyelitis, cerebral palsy, neurofibromatosis.
- Treatment is surgical.
- **Idiopathic scoliosis**
  - According to age group
    - Infantile (0-3 years).
    - Juvenile (3-9 years).
    - Adolescent (10-18 years, most common type).

**New classification:**

- **Early onset** <10 years (includes idiopathic, congenital, syndromic, neuromuscular)
- **Late onset** >10 years → MC
- This classification is important with regards to treatment, as the usual treatment of the adolescent type in terms of spinal fusion can't be done in patients under 10 years of age as this will result in cessation of thoracic spine growth and consequently thoracic cage and lung growth which will lead to what's known as respiratory insufficiency syndrome ( restrictive lung disease)
- The most common type is **Adolescent idiopathic scoliosis:**
  - Usually, Deformity is the presenting symptom, it's mostly Painless, and age of presentation might give you a lead.
  - Test the patient on flexion→ Forward test will uncover it by the appearance of hump.
  - By history and physical exam exclude the congenital and neuromuscular types.
  - Rt thoracic curve is the MC idiopathic curve
    - High Rt shoulder
    - Rt proximal rib cage posteriorly
    - Left prominent breast anteriorly

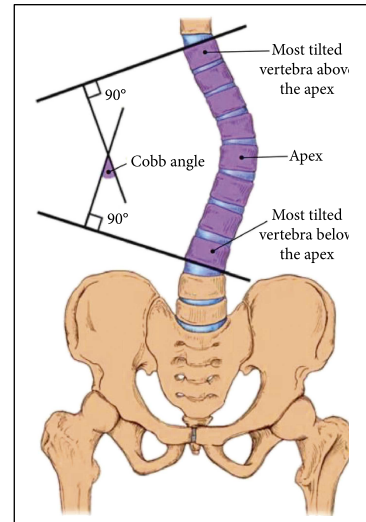
**Physical Examination:**

1. Asymmetry of shoulders, chest wall or breast in addition to a hump.
  2. Unequal gaps between trunk and arm.
  3. Leg length discrepancy.
  4. DO neurological exam.
- The person's gait is assessed, and there is an exam for signs of other abnormalities (e.g., spina bifida as evidenced by a dimple, hairy patch, lipoma, or hemangioma (known as skin manifestations of spinal dysraphism). A thorough neurological examination is also performed, the skin for café au lait spots, indicative of neurofibromatosis, the feet for cavovarus deformity, abdominal reflexes and muscle tone for spasticity. (sometimes, the only abnormal neurological physical sign is asymmetrical abdominal reflexes).

## Imaging:

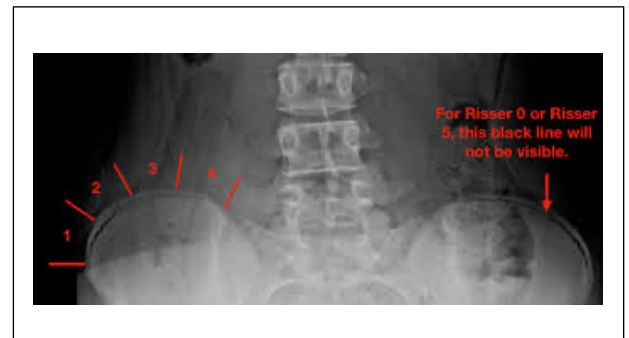
### Cobb's angle

- Full-length PA and lateral x-rays of the spine and iliac crests must be taken with the patient erect.
- The degree of curvature is measured by drawing lines on the x-ray at the upper border of the uppermost vertebrae of the curve and the lower border of the lowermost vertebrae of the curve; The angle between intersecting lines drawn perpendicular to the top of the top vertebrae and the bottom of the bottom vertebrae is the Cobb angle “the angle of curvature”
  - Mild → 10 - 30°
  - Moderate → 30 - 45°
  - Severe → >45°
- If 50-90 → needs surgery to prevent progression
- <50 → conservative
- Right thoracic curves are the commonest, the great majority in girls in adolescent idiopathic scoliosis. → the apex to the Rt side → to the opposite side of heart
- Left thoracic curves are so unusual that if seen they should be further investigated by MRI to exclude spinal tumors.
- Primary thoracic curves are usually convex to the right, lumbar curves to the left.



### SKELETAL MATURITY – RISSER'S SIGN

- Indirect measure of skeletal maturity, whereby the ossification stage of iliac apophysis is used to judge the ossification of spinal vertebra. On a scale of 5, it gives a measure of progression of ossification; the grade of 5 means that skeletal maturity is reached.
  - The curve of scoliosis often progresses most during the period of rapid skeletal growth and maturation.
  - The iliac apophysis start ossifying shortly after puberty.
  - Ossification extends medially and, once the iliac crests are completely ossified, further progression of the scoliosis is minimal (Riser's sign).
  - This stage of development usually coincides with fusion of the vertebral ring apophysis. ‘Skeletal age’ may also be estimated from x-rays of the wrist and hand.
1. Grade 1 → when the ilium (bone) is calcified at a level of 25%; it corresponds to prepuberty or early puberty.
  2. Grade 2 → when the ilium (bone) is calcified at a level of 50%; it corresponds to the stage before or during growth spurt.
  3. Grade 3 → when the ilium (bone) is calcified at a level of 75%; it corresponds to the slowing of growth.
  4. Grade 4 → when the ilium (bone) is calcified at a level of 100%; it corresponds to an almost cessation of growth.
  5. Grade 5 → when the ilium (bone) is calcified at a level of 100 % and the iliac apophysis is fused to iliac crest; it corresponds to the end of growth.



- SPECIAL IMAGING: CT and MRI may be necessary to define a vertebral abnormality or cord compression.

### **Prognosis:**

- CVS /RS compromise in severe cases in pts <5 yrs as it affects lung structural maturity
- The risk of progression depends on the following parameters:
  1. Growth potential of the patient.
  2. Magnitude of curve
  3. Type of curve
  4. Sex of the patient
- In adults: Once growth has stopped, risk of progression is minimal or null in patients with thoracic scoliosis less than 50°, lumbar/thoracolumbar, < 30°.
- Adult idiopathic scoliosis with curves greater†than†50°†may progress slowly at a rate of 0.5–1°/year.
- Progression of scoliosis can involve an aesthetic problem and lead to functional problems. Cardiac and Respiratory disorders may develop in large curves greater than 80°.
- Nonetheless, the mortality rates and vital prognosis in individuals with scoliosis are comparable to those of the general population.
- Reliable predictors of progression are: (1) a very young age; (2) marked curvature; (3) an incomplete Risser sign at presentation. In prepubertal children, rapid progression is liable to occur during the growth spurt.
- **Reasons to treat:**
  - Cosmetic mainly.
  - *Progression (>50 degree) as a rate of 0.5-1 /year.*
  - Cardiac and respiratory complications.
  - Disc herniation.
  - Degenerative changes.
- Patients with severe chest deformities should undergo pulmonary function tests. A marked reduction in vital capacity is associated with diminished life expectancy and carries obvious risks for surgery.

### **Treatment principles:**

1. Patients with a curve <20 degree regardless of age observe.
2. Patients with a curve >50 degree may progress more →surgery is needed.
3. Those between 20-50→ depends on maturation; if skeletally mature and risk of progression is low observe for a while to make sure it won't exceed the 50 degrees mark. /if skeletally immature then need bracing to control the curve during this period of rapid growth.

"The 3O's ":

- (1) observation: 4-6 monthly visits.
- (2) Orthotics: braces, prevents progression and does not correct deformity.

### (3) Operative intervention.

When to choose each of these treatments is a complicated matter.

- Complications of surgery
  - Neurological compromise: less than 1%.
  - Spinal decompensation
  - Pseudarthrosis: incomplete fusion occurs in about 2% of cases and may require further operation and grafting.
  - Implant failure: hooks may cut out and rods may break. If this is associated with a symptomatic pseudarthrosis, revision surgery will be needed.

## Kyphosis

- Kyphosis (a hump) is an abnormally excessive convex kyphotic curvature (flexible or fixed) of the spine as it occurs in the thoracic and sacral regions. (Abnormal inward concave lordotic curving of the cervical and lumbar regions of the spine is called lordosis.)
- It can result from degenerative diseases such as arthritis; developmental problems, most commonly Scheuermann's disease; osteoporosis with compression fractures of the vertebra; multiple myeloma or trauma. A normal thoracic spine extends from the 1st to the 12th vertebra and should have a slight kyphotic angle, ranging from 20° to 45°. When the "roundness" of the upper spine increases past 45° it is called kyphosis or "hyper-kyphosis".
- Scheuermann's kyphosis is the most classic form of hyper-kyphosis and is the result of wedged vertebrae that develop during adolescence. The cause is not currently known, and the condition appears to be multifactorial and is seen more frequently in males than females.
- While most cases of kyphosis are mild and only require routine monitoring, serious cases can be debilitating. High degrees of kyphosis can cause severe pain and discomfort, breathing and digestion difficulties, cardiovascular irregularities, neurological compromise and, in the more severe cases, significantly shortened life spans. These types of high-end curves typically do not respond well to conservative treatment and almost always warrant spinal fusion surgery, which can restore the body's natural degree of curvature. Kyphosis; Refers to the normal apical-dorsal sagittal contour of the thoracic and sacral spine. As a pathologic entity, kyphosis is an accentuation of this normal curvature.
- It's a progressive spinal disorder that can affect children or adults, more common in males. Causes a deformity described as "hunchback", causing bending & a loss of height.
- Commonly found in thoracic or thora-columbar spine.
- Up to 20-45 can be considered normal.
- Vertebral anomalies leading to kyphosis may be due to failure of formation (Type I, commonest (and the worst) type), failure of segmentation (Type II) or a combination of these.
- Threshold for surgery of Kyphosis is high because of neurological injury risk.

- A kyphos (or gibbus) is a sharp posterior angulation due to localized collapse or wedging of one or more vertebrae. This may be the result of a congenital anomaly, a fracture (sometimes pathological) or spinal TB.

Kyphosis is divided into:

### 1. Postural Kyphosis:

- Common “round back” or “Drooping shoulders”
- Seen in tall and shy people.
- Increased but flexible curvature of the spine.
- Occurs mostly in adolescents, no associated pain.

### 2. Structural Kyphosis:

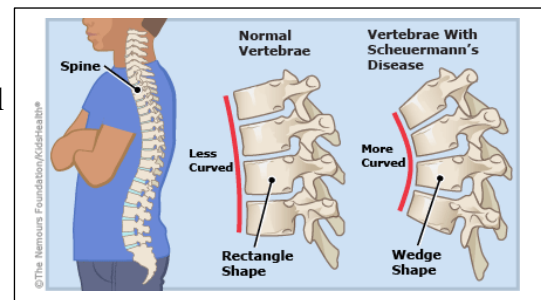
#### A. Sweeping or generalized, Involving the whole spine

Classified according to age

- Old age: most common cause is osteoporosis.
- Young: most common cause is ankylosing spondylitis.

### Scheuermann's kyphosis:

- Scheuermann's disease is a self-limiting skeletal disorder of childhood. Scheuermann's disease describes a condition where the vertebrae grow unevenly with respect to the sagittal plane; that is, the posterior angle is often greater than the anterior. This uneven growth results in the signature "wedging" shape of the vertebrae, causing kyphosis.
- blood supply of anterior spinal artery < posterior spinal artery. So, vertebrae become wedge in shape causing Kyphosis
- Chief complaint of these patient's easy fatigability due to tension on muscle resulted from deformity.
- It's a 'developmental' disorder in which there is abnormal ossification (and possibly some fragmentation) of the ring epiphyses that appear on the upper and lower surfaces of each vertebral body in the growing spine. Sometimes there may also be small central herniation of disc material into the vertebral body; these are called Schmorl's nodes.
- Examination reveals a smooth but well-marked thoracic kyphosis (or 'hyper-kyphosis') which does not improve with changes in posture.
- X-ray features are typical: in the lateral views one can see patchiness or irregularity of the vertebral endplates and, in some cases, Schmorl's nodes at several intervertebral levels.
- Later, the vertebral bodies become noticeably wedge shaped.
- It's is a type of generalized kyphosis.
- A rigid thoracic hyper-kyphosis defined by > 45 degrees.
- Caused by anterior wedging of >5 degrees across three consecutive vertebrae.



- Differentiated from postural kyphosis by rigidity of curve, and by being painful.
- On x-ray Anterior height of vertebrae < posterior height of vertebrae in multiple vertebrae
- Presentation:
  - Between 13-16 yr-old, male > female.
  - Painful, progressive deformity, in addition to Muscle tension caused by deformity causing easy fatigability

**B. Angular or localized:** Any local pathology of the spine.

- Congenital deformity
  - Fractures
  - Infections
  - Tumor
  - TB
- Symptoms: Mild back pain, Fatigue, Appearance of round back, Breathing difficulties (in severe cases)
  - Appearance:
    - Difference in shoulder height.
    - Head bends forward compared to the rest of the body.
    - When bending forward, the height of the upper back appears higher than normal.
  - Diagnosis:
    - Hx + Physical examination. + Natal Hx.+ Developmental milestones.
  - Physical Examination:
    - Observation → look (from the side, may reveal round-back, any associated scoliosis will be observed).
    - Palpation → feel (Determines spinal abnormalities; often the paraspinal musculature is tender). When Scheuermann's Disease is present, the hamstring muscles may be tight.
    - Range of Motion → move (Deformity is palpated during range of motion to assess flexibility or rigidity of the curve).
  - Investigations:
 

X-rays: AP and lateral spine.

Findings:

    - Anterior wedging
    - Disc narrowing
    - Endplate irregularities
    - Schmorl's nodes
    - Scoliosis
    - Compensatory hyperlordosis

MRI: To rule out associated abnormalities of spinal curve and nerves.
  - Rx:
    - >70 degrees do surgery.
    - Physiotherapy



### **Schmorl's nodes:**

- Protrusions of cartilage of the intervertebral disc through the vertebral body endplate and into the adjacent vertebrae. The protrusions may contact the marrow of the vertebrae leading to inflammation.

### **General notes:**

- Lordosis: is an unstable curvature of the spine, that's why any problem in the spine occurs more frequently in lordotic parts (cervical, lumbar)
- Why kyphosis, and lordosis are important to us? To maintain center of gravity.
- Cervical lordosis developed when the infant start to carry his head and control it using his cervical spine and muscles, about the 1st 3 months of age.
- Lumbar lordosis developed when the infant start using his lower limbs and pelvis and carry his trunk (sitting and standing)
- Usually the lordotic areas of the spine are more moveable; this is the case in cervical and lumbar spines where the movement is present more than that of the normally kyphotic parts of thoracic and sacral.
- Primary position of the spine is kyphosis, and secondary lordosis developed after birth. Kyphosis is stable and prevents rotational movement on the spine, when hypokyphosis takes place "idiopathic" the stability decreases, and such rotational movement became easier to happen. And any movement will have by physics translation, based on the biomechanical coupling theory: rotation with translation equal to bending.
- Pain is not idiopathic so think of other pathology.
- The respiratory system by the age of 5 will be almost developed, if the pathology occurs. Before that it would affect significantly the pulmonary functions. But if the onset is after that level it will be of less or no effect.
- X-rays are of diagnostic value because usually the apparent contour of the body is normal by compensation.
- We classify the scoliosis by the position of the spine involved, and by the apex of primary scoliotic area, as right cervical or left lumbar.
- But how to know if scoliosis is primary or compensatory? by lateral flexion, the compensating scoliosis will be corrected. This is only before a permanent deformity developed as fibrosis and fusion take place by 8 months. Or what called double curve, and by this level you can't judge if it primary double curve or secondary to usual scoliosis
- 60% of back flexion is from the hip region.