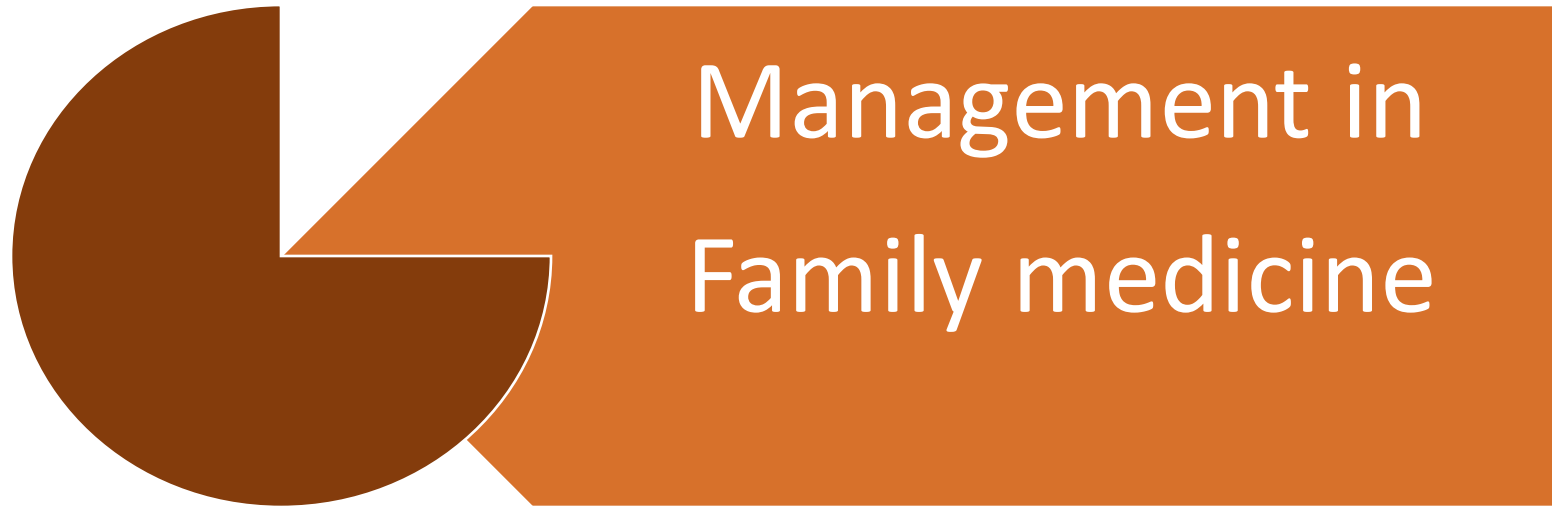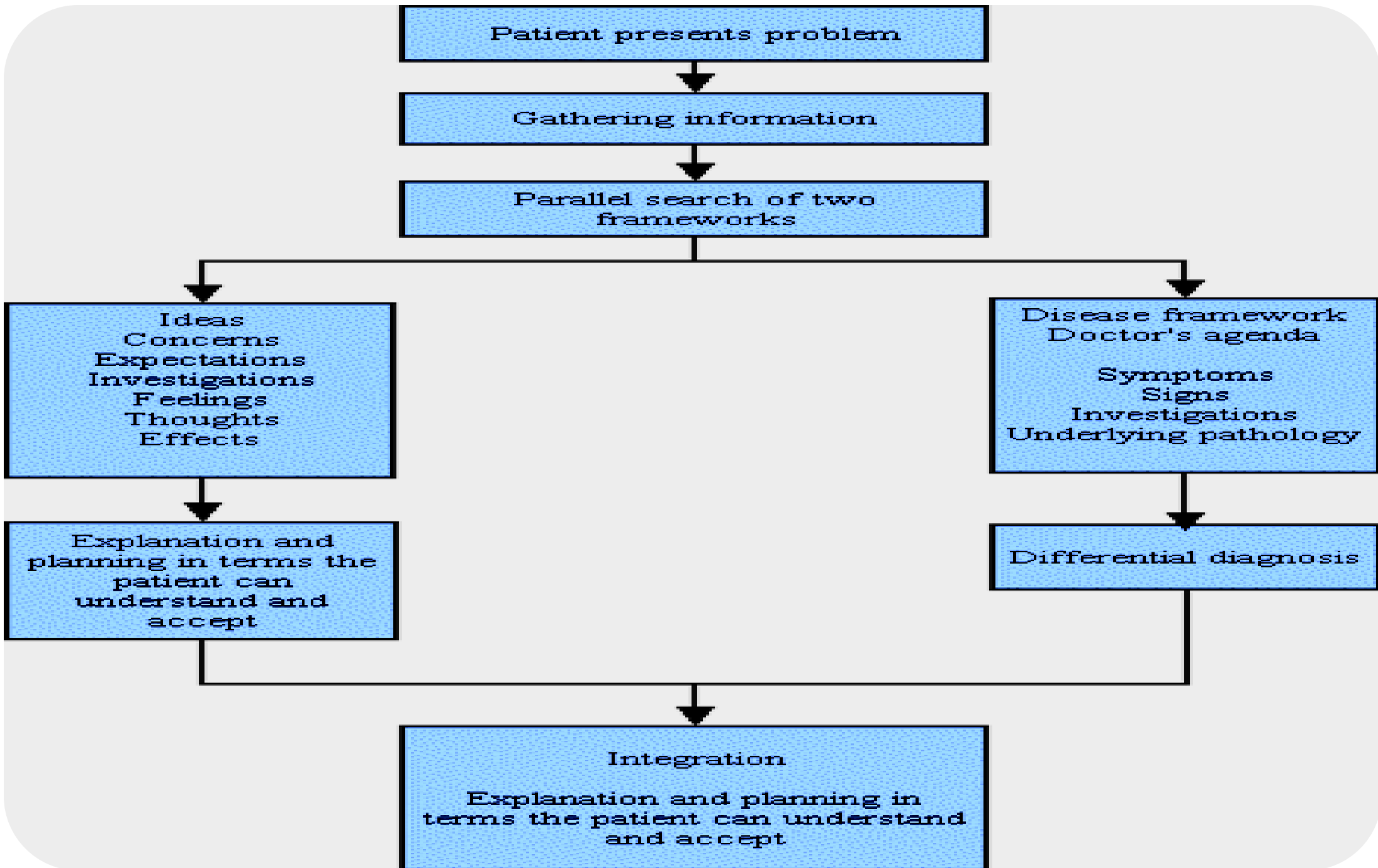




Management in
Family medicine

Dr. Farihan Barghouti



A 15-year-old girl has a history of acute difficulty breathing when playing basketball.

Symptoms and signs

- Her symptoms include inspiratory wheezing/stridor
- increased respiratory rate
- throat tightness, and chest discomfort.
- Premedication with adequate doses of albuterol has no effect.

Differential diagnosis

What is the most likely diagnosis?

A-Exercise-induced asthma.

B-Gastroesophageal reflux disease.

C-Musculoskeletal chest pain.

D-Hyperventilation.

E-Vocal cord dysfunction.

Differential Diagnosis of Vocal Cord Dysfunction

Anaphylaxis

Angioedema

Asthma

Epiglottitis

Hypoparathyroidism

Laryngomalacia (in adults)

Laryngotracheobronchitis (croup)

Presence of foreign body

Tracheal stenosis

Vocal cord paralysis

Vocal cord tumors or polyps

The correct answer is "E."

Why ??

In this patient, a β_2 -agonist was ineffective, even though she displays symptoms with exertion. This argues against answer "A." The distinction between VCD and asthma may be less clear in other patients, since the two disorders sometimes coexist.

The clinical history does not support the diagnoses of gastroesophageal reflux disease, musculoskeletal chest pain, or hyperventilation

Explanation

Vocal cord dysfunction (VCD)

Is one of the most common
asthma mimics.

Symptoms

Patients with VCD
present with

- hoarseness, coughing, dyspnea, and loud **inspiratory wheezing/stridor**, along with other symptoms mentioned above.

Precipitating Factors

EXERCISE

PSYCHOLOGICAL CONDITION Studies have reported associations between vocal cord dysfunction and multiple psychological conditions, including posttraumatic stress disorder, anxiety, depression, and panic attack.

IRRITANTS Exposure to environmental and occupational irritants has been found to precipitate respiratory symptoms consistent with vocal cord dysfunction.

RHINOSINUSITIS Postnasal drip associated with rhinosinusitis has been linked to airway hyperresponsiveness.- A high prevalence of rhinosinusitis in patients with vocal cord dysfunction and case reports of resolution of vocal cord dysfunction symptoms with treatment suggest that rhinosinusitis may play a role in some patients.

GASTROESOPHOGEAL REFLUX DISEASE

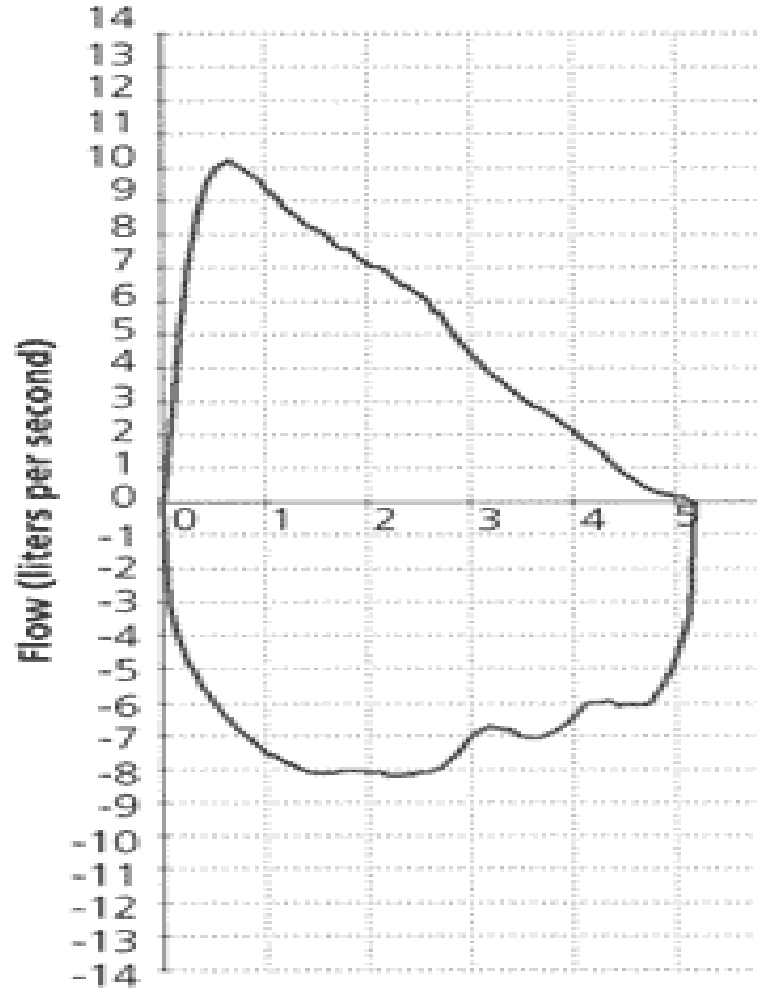
MEDICATION USE Neuroleptic drugs, specifically phenothiazines,

Investigation

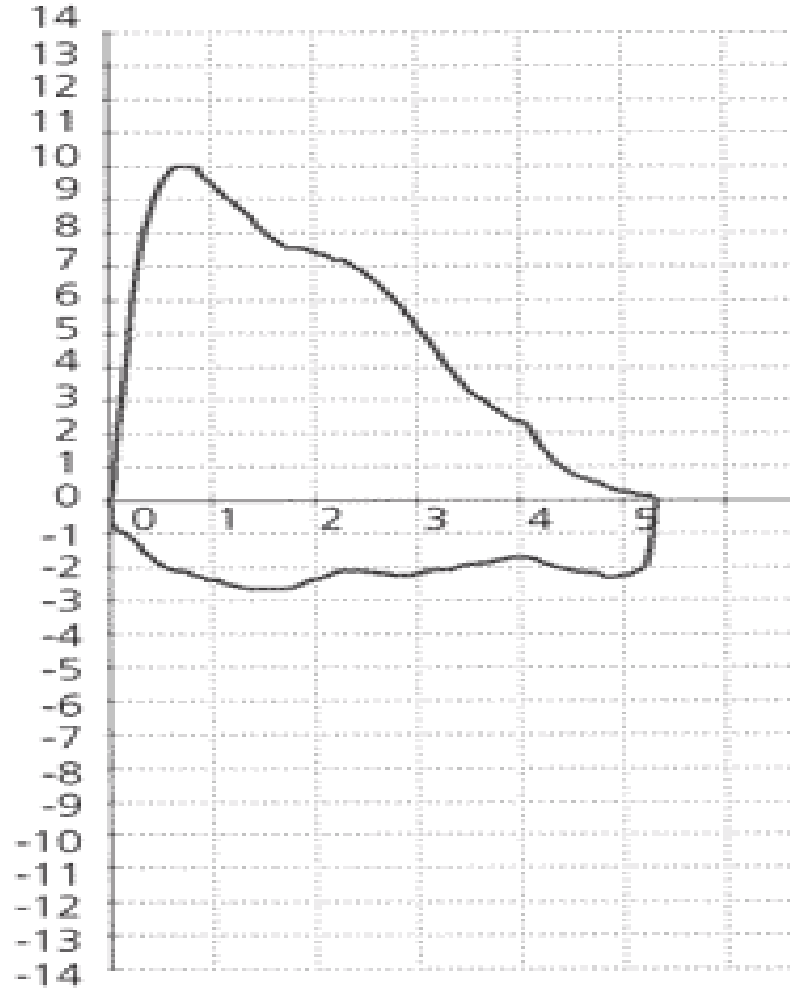
Pulmonary function testing-- indicates airway obstruction due to an extrathoracic component. It appears that paradoxical inspiratory vocal cord adduction causes airflow restriction at the level of the larynx, resulting in a flattened inspiratory loop on flow–volume diagram

The second test is flexible laryngoscopy

Normal



VCD



Flow-volume loop. (Left) Normal expiratory and inspiratory loop. (Right) Normal expiratory loop with flattening of the inspiratory loop, consistent with vocal cord dysfunction.

VCD presents a diagnostic challenge, and often leads to unnecessary treatment of asthma.

Short-term

Reassure patient

Instruct patient in breathing behaviors, including panting (having the patient breathe rapidly and shallowly), diaphragmatic breathing, breathing through the nose or a straw, pursed-lip breathing, and exhaling with a hissing sound

Consider a trial of helium and oxygen (heliox) in patients with persistent or severe vocal cord dysfunction

Long-term

Avoid known triggers, such as smoke, airborne irritants, or certain medications

Treat underlying conditions, including anxiety, depression, gastroesophageal reflux disease, and rhinosinusitis

Consider a trial of inhaled ipratropium (Atrovent) in patients with exercise-induced symptoms

Referral for speech therapy is indicated in patients with unresolved symptoms

Long-term tracheostomy may be appropriate in severe, resistant cases

Short- and Long-term Management of
Vocal Cord Dysfunction

Treatment

The main treatment for VCD is speech therapy technique

Speech therapy techniques are usually taught by a speech therapist or psychologist who is trained and experienced in treating VCD.