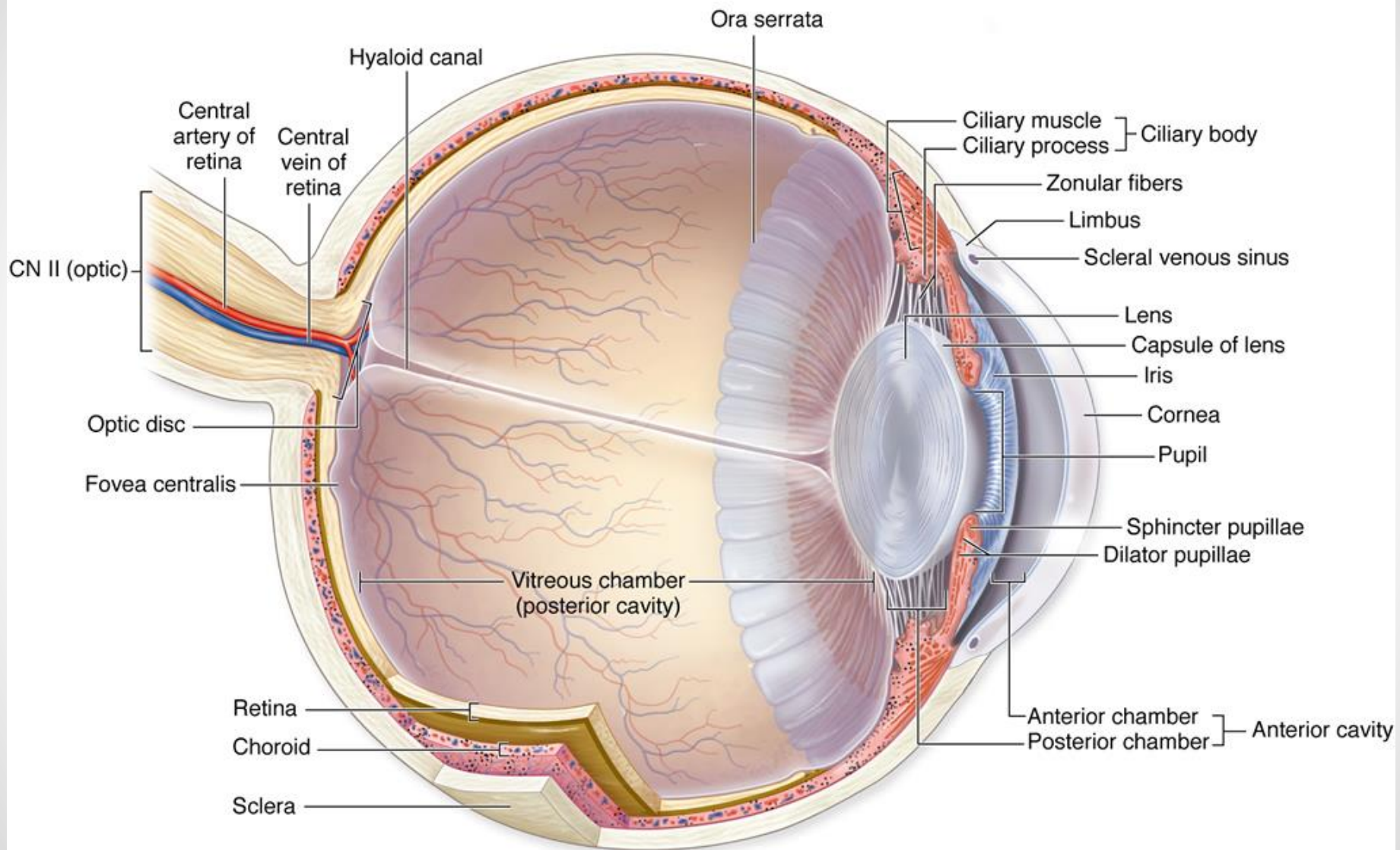


Lens and Cataract

DR MUTASEM ALRABIE
CONSULTANT OPHTHALMOLOGY
JUH

Lens

...



Lens

- Is a transparent biconvex structure immediately behind the iris
- It Focuses light on the retina
- Derived from ectoderm
- It is avascular
- It is highly elastic; but it hardens with age

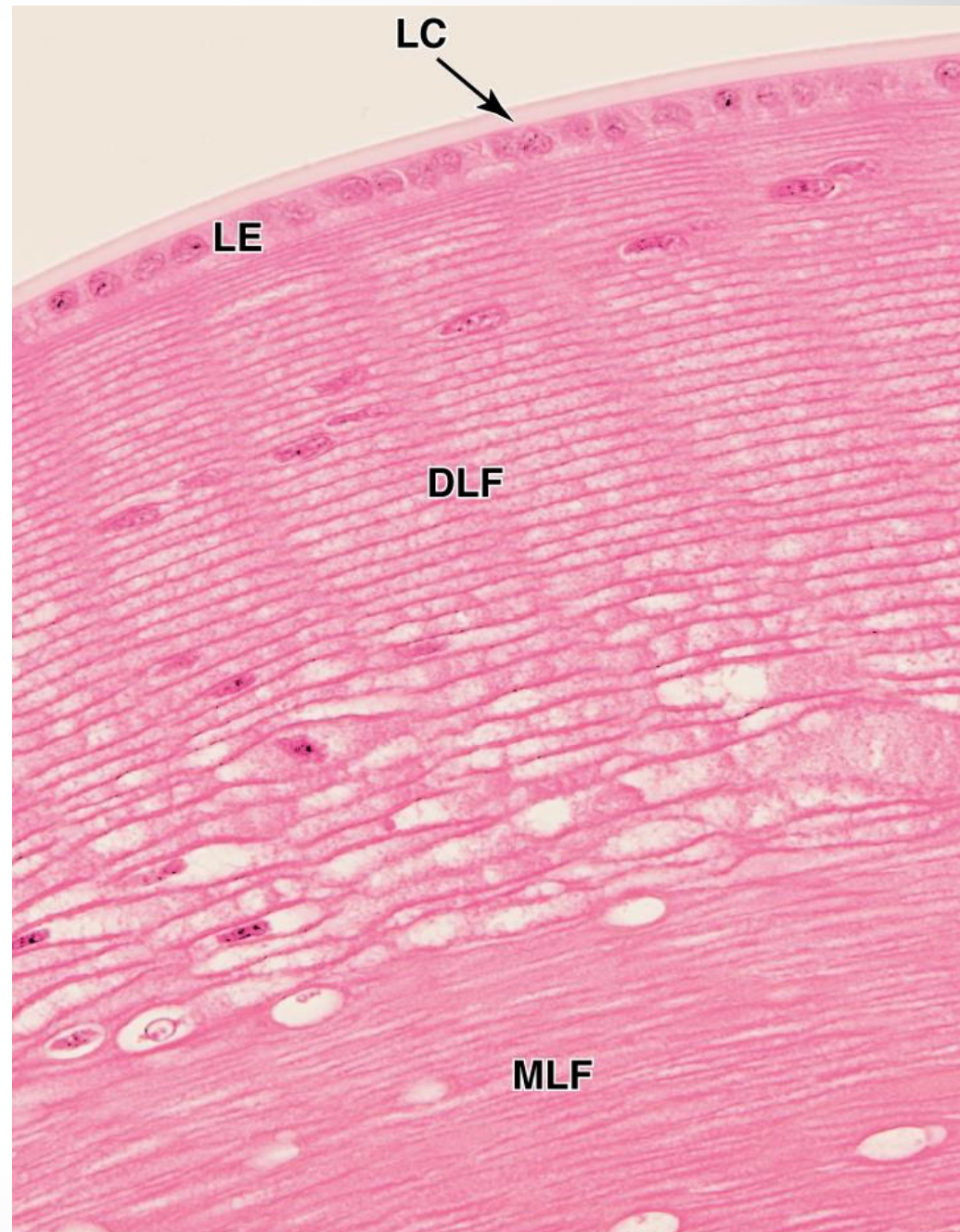Histology of the Lens

Lens Capsule (LC)

Lens Epithelium (LE)

Differentiating Lens Fibers (DLF)

Mature Lens Fibers (MLF)



Histology of the Lens

- The lens capsule is a thick, homogenous external lamina formed by proteoglycans & collagen IV for protection of underlying structures and attachment of zonules.
- The lens epithelium is a single layer of cuboid cells, present only on the anterior surface of the lens.
- Near the equator, the cells divide to provide new cells that differentiate as lens fibers.

Histology of the Lens


- The lens fibers align parallel to the epithelium.
- Differentiating lens fibers: still have their nuclei, but are greatly elongated, and their cytoplasm is filled with proteins called crystallins.
- The mature lens fibers: lost their nuclei and became densely packed to produce a unique transparent structure.

Cataract

...


Definition

- It is the opacification of the lens of the eye
- **Opacification:**
The process of becoming cloudy or opaque



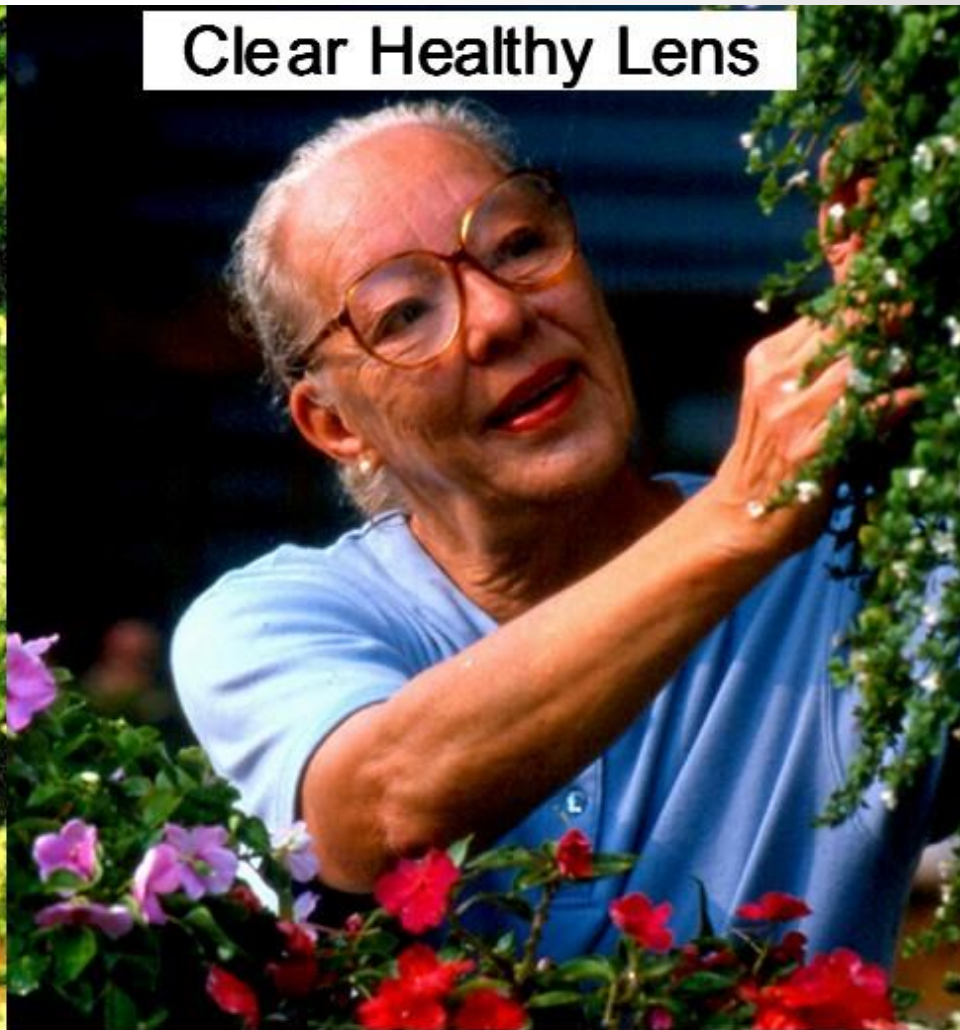
- **Cataract is the most common cause of treatable blindness (visual loss) in the world**

Cataract



The image is blurred. Colors are distorted. Glare is present.

Clear Healthy Lens



The image is clear. Colors are vibrant.



*Normal
vision*

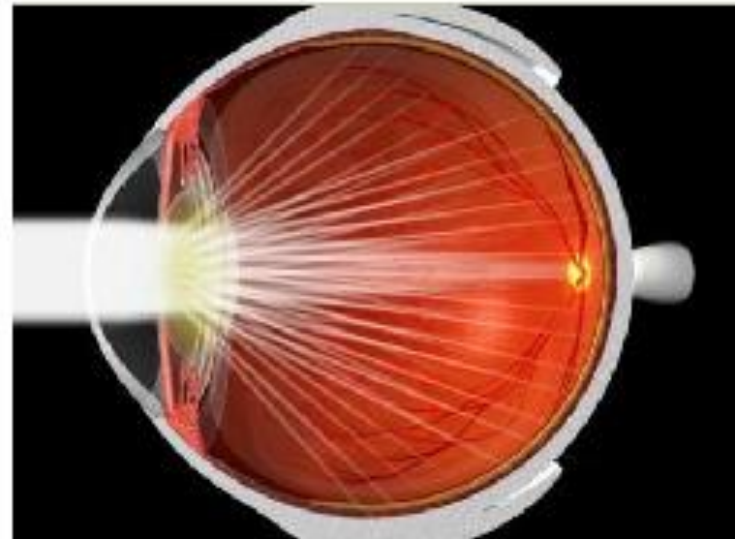
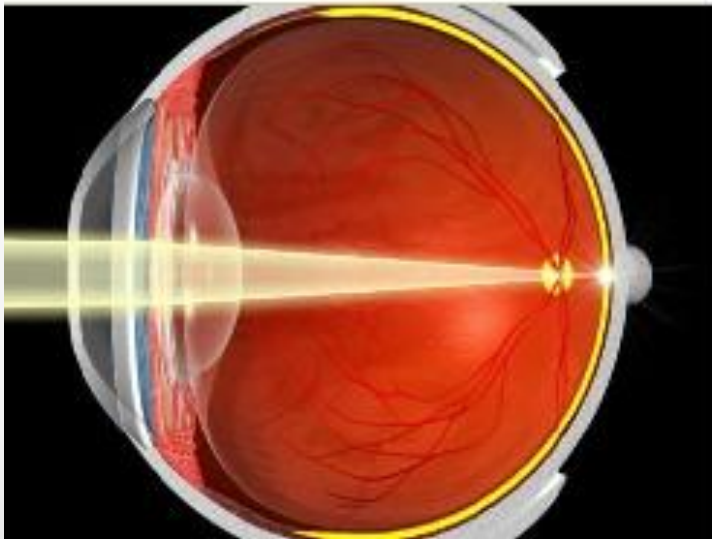


*Vision through
early cataract*



*Vision through
advanced cataract*

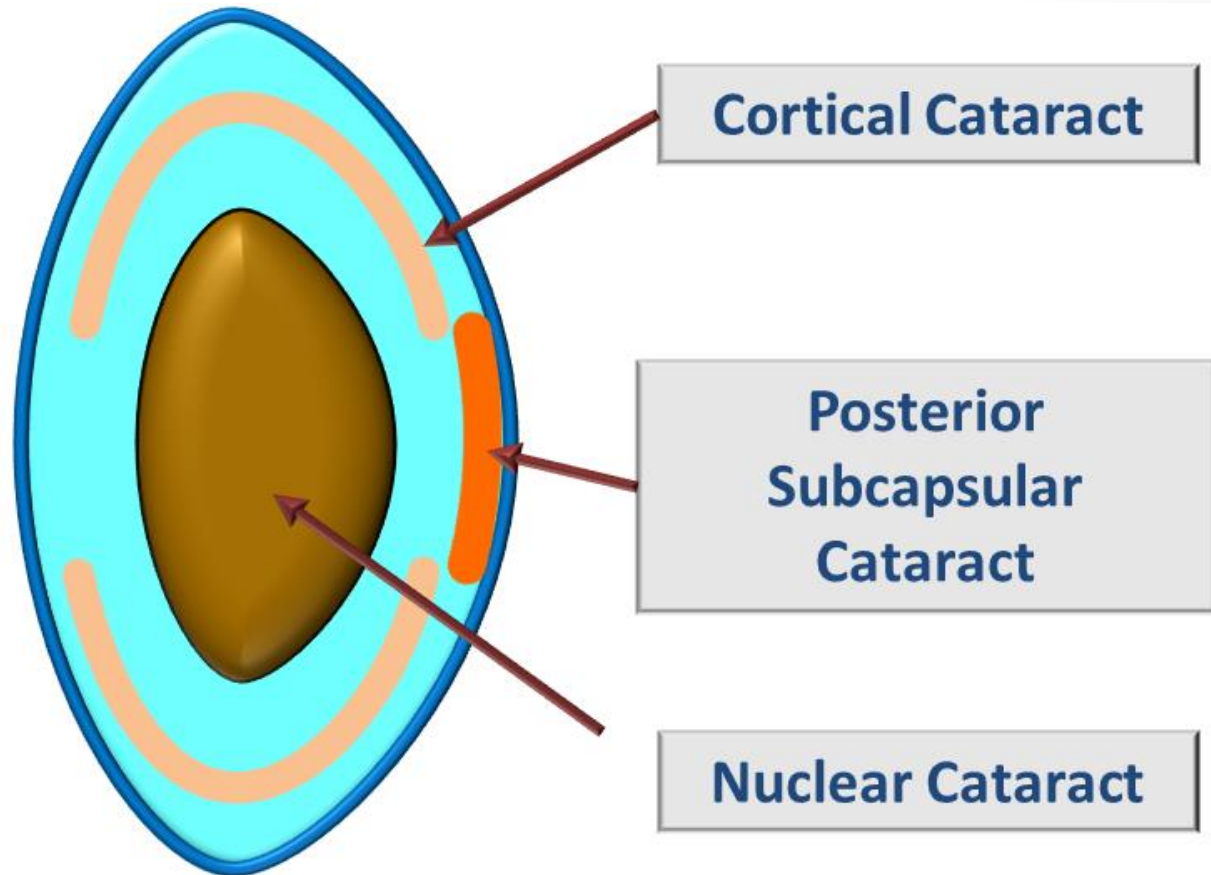
How this happen?



How cataract vision occurs?

- A healthy, clear lens allows a sharp image to fall on every part of the retina allowing a crisp, clear image to be seen.
- A cloudy lens scatters light, causing a hazy image to be seen.

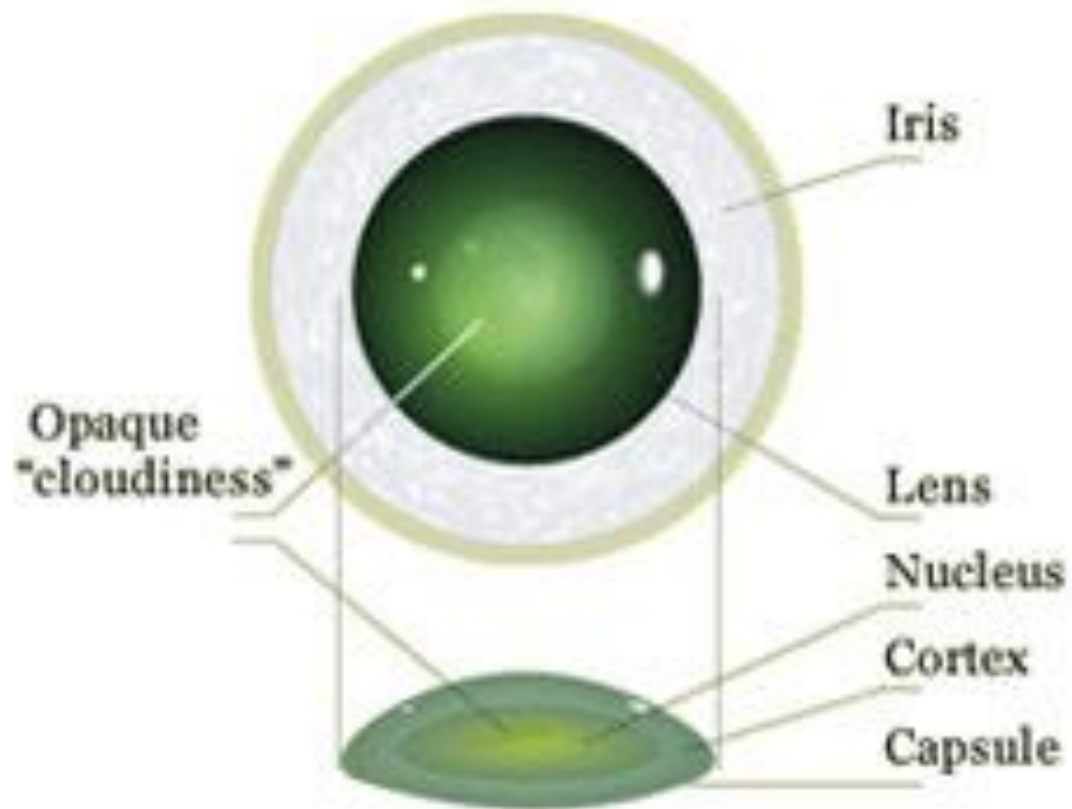
Types of cataract

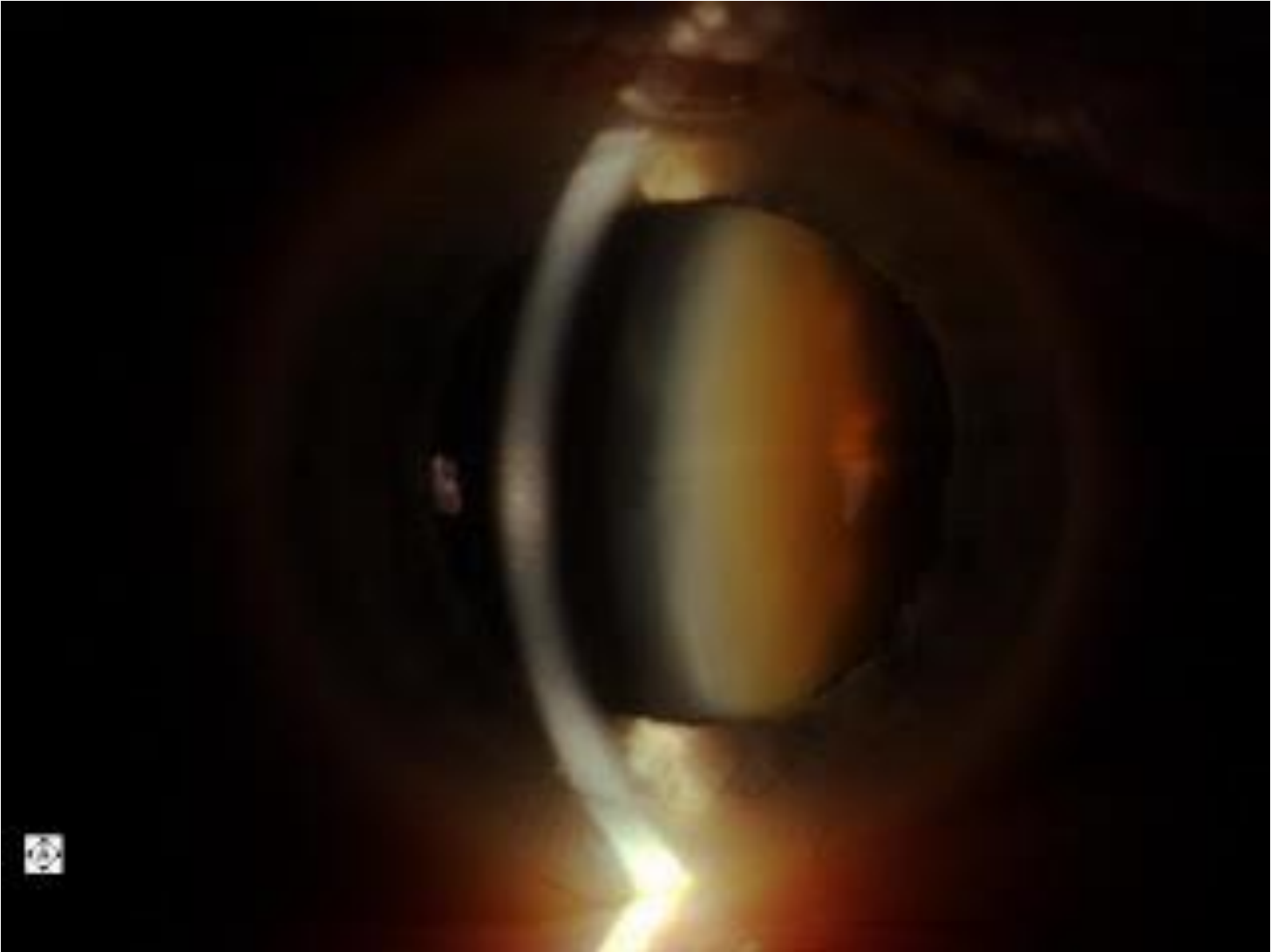


Types of cataract

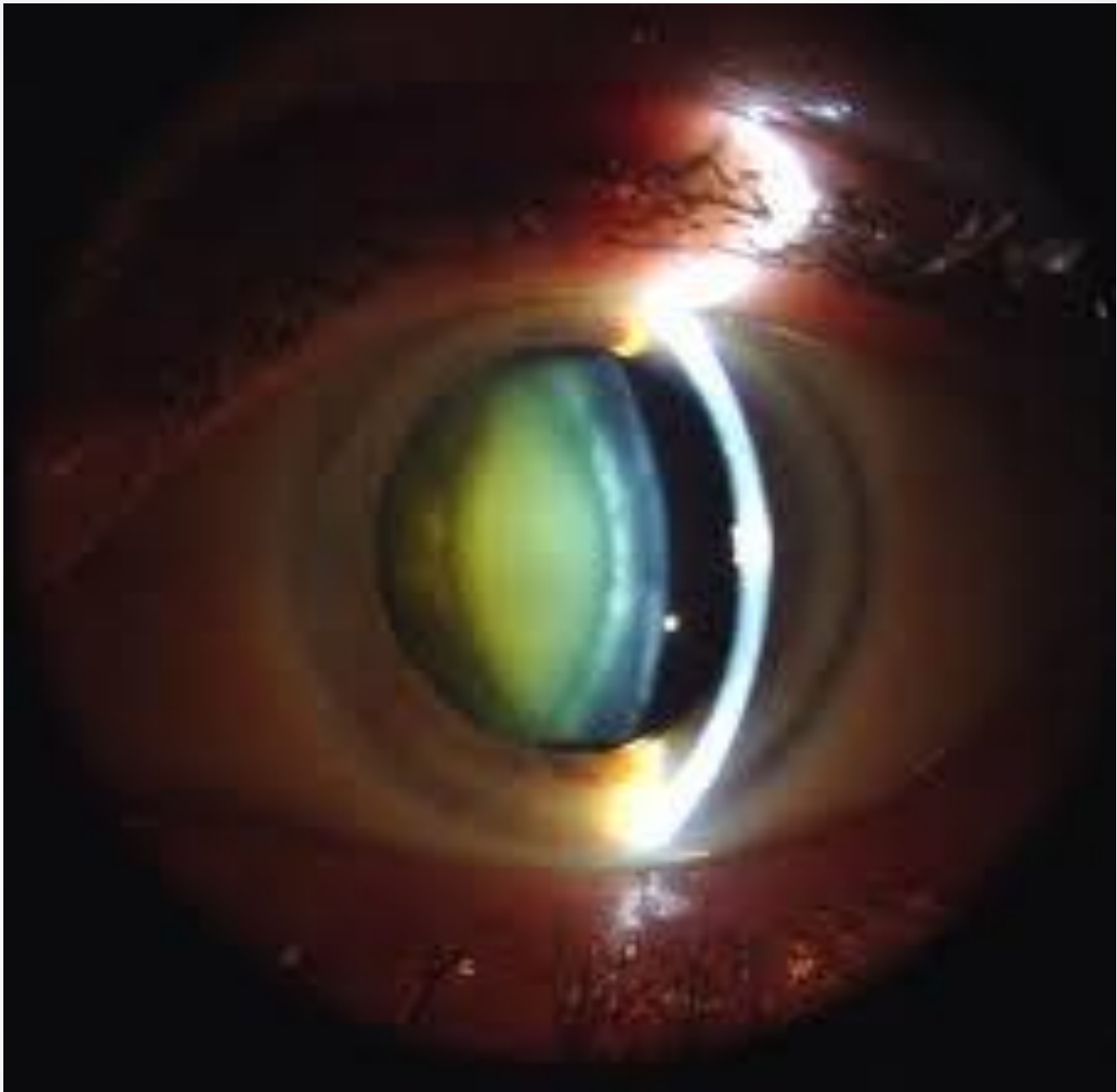
- **Nuclear:**
 - is the most common type of cataract
 - involves the central or 'nuclear' part of the lens.
 - Over time, the nucleus becomes hard or 'sclerotic' due to condensation of lens nucleus and deposition of brown pigment within the lens.
 - presents with a shift to nearsightedness and causes problems with distance vision while reading is less affected.

Nuclear Cataract





Nuclear cataract

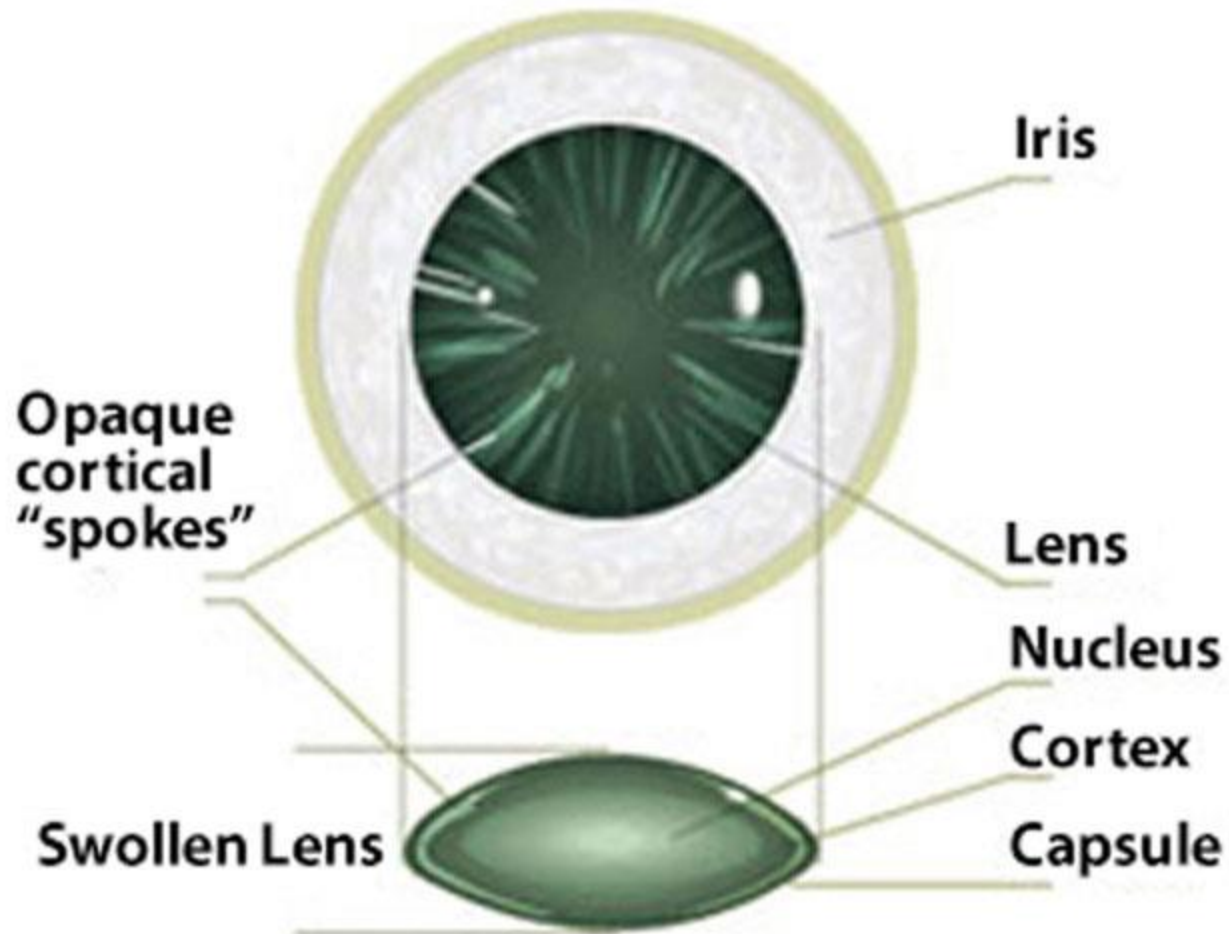


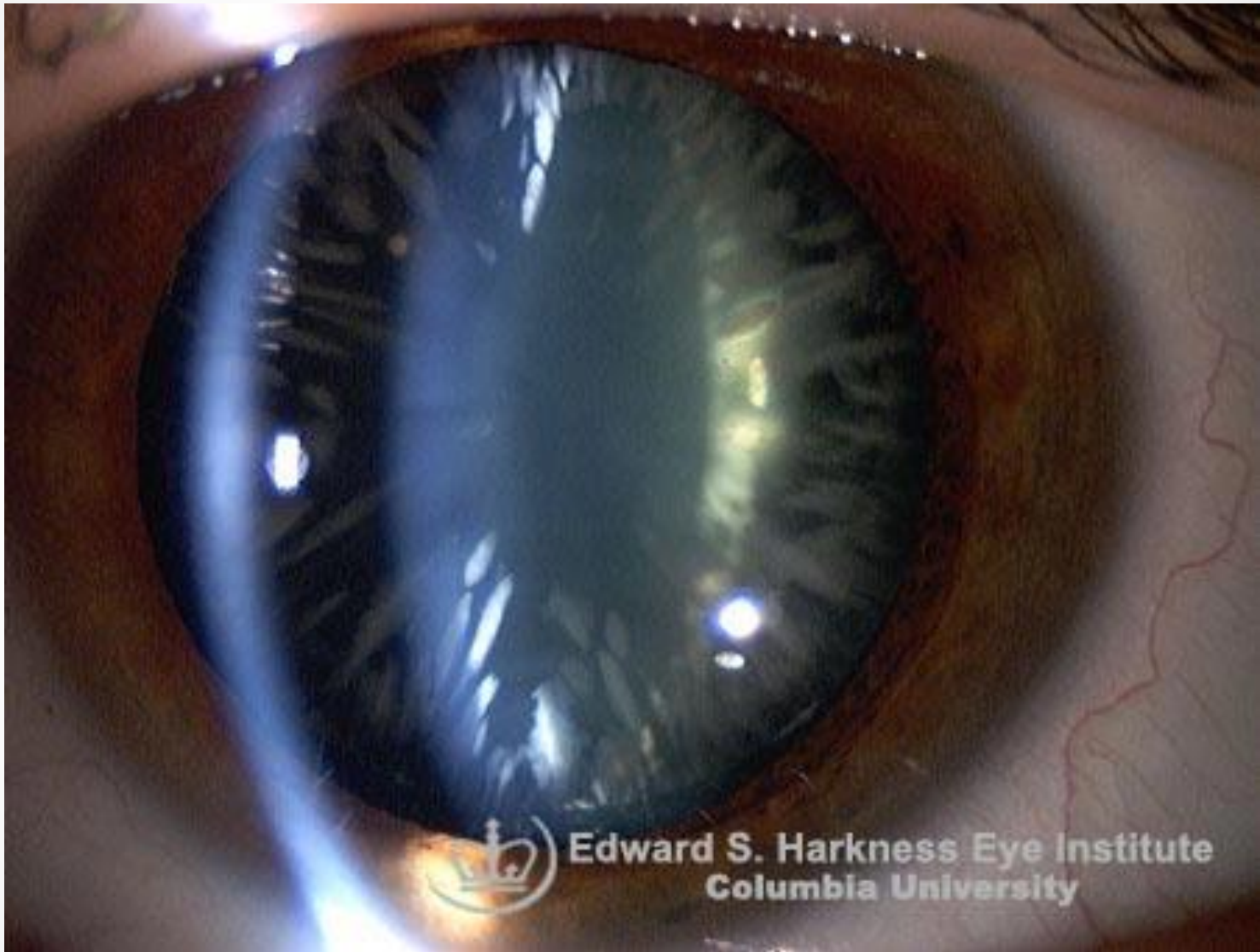
Nuclear cataract

Types of cataract

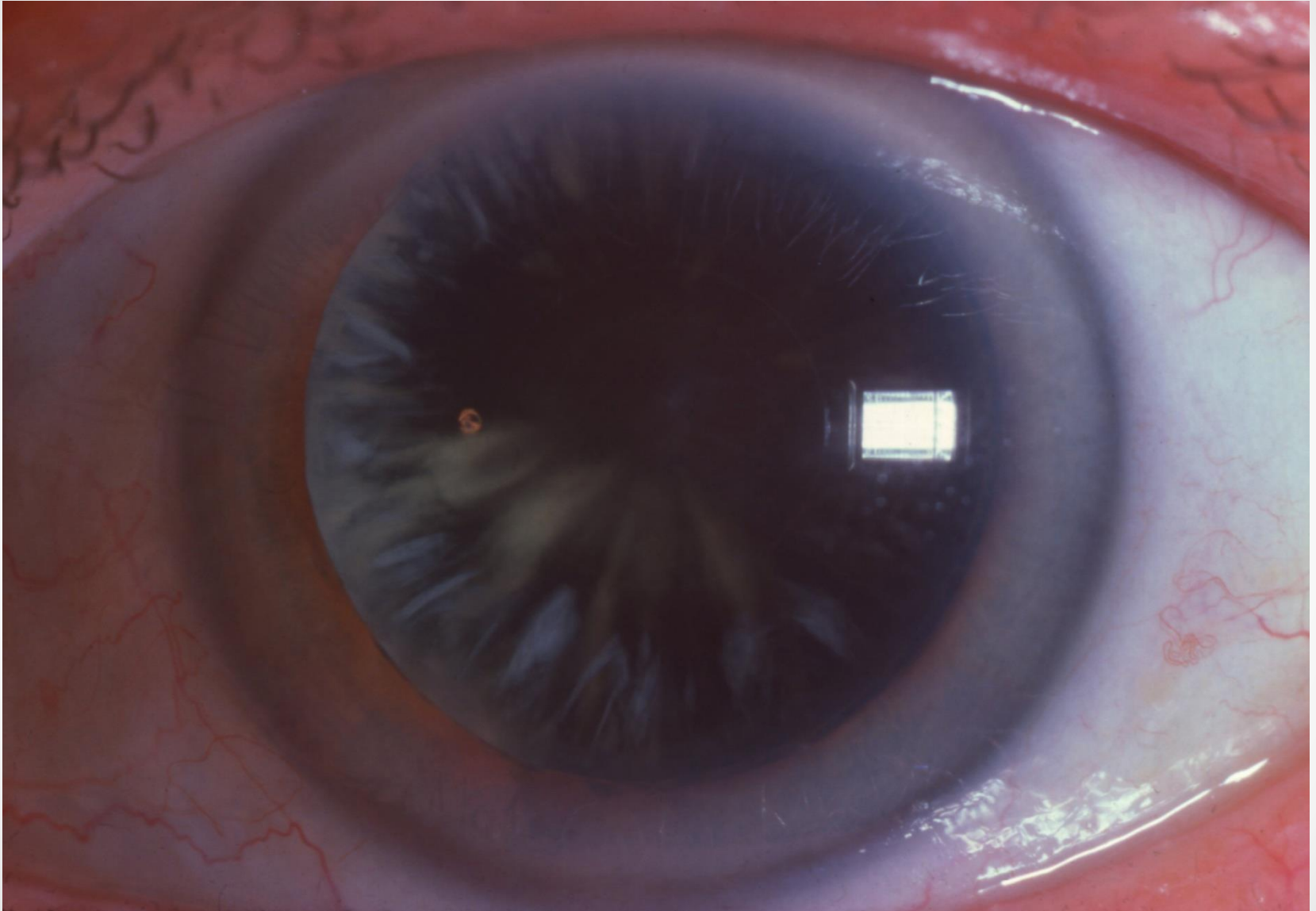
- **Cortical:**
 - Due to opacification of the lens cortex (outer layer).
 - They occur when changes in the water content of the periphery of the lens causes fissuring.
 - Present with problems like glare and light scattering at night

Cortical Cataract





Cortical cataract

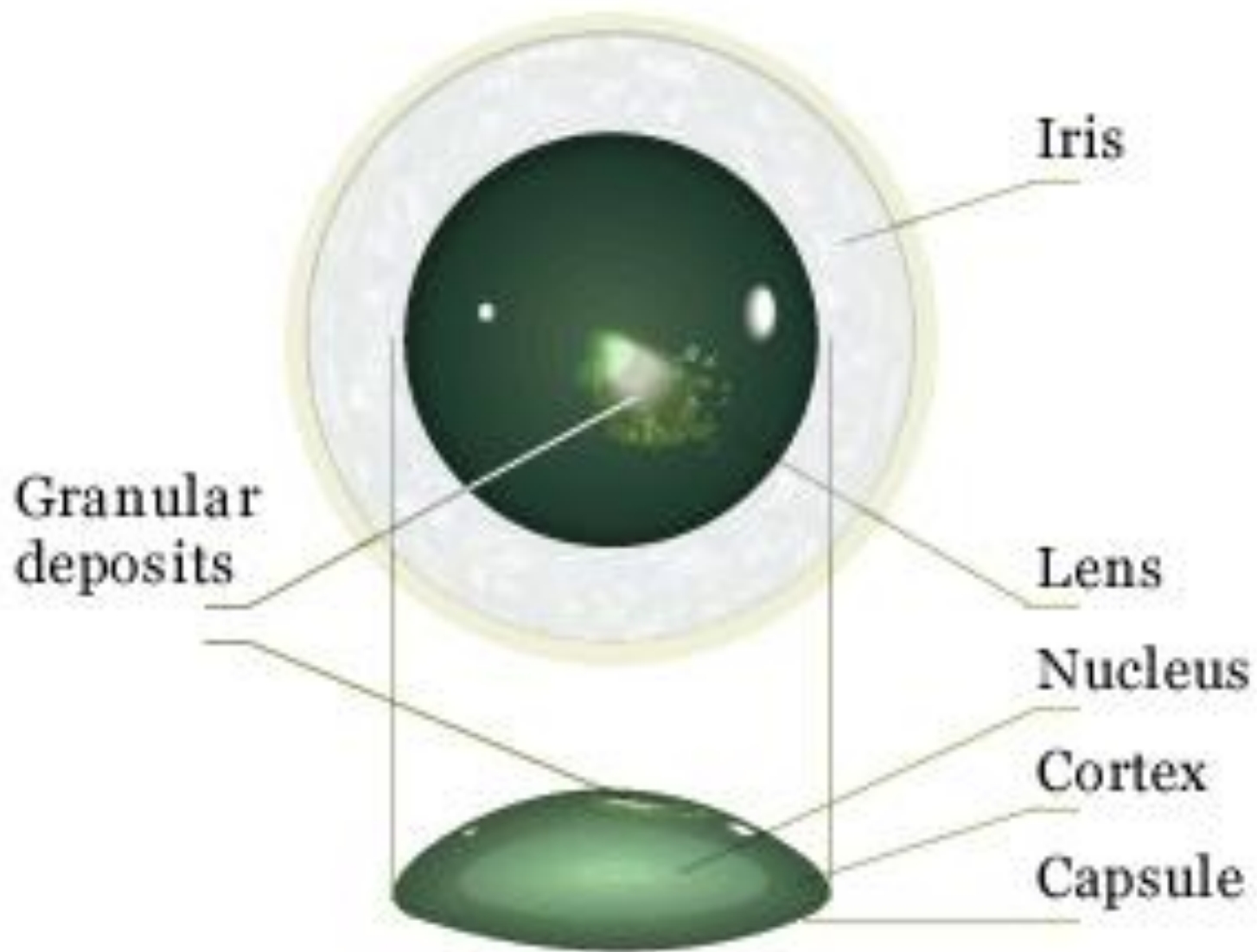


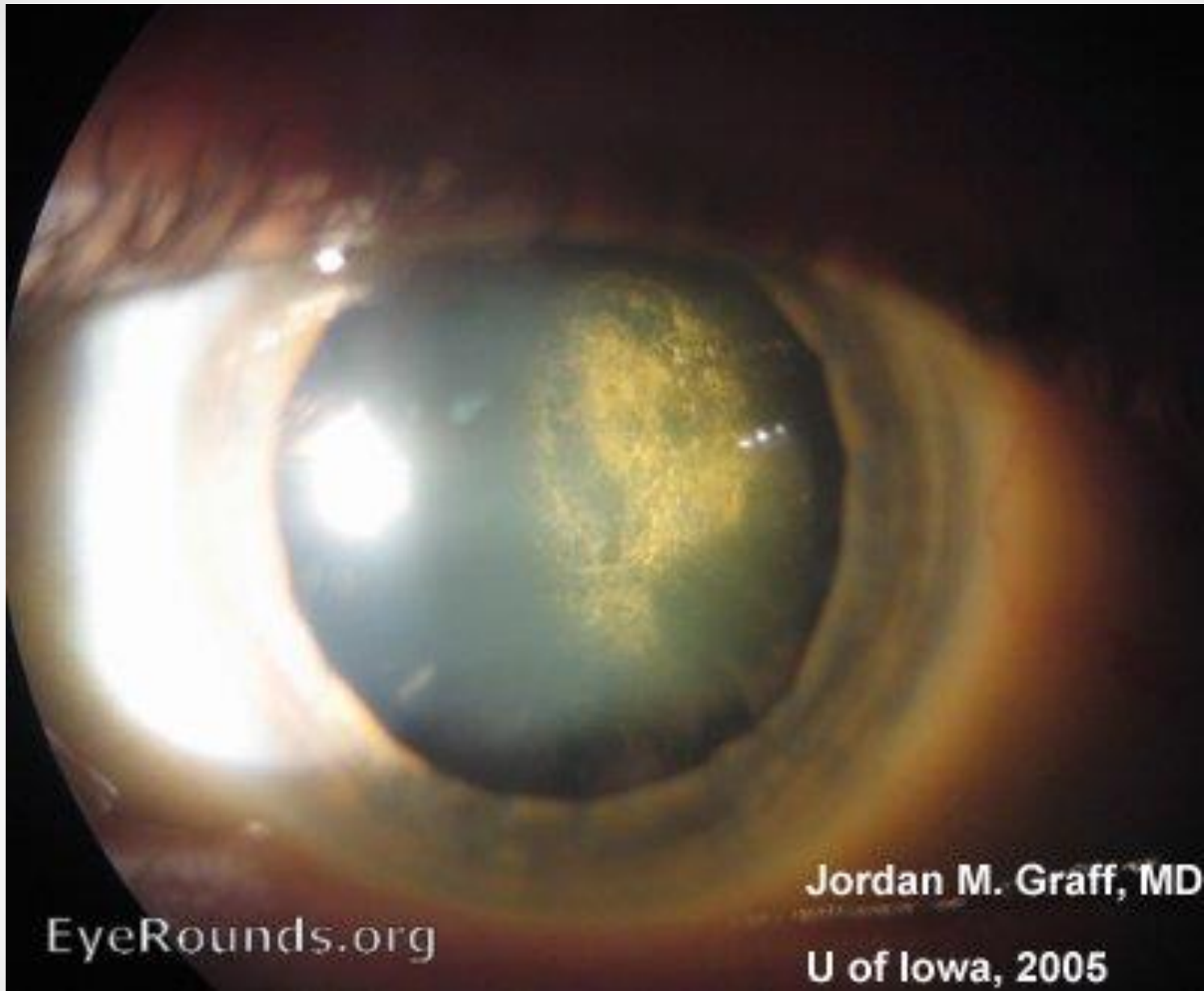Cortical cataract

Types of cataract

- **Posterior subcapsular:**
 - At back of the lens adjacent to the capsule
 - Because light becomes more focused toward the back of the lens, they can cause disproportionate symptoms for their size

Posterior Subcapsular Cataract





EyeRounds.org

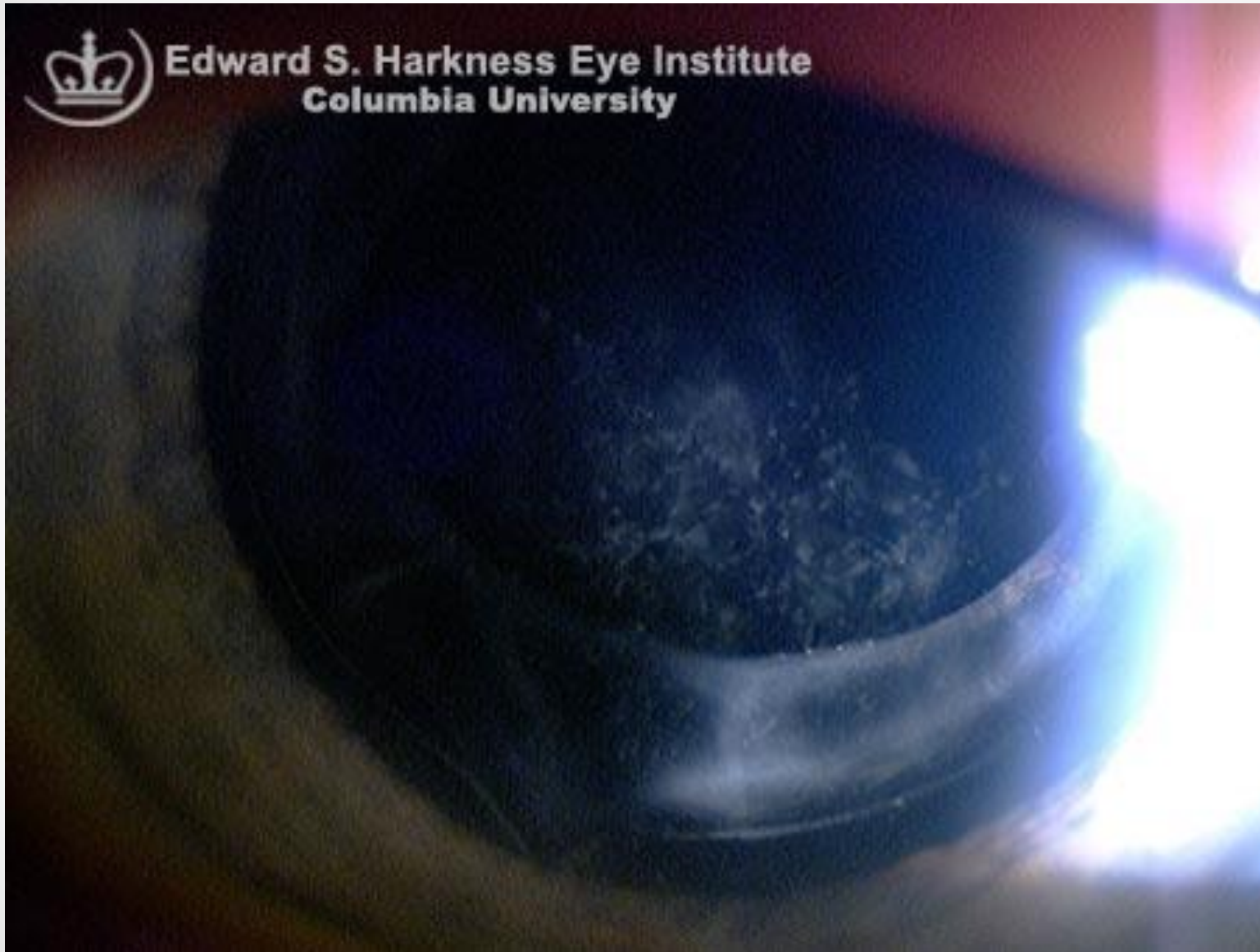Jordan M. Graff, MD

U of Iowa, 2005

Posterior subcapsular cataract

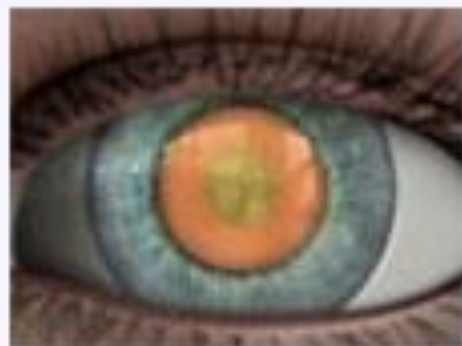

Edward S. Harkness Eye Institute
Columbia University

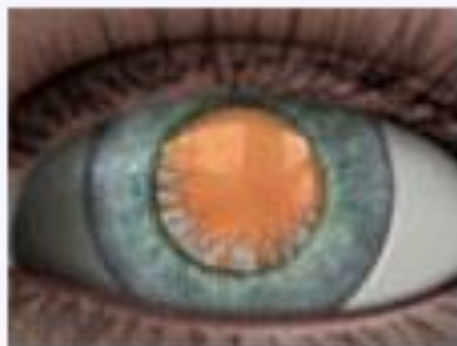

• Posterior subcapsular cataract •

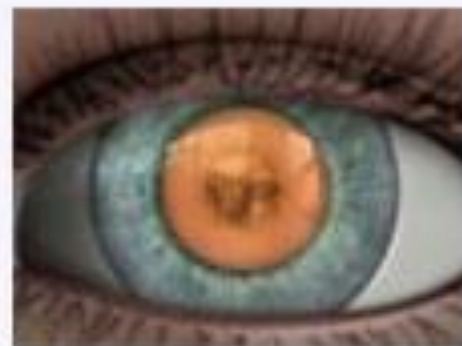Types of Cataracts



Nuclear cataract



Cortical cataract

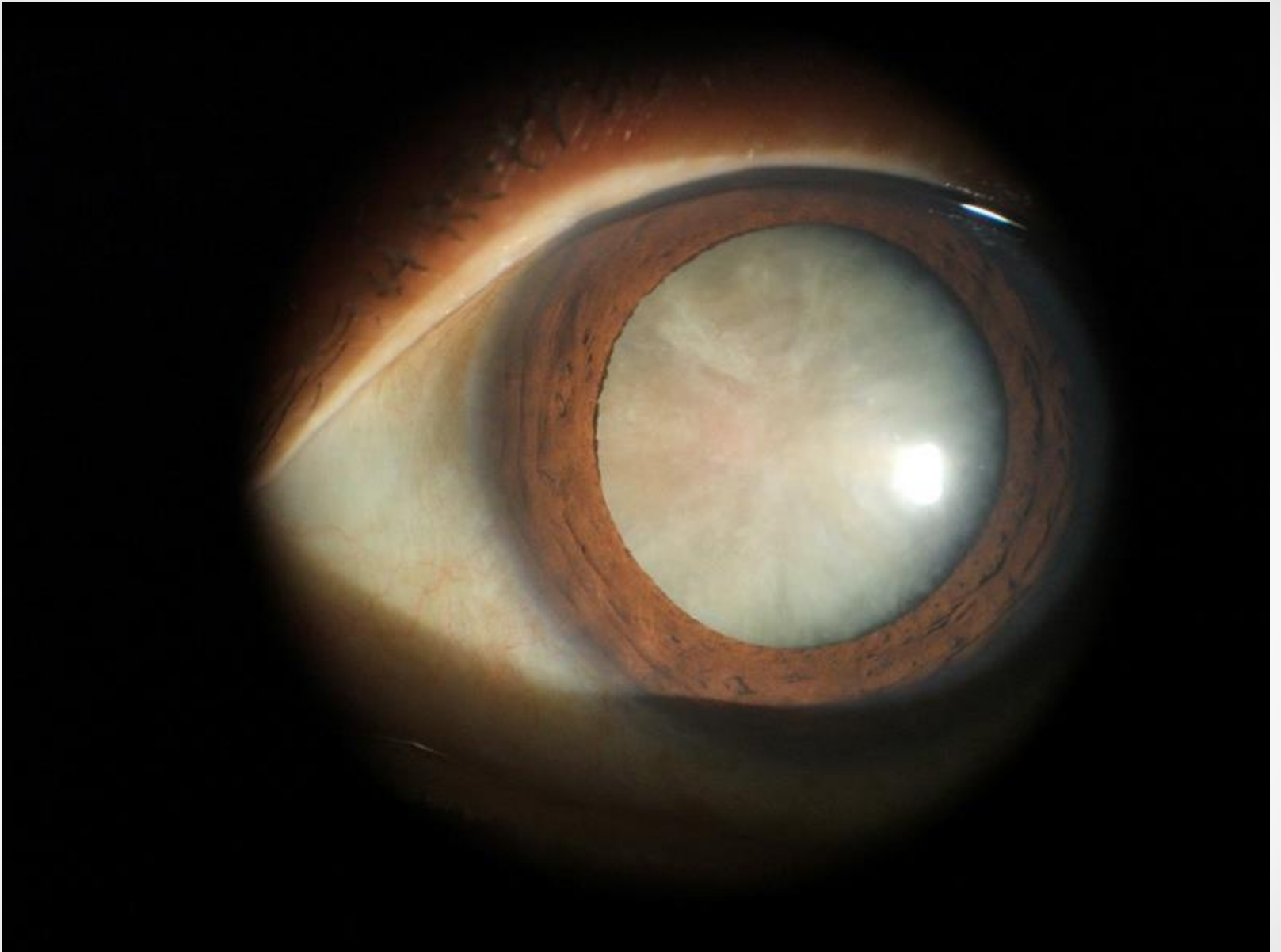


Posterior capsular cataract

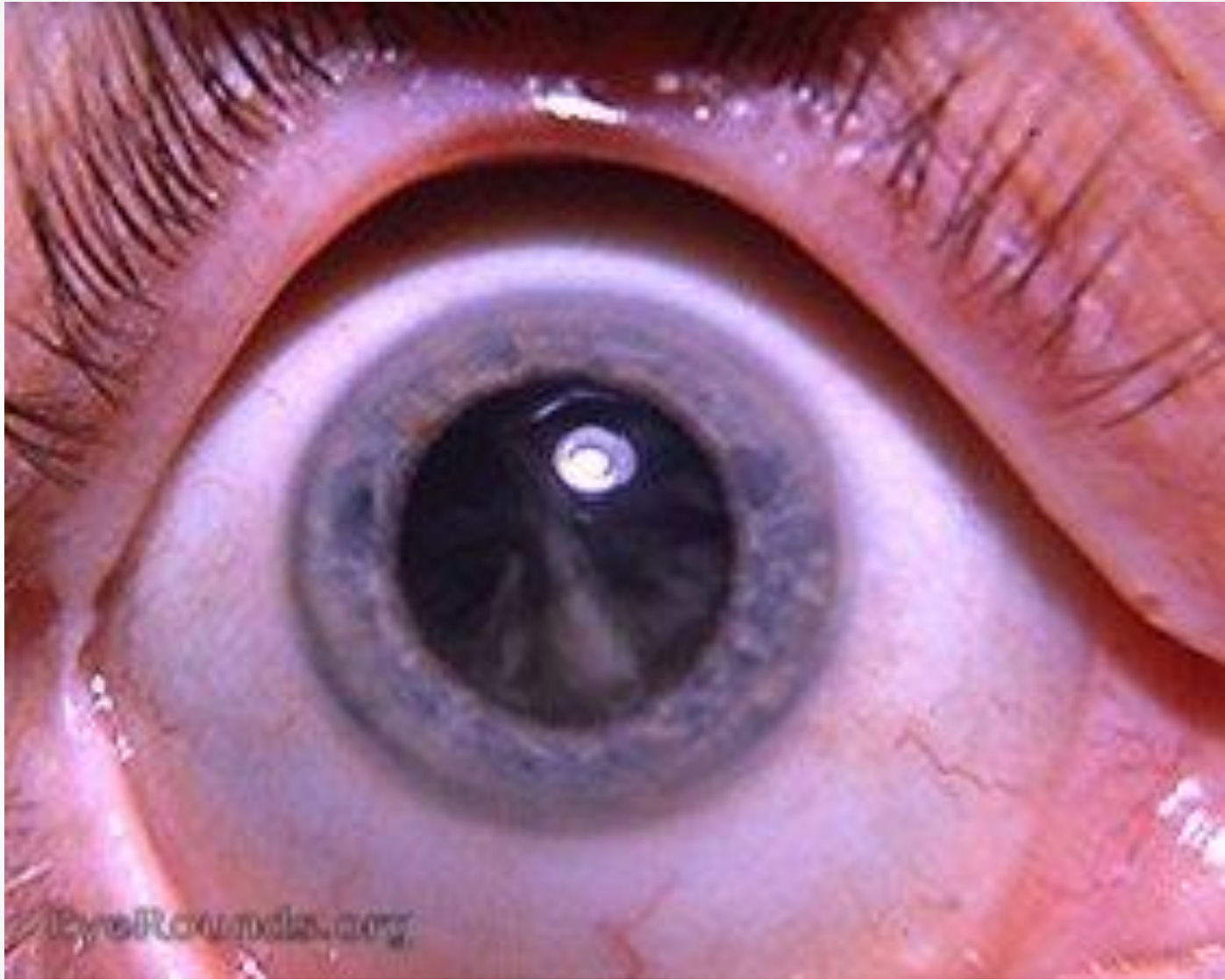Images courtesy of Eyemaginations™.

Other types

- In cataract, all of the lens protein is opaque
- Immature cataract has some transparent protein content.



• Mature cataract •



Immature cataract

Other types

- **Congenital cataract: which may be detected in adults.**
 - **Has a different classification and includes:**
 - lamellar
 - polar
 - sutural

Causes of cataract

1. Age:

- is the most common cause (senile cataract)
- results from cumulative exposure to environmental and other factors such as smoking, UV-B light and blood sugar level

Causes of cataract

2. Associated with Ocular conditions:

- Trauma
- Uveitis
- High myopia
- Topical medications (steroid)
- Intraocular tumors

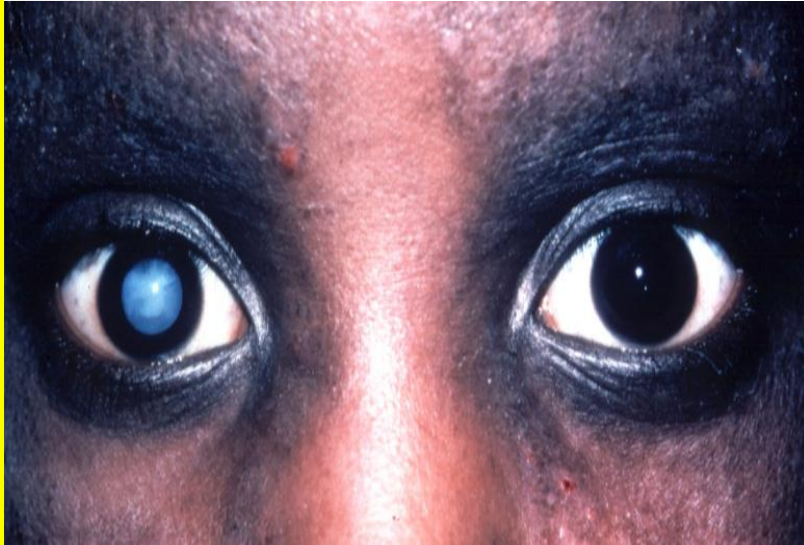Causes of cataract

3. Associated with systemic diseases:

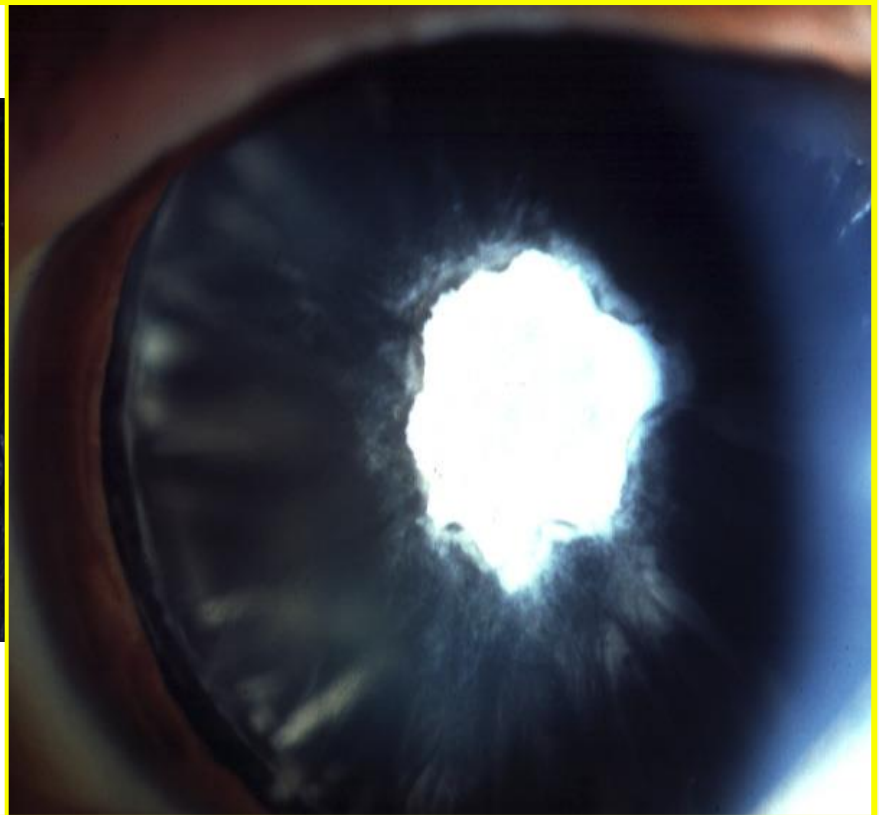
- DM
- Metabolic diseases (Galactosemia, Hypocalcemia, fabry disease)
- Systemic drugs (steroids , chlorpromazine)
- Infection (Cong. Rubella)
- Myotonic dystrophy
- Atopic dermatitis
- Systemic syndromes (Down's, Lowe's)
- Congenital Cataract (inherited)
- External radiation

- **Lowe syndrome** : is a rare X-linked recessive disorder characterized by congenital cataracts, hypotonia and areflexia , mental retardation, proximal tubular acidosis, aminoaciduria, phosphaturia, and low-molecular-weight proteinuria. Glaucoma is present in about 50% of cases.
- **Fabry disease**: is a rare X-linked (inherited) lysosomal storage disease

Other causes of cataract - atopic dermatitis



- Cataract develops in 10% of cases between 15-30 years
- Bilateral in 70%
- Frequently becomes mature



- Anterior subcapsular plaque (shield cataract)
- Wrinkles in anterior capsule

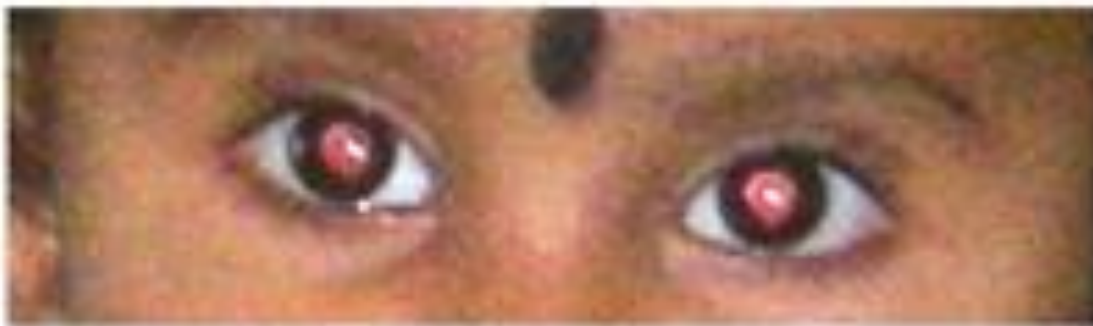Symptoms

- Loss of vision (painless progressive)
- Glare
- Change in refractive error
- Amblyopia (a failure of visual maturation); in infants.

Signs

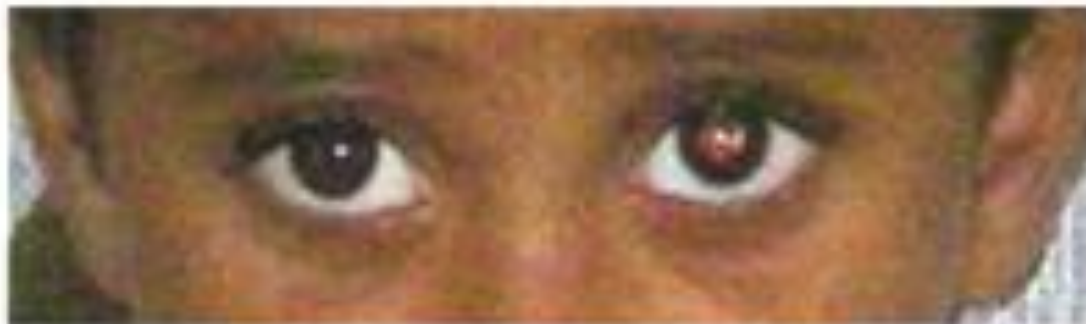- **Decreased visual acuity, especially when measured in light**
- **Lens opacity seen with SLE**
- **Black spot against the red reflex of the fundus**
- **Leukocoria (white pupillary reflex); it's caused by many conditions including congenital cataract**

Normal

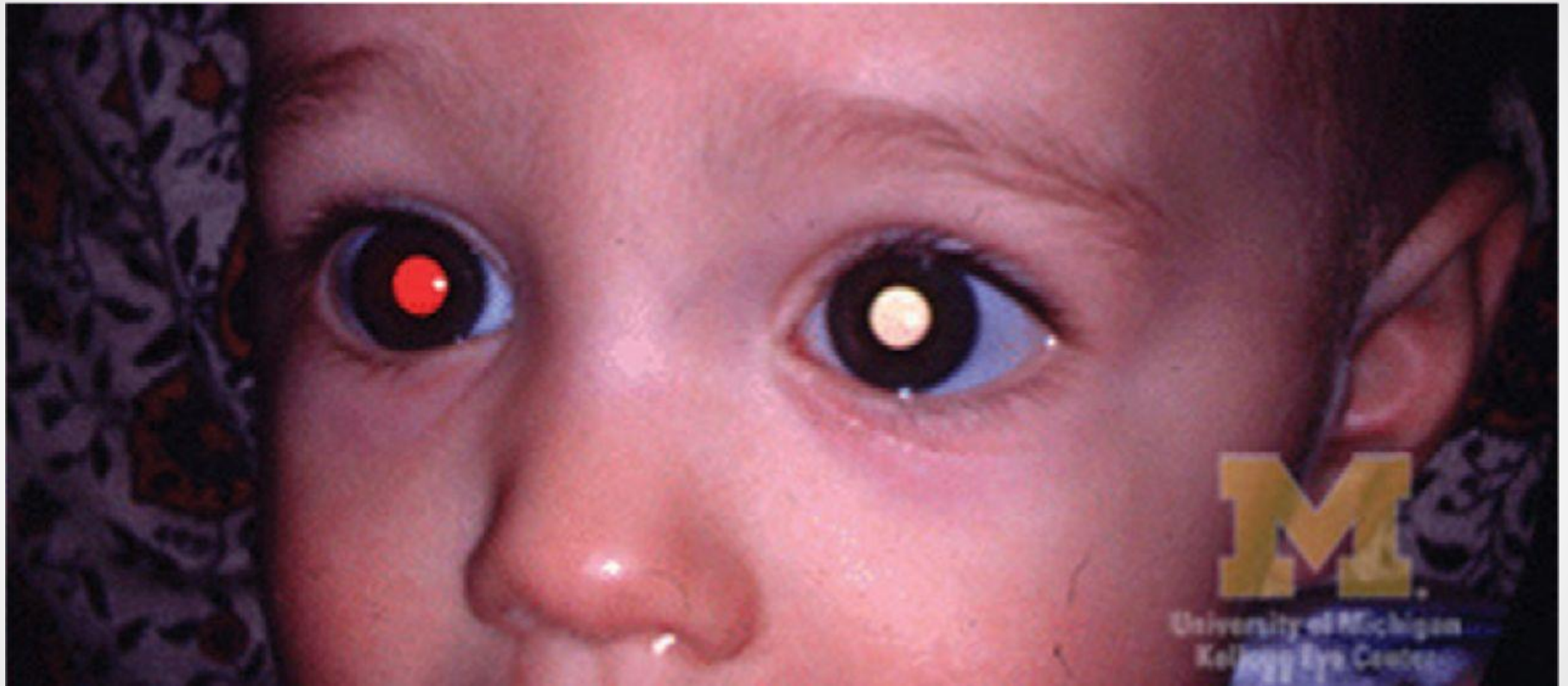

**Symmetrical
red reflex**

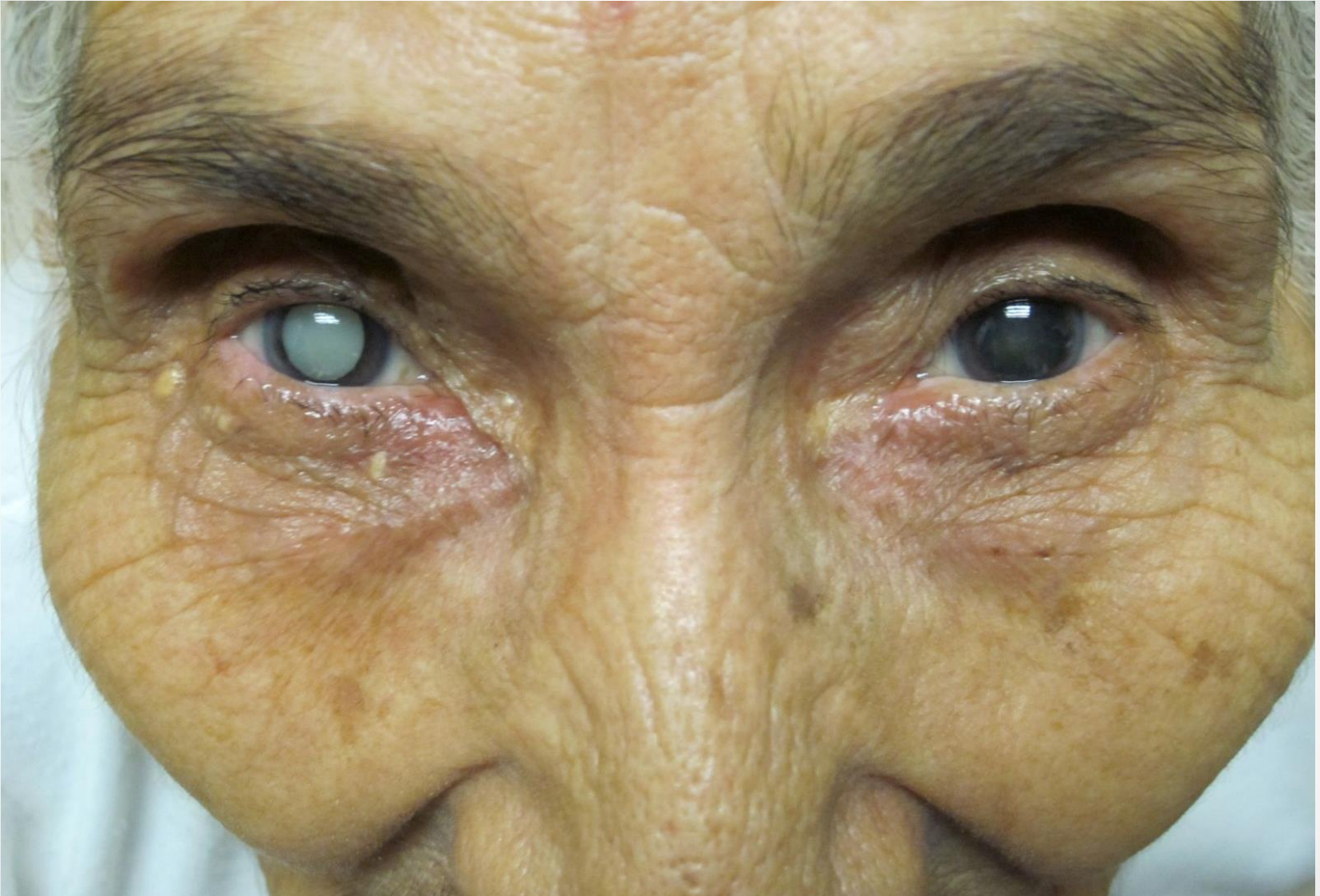Abnormal



Loss of reflex



Leukocoria

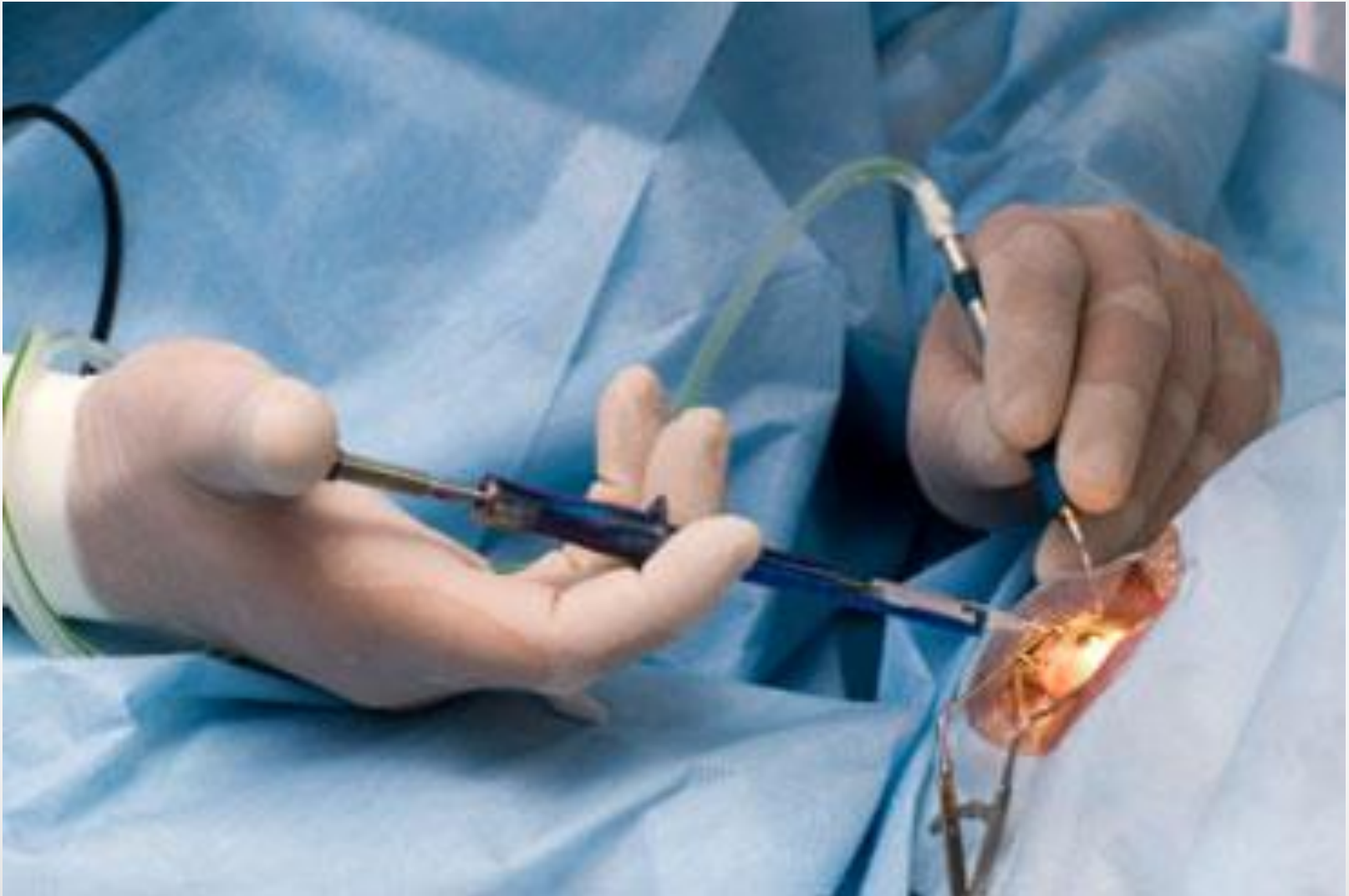


A cataract occurs when the lens of your eye becomes cloudy. Eventually, a cataract can **advance** to the degree of the one shown in this person's right eye.

Treatment


- No proven way to prevent cataract.
- Main stay of treatment is surgical removal of the affected lens.
- Indication of surgery: cataract reducing the quality of life.
- No need to wait for cataract ripening.

Cataract Surgery



Cataract Surgery

- Patient managed as a day case.
- Using Topical, LA and GA.
- The operation involves removal of most of the lens fibers and epithelial cells & insertion of a plastic lens implant of appropriate optical power.

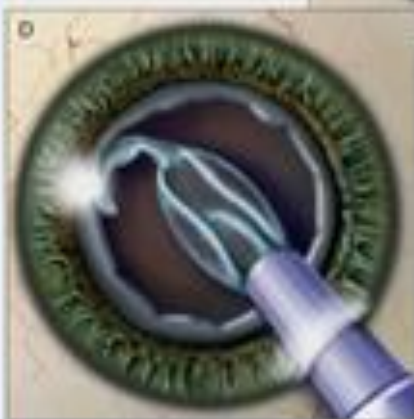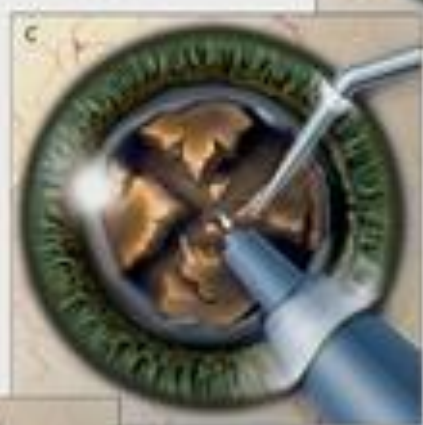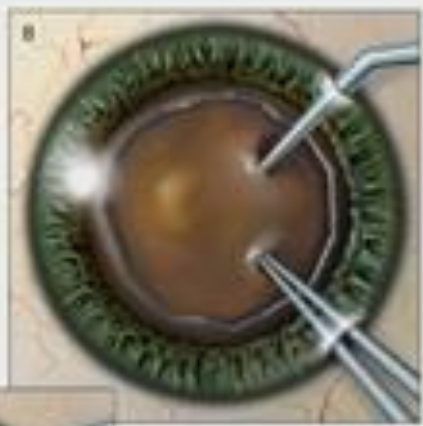


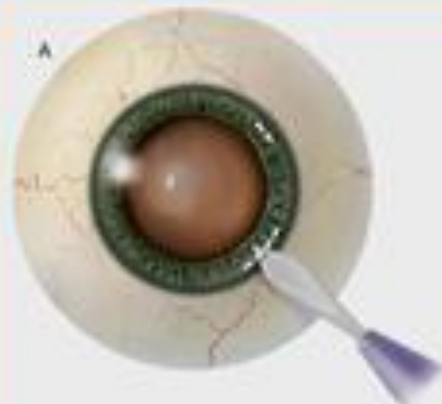Types of cataract surgeries

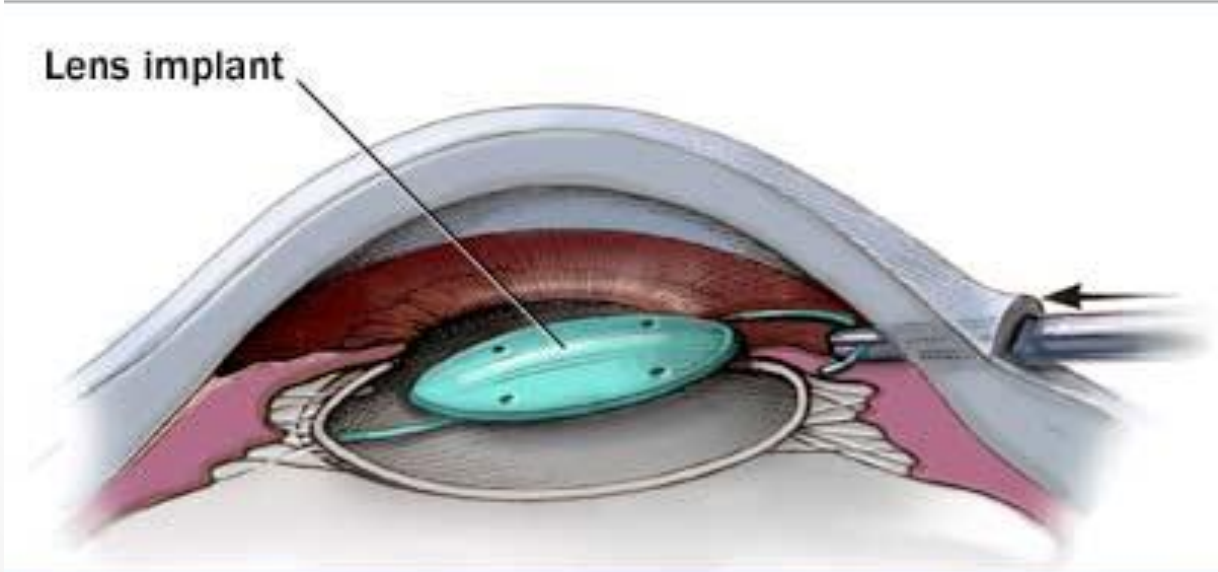
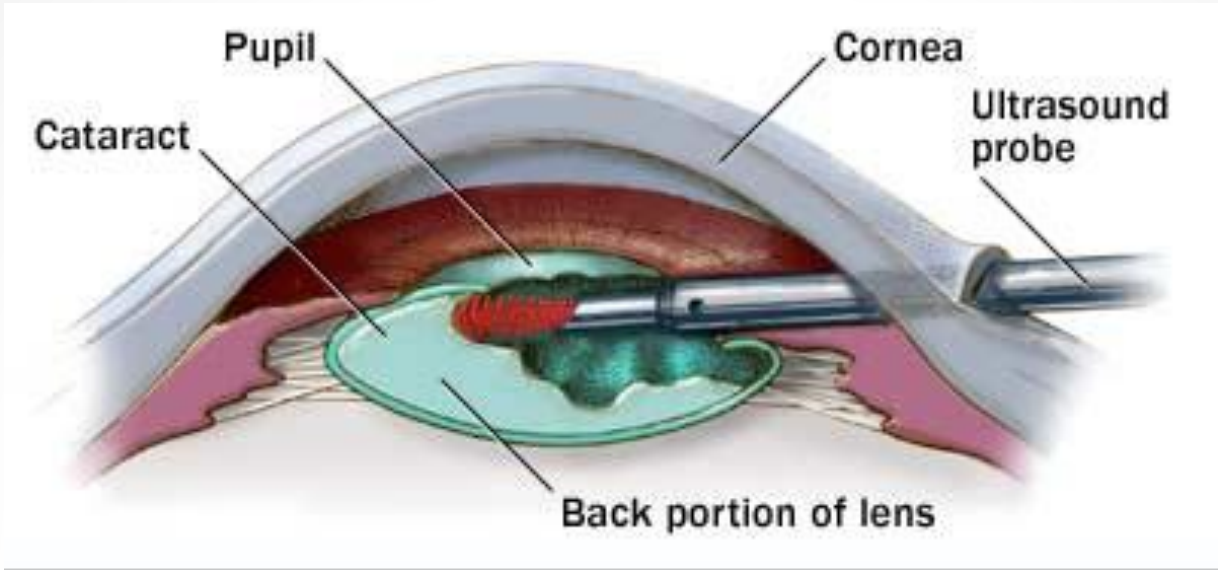
1. Phacoemulsification
2. Extra Capsular Cataract Extraction (ECCE)
3. Intra Capsular Cataract Extraction (ICCE)

Phacoemulsification

1. *Anaesthetic* - The eye is numbed with either a subtenon injection around the eye or using simple eye drops.
2. *Corneal Incision* - Two cuts are made through the clear cornea to allow insertion of instruments into the eye.
3. *Capsulorhexis* - A needle or small pair of forceps is used to create a circular hole in the capsule (or bag) in which the lens sits.
4. *Phacoemulsification* - A handheld probe is used to break up and emulsify the lens into liquid using the energy of ultrasound waves. The resulting 'emulsion' is sucked away.
5. *Irrigation and Aspiration* - The cortex which is the soft outer layer of the cataract is aspirated or sucked away. Fluid removed is continually replaced with a salt solution to prevent collapse of the structure of the anterior chamber (the front part of the eye).
6. *Lens insertion* - A plastic foldable lens is inserted to the capsular bag that is used to contain the natural lens. Some surgeons will also inject an antibiotic in to the eye to reduce the risk of infection.
The final step is to inject salt water in to the corneal wounds to cause the area to swell and seal the incision.



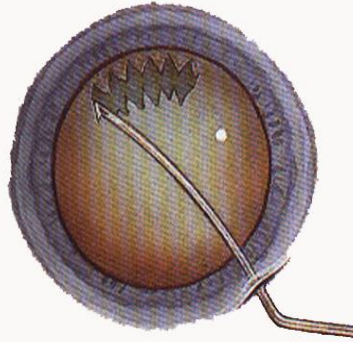
© 2004
Lippincott
Williams &
Wilkins




Extra Capsular Cataract Extraction

- Consists of removing the lens manually, but leaving the majority of the capsule intact. The lens is expressed through a 10–12 mm incision which is closed with sutures at the end of surgery.
- Extracapsular extraction is less frequently performed than phacoemulsification but can be useful when dealing with very hard cataracts or other situations where emulsification is problematic.
- Manual small incision cataract surgery (MSICS) has evolved from extracapsular cataract extraction. In MSICS, the lens is removed through a self-sealing scleral tunnel wound in the sclera which, ideally, is watertight and does not require suturing.

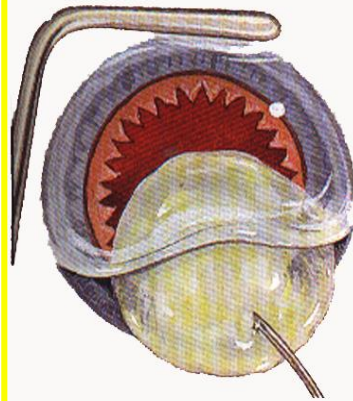
1. Anterior capsulotomy



2. Completion of incision



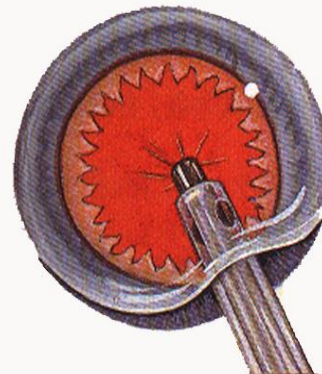
3. Expression of nucleus



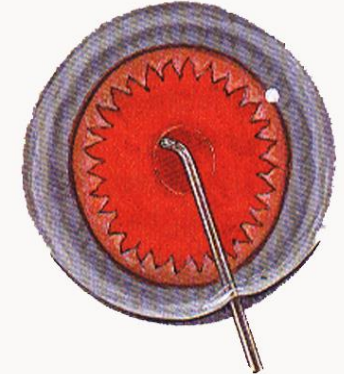
4. Cortical cleanup

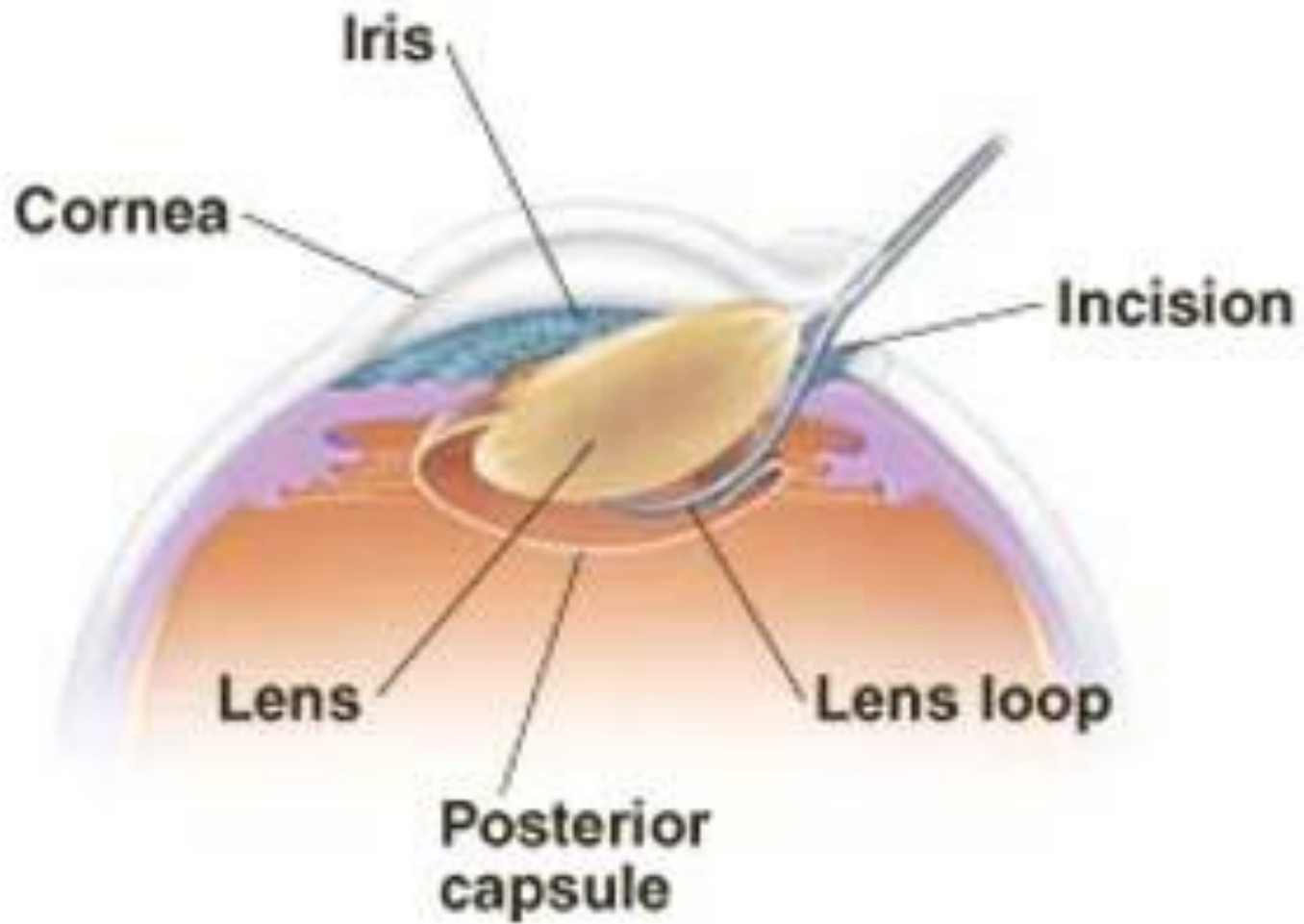


5. Care not to aspirate posterior capsule accidentally

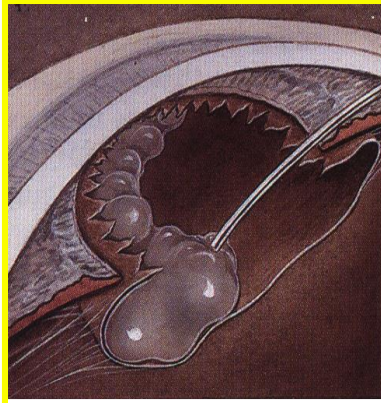


6. Polishing of posterior capsule, if appropriate

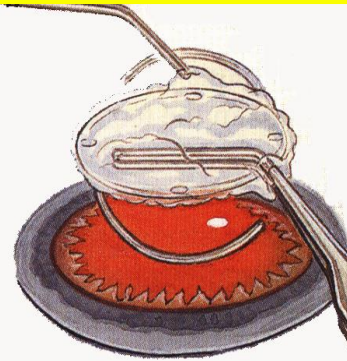




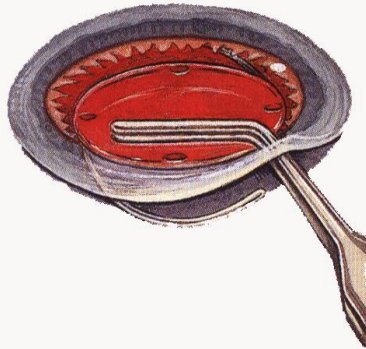
7. Injection of viscoelastic substance



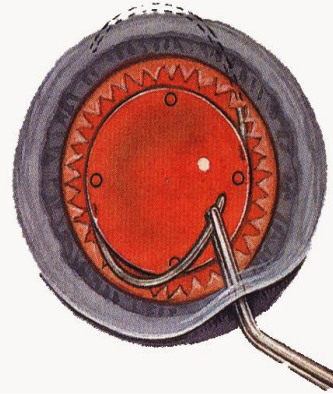
8. Grasping of IOL and coating with viscoelastic substance



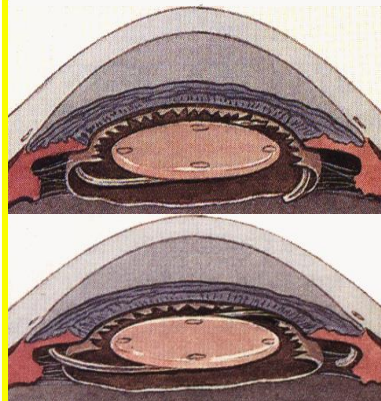
9. Insertion of inferior haptic and optic




10. Insertion of superior haptic



11. Placement of haptics into capsular bag and not into ciliary sulcus



12. Dialling of IOL into horizontal position



Intracapsular cataract extraction

- The lens and surrounding capsule are removed in one piece through a large incision while pressure is applied to the vitreous membrane.
- It is rarely performed as the surgery has a high rate of complications.

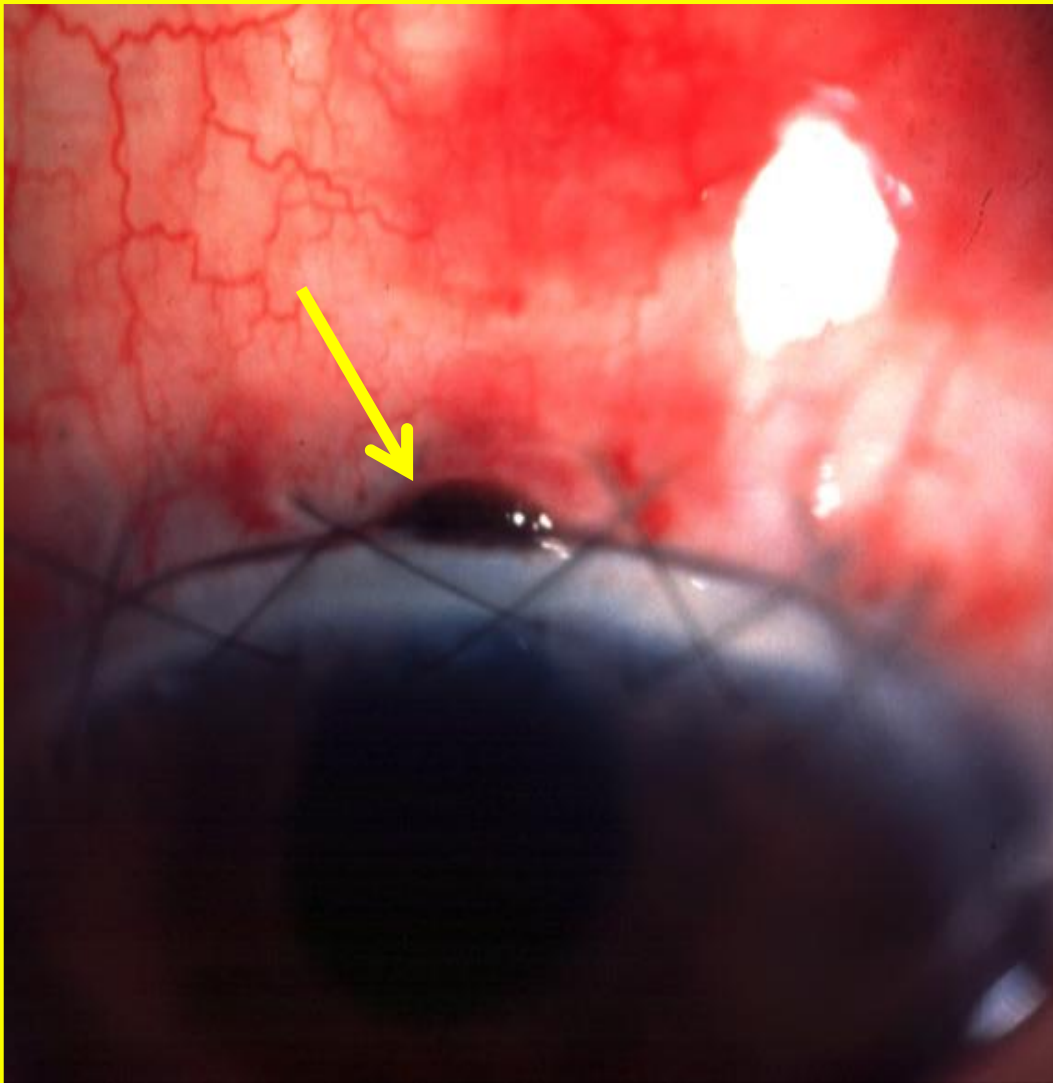
Post-op care

- Patient is given a short course of steroids and antibiotics drops.
- For near vision; since the patient cannot accommodate (spectacle, multifocal intraocular lenses)

Complications of cataract surgery

1. **Vitreous loss: a risk for glaucoma or retinal traction**
 - tx: vitrectomy at operation time and delay of IOL placement
2. **Iris prolapse: immediately post-op.**
 - tx: surgical repair

Iris prolapse



Cause

- Usually inadequate suturing of incision
- Most frequently follows inappropriate management of vitreous loss

Treatment

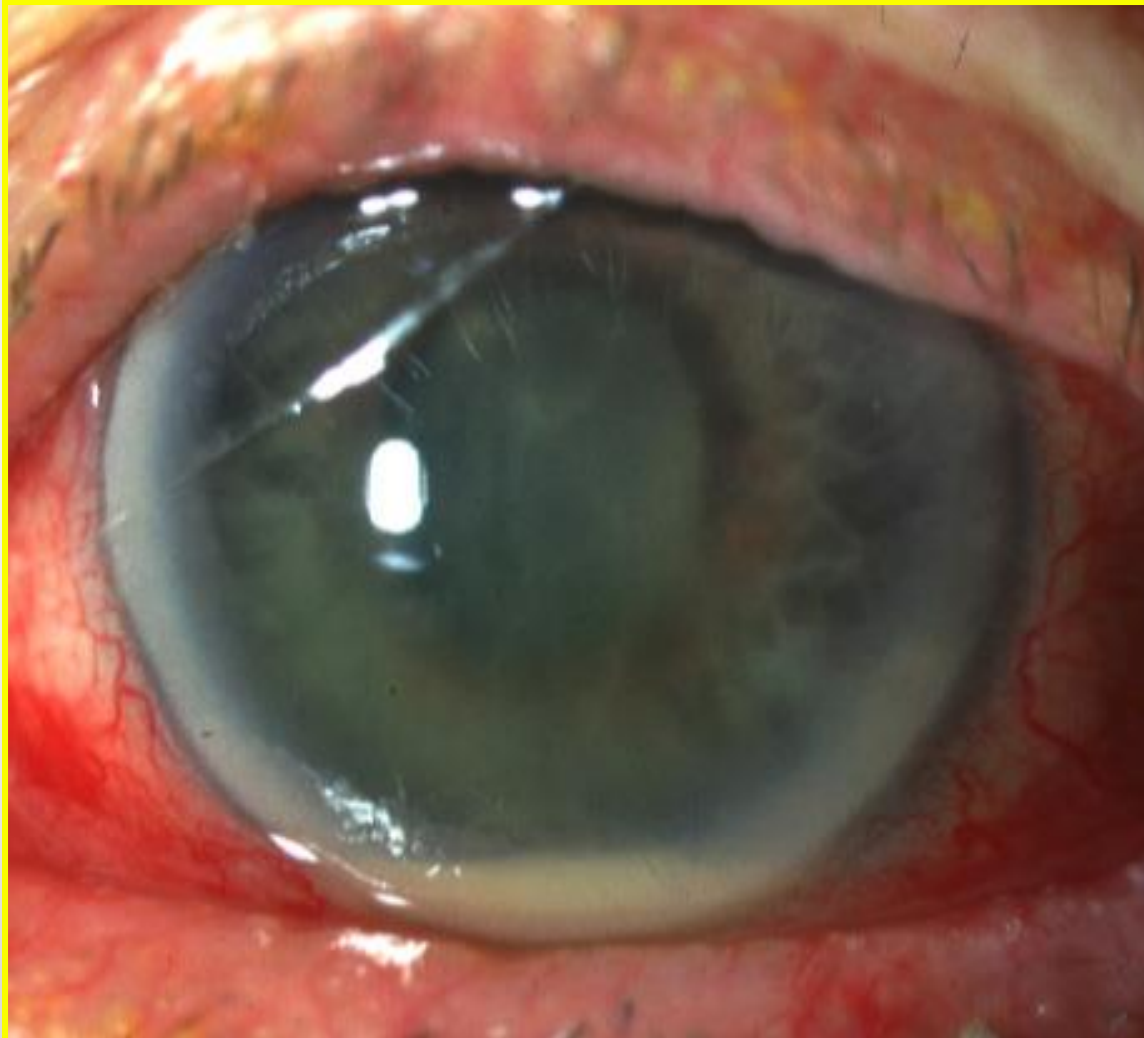- Excise prolapsed iris tissue
- Resuture incision

Complications of cataract surgery

- 3- Endophthalmitis: a serious but rare infective complication. Within few days of surgery patient presents with:
- 1- painful red eye
 - 2- reduced visual acuity
 - 3- hypopyon; collection of pus in the anterior chamber
- Tx: emergency; intravitreal broad spectrum Abx

Acute bacterial endophthalmitis

Incidence – 0.3%



Common causative organisms

- *Staph. epidermidis*
- *Staph. aureus*
- *Pseudomonas sp.*

Source of infection

- Patient's own external bacterial flora is most frequent culprit
- Contaminated solutions and instruments
- Environmental flora including that of surgeon and operating room personnel

4. **Postoperative corneal astigmatism by tight sutures**
5. **Macular edema**
Tx: topical NSAIDs and steroids
6. **Retinal detachment**
7. **Opacification of the posterior capsule**
occurs in 20% of pt, when residual epithelium forms
a scar
Tx: out-pt; ndYAG laser

Thank you