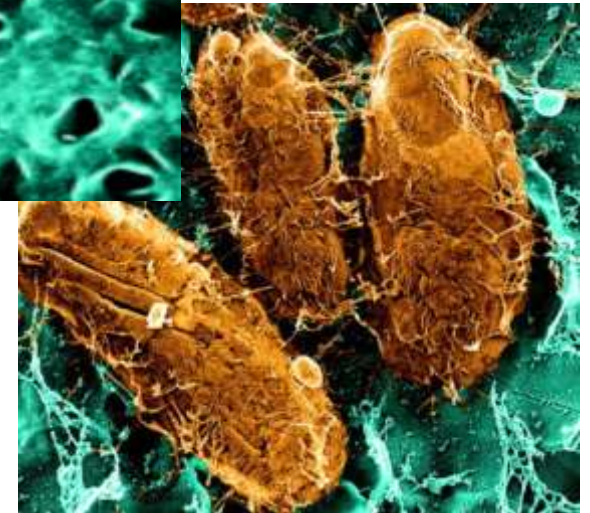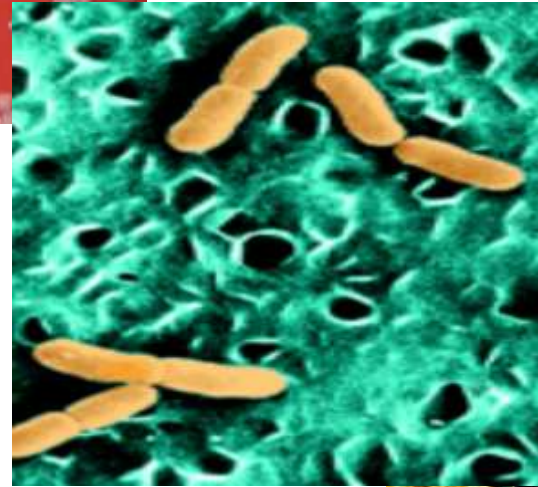
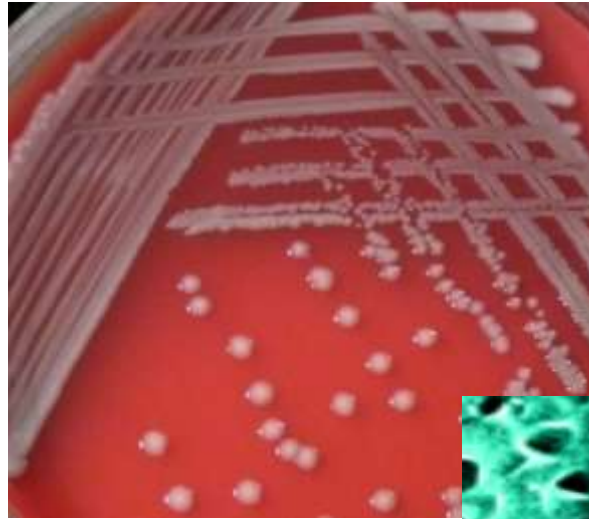


# Microbiology of Urogenital system

---



Anas Abu-Humaidan  
M.D. Ph.D.

Sexually transmitted diseases

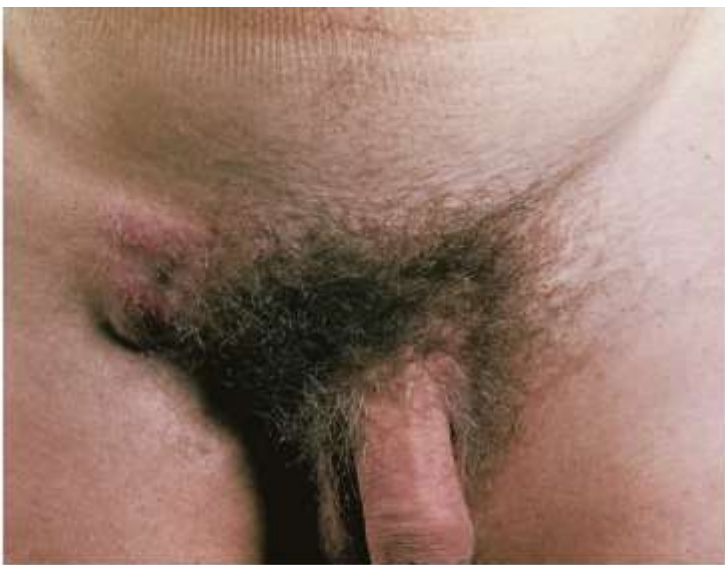Genital infections encompasses a variety of clinical entities, including :

- **Bacterial vaginosis**
- **Chancroid**
- **Gonorrhoea**
- **Chlamydia**
- **Syphilis**
- **Trichomoniasis**
- **Vulvovaginal candidiasis**
- **Genital warts**
- **Human immunodeficiency virus.**
- **Genital herpes**

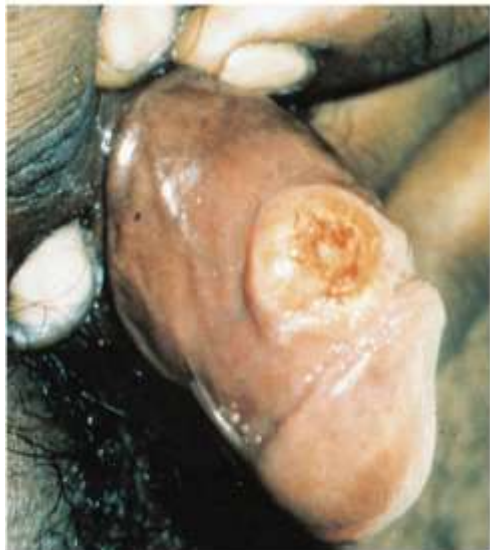SEXUALLY TRANSMITTED AND SEXUALLY TRANSMISSIBLE MICROORGANISMS		
BACTERIA	VIRUSES	OTHER <sup>a</sup>
Transmitted in Adults Predominantly by Sexual Intercourse		
Neisseria gonorrhoeae	HIV (types 1 and 2)	Trichomonas vaginalis
Chlamydia trachomatis	Human T cell lymphotropic virus type 1	Pthirus pubis
Treponema pallidum	Herpes simplex virus type 2	
Haemophilus ducreyi	Human papillomavirus (multiple genital genotypes)	
Klebsiella (Calymmatobacterium) granulomatis	Hepatitis B virus <sup>b</sup>	
Ureaplasma urealyticum	Molluscum contagiosum virus	
Mycoplasma genitalium		

## Ulcerative genital infections

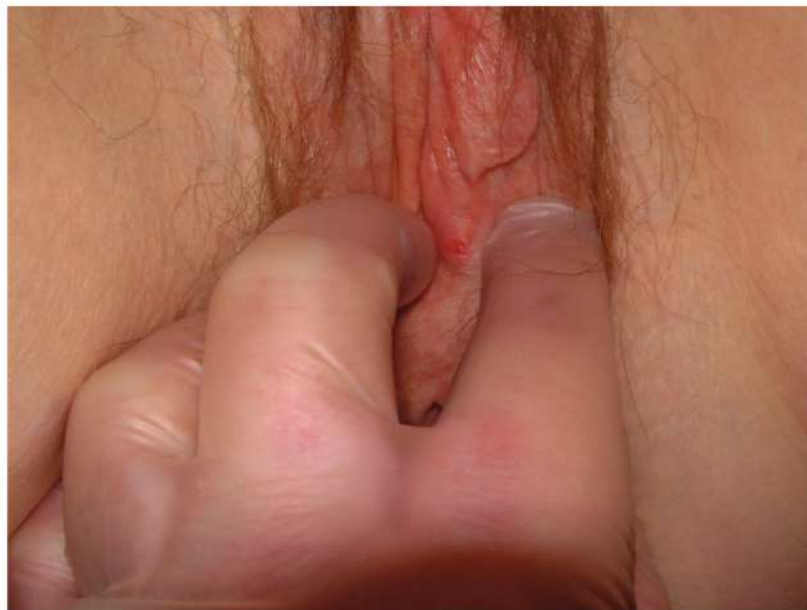- Genital ulceration reflects a set of important STIs, most of which sharply increase the risk of sexual acquisition and shedding of HIV.
- PCR testing of ulcer specimens demonstrated **HSV** in 62% of patients, **Treponema pallidum** (the cause of **syphilis**) in 13%, and **Haemophilus ducreyi** (the cause of **chancroid**) in 12–20%.
- In Asia and Africa, **chancroid** was once considered the most common type of genital ulcer, PCR testing of genital ulcers now clearly implicates **genital herpes** was by far the most common cause of genital ulceration.



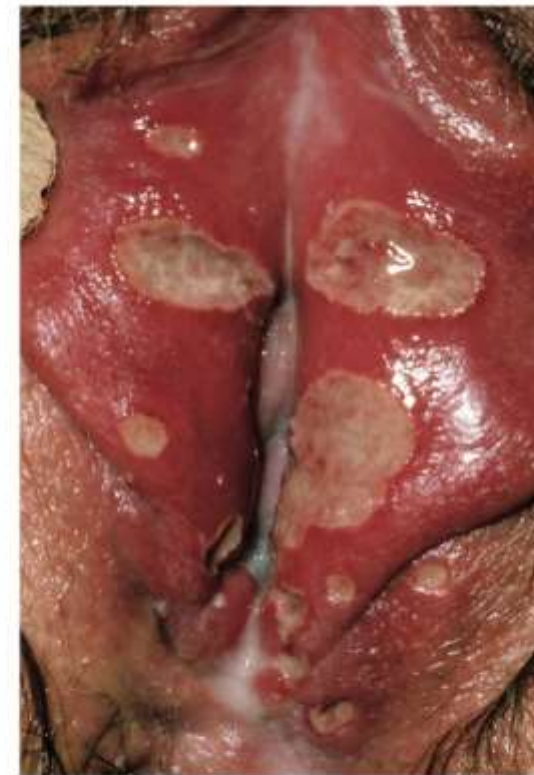**FIGURE 35-7**  
Lymphogranuloma venereum (LGV): striking tender lymphadenopathy occurring at the femoral and inguinal lymph nodes, separated by a groove made by Poupart's ligament. This "sign-of-the-groove" is not considered specific for LGV; for example, lymphomas may present with this sign.



**FIGURE 78-2**  
Primary syphilis with a firm, nontender chancre.



**FIGURE 35-6**  
Genital herpes. A relatively mild, superficial ulcer is typically seen in episodic outbreaks. (Courtesy of Michael Remington, University of Washington Virology Research Clinic.)

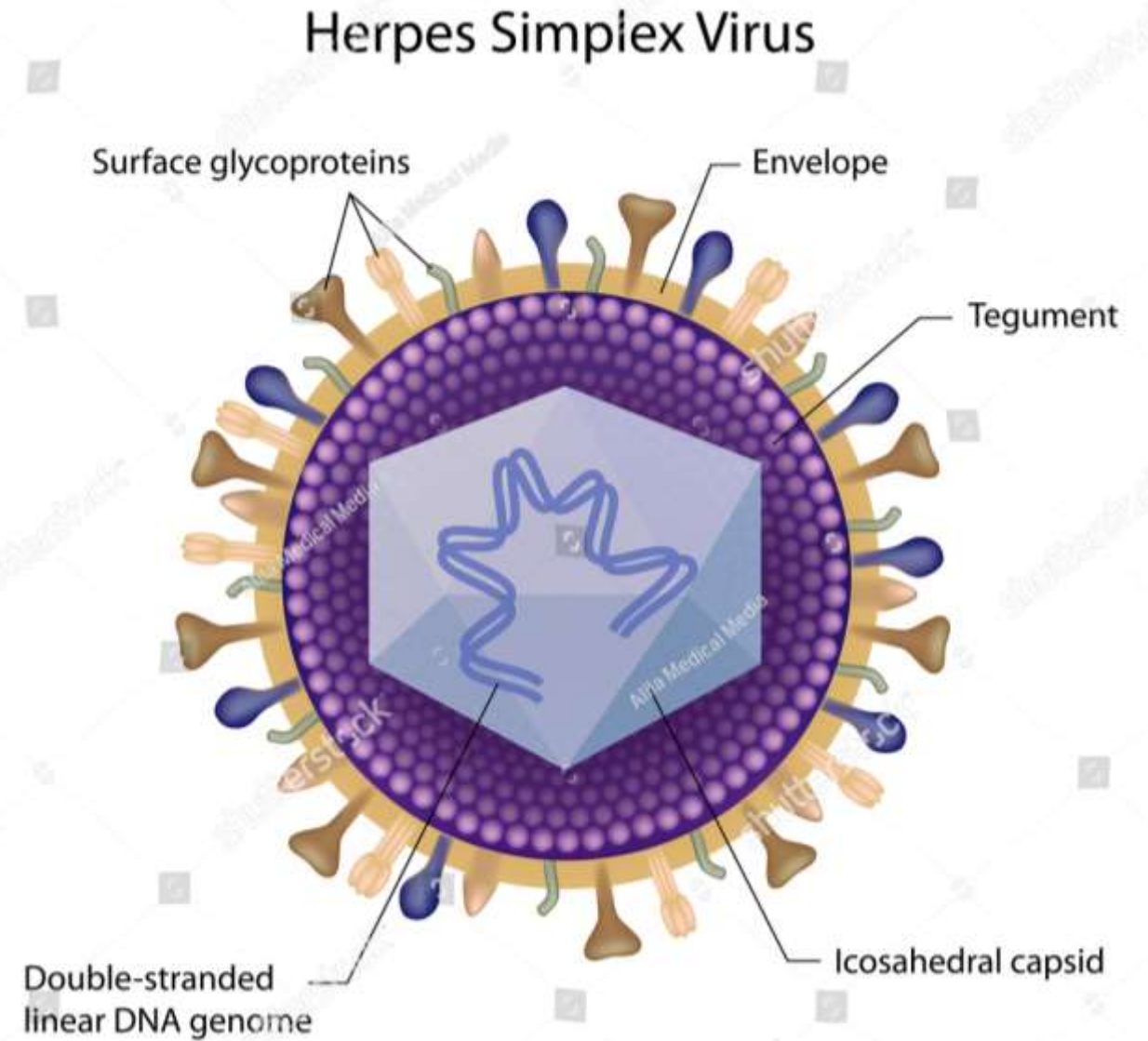


**FIGURE 35-5**  
Chancroid: multiple, painful, punched-out ulcers with undermined borders on the labia occurring after autoinoculation.

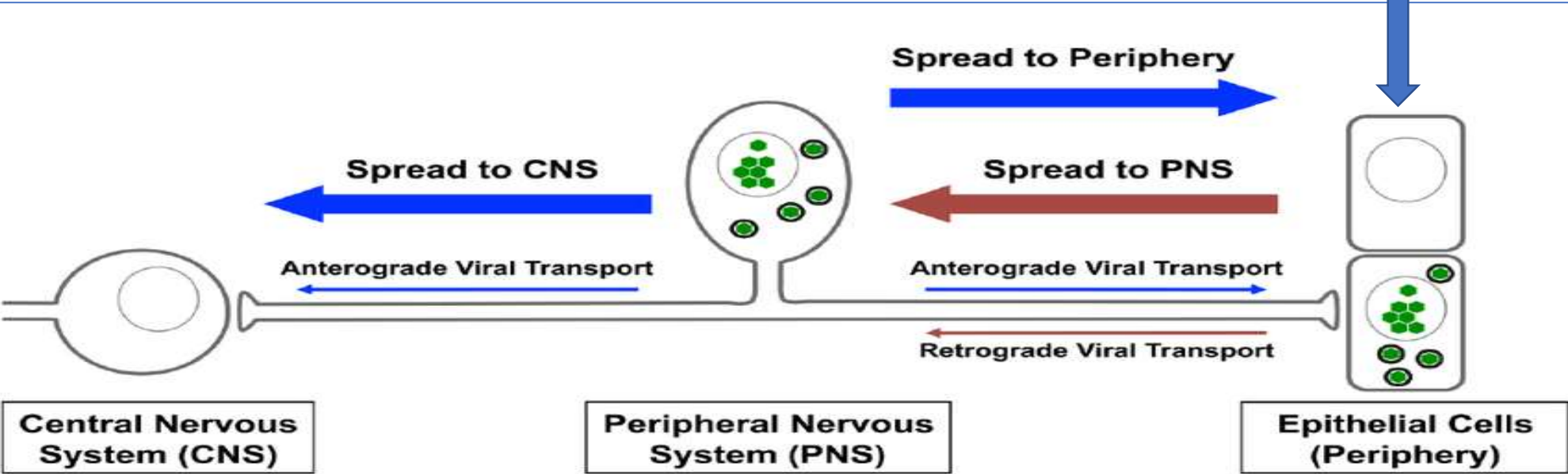
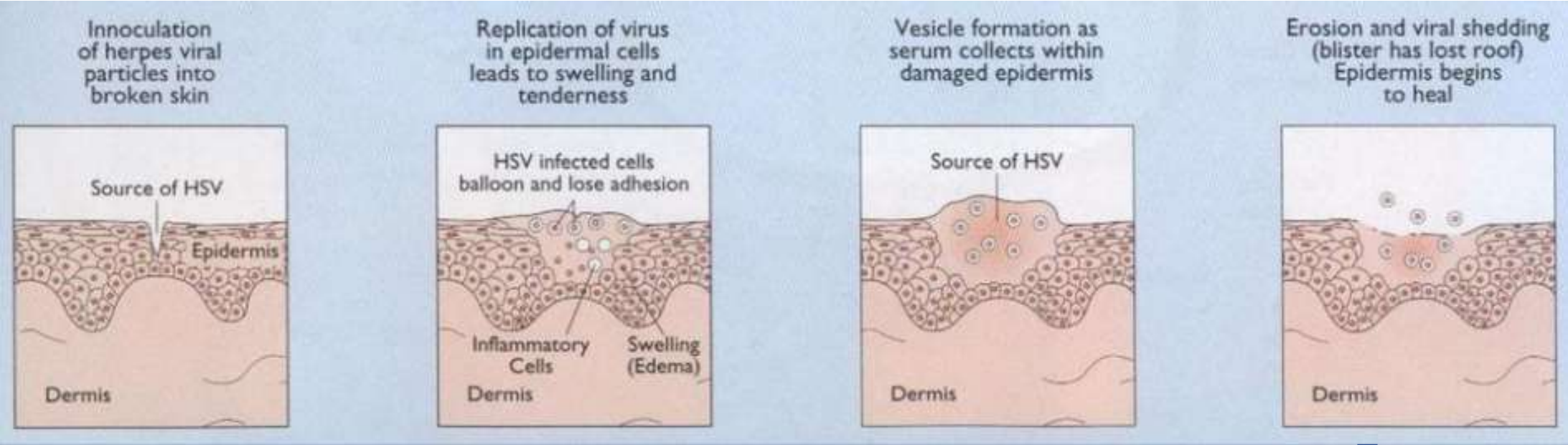


## Ulcerative genital infections / Genital herpes / epidemiology

- **Genital herpes** is a common sexually transmitted disease, affecting **more than 400 million persons worldwide**
- In the United States, nearly **one in five adults** (approximately 50 million persons) has **HSV-2** infection, with 1 million new infections occurring each year.
- It is characterized by **lifelong** infection and periodic **reactivation**

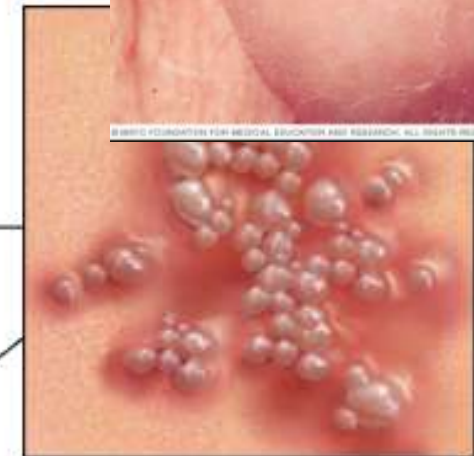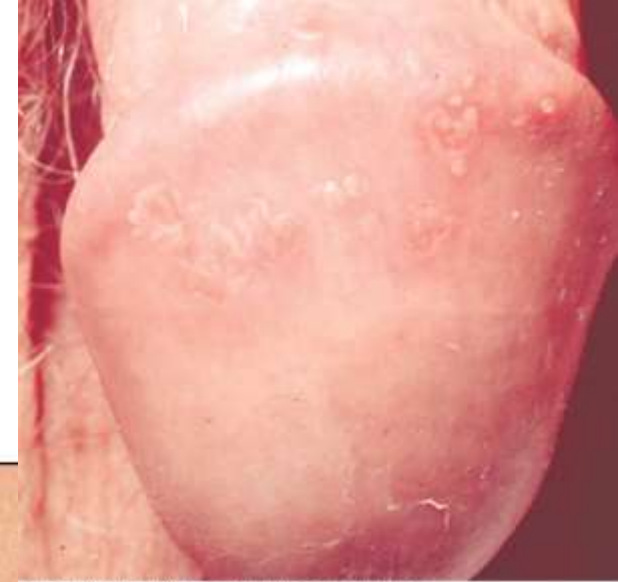
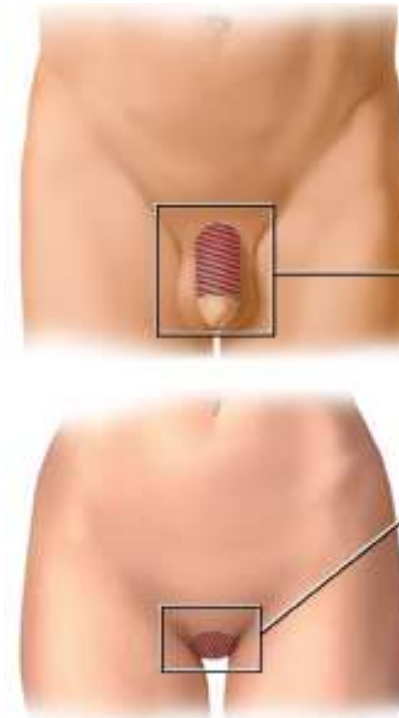


# Ulcerative genital infections / Genital herpes / pathophysiology



## Ulcerative genital infections / Genital herpes/ signs and symptoms

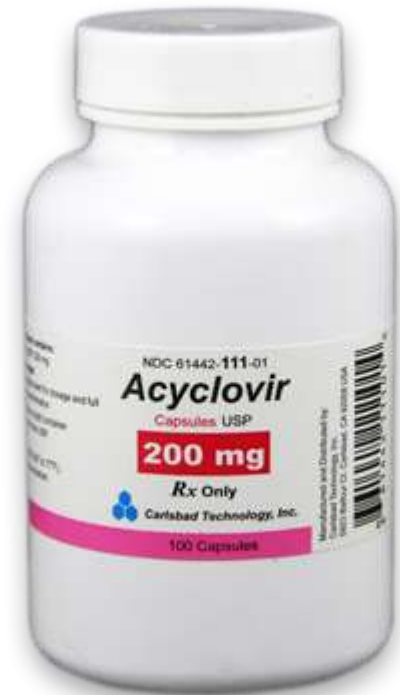- A visible outbreak consists of **single or clustered vesicles** on the genitalia that **ulcerate before resolving**.
- Primary infections may cause malaise, fever, or localized adenopathy, **Subsequent outbreaks are usually milder** and are caused by reactivation of latent virus.
- Patients with HSV-1 infection average zero to one recurrence per year, whereas **HSV-2 recurs four to five times annually**
- **Asymptomatic viral shedding** is common, occurring on 10% to 20% of all days, and facilitates viral transmission.



Herpes lesion:  
Found on shaft of penis (male),  
vagina, vulva, cervix (female),  
and around anus

## Ulcerative genital infections / Genital herpes/ Diagnosis and treatment

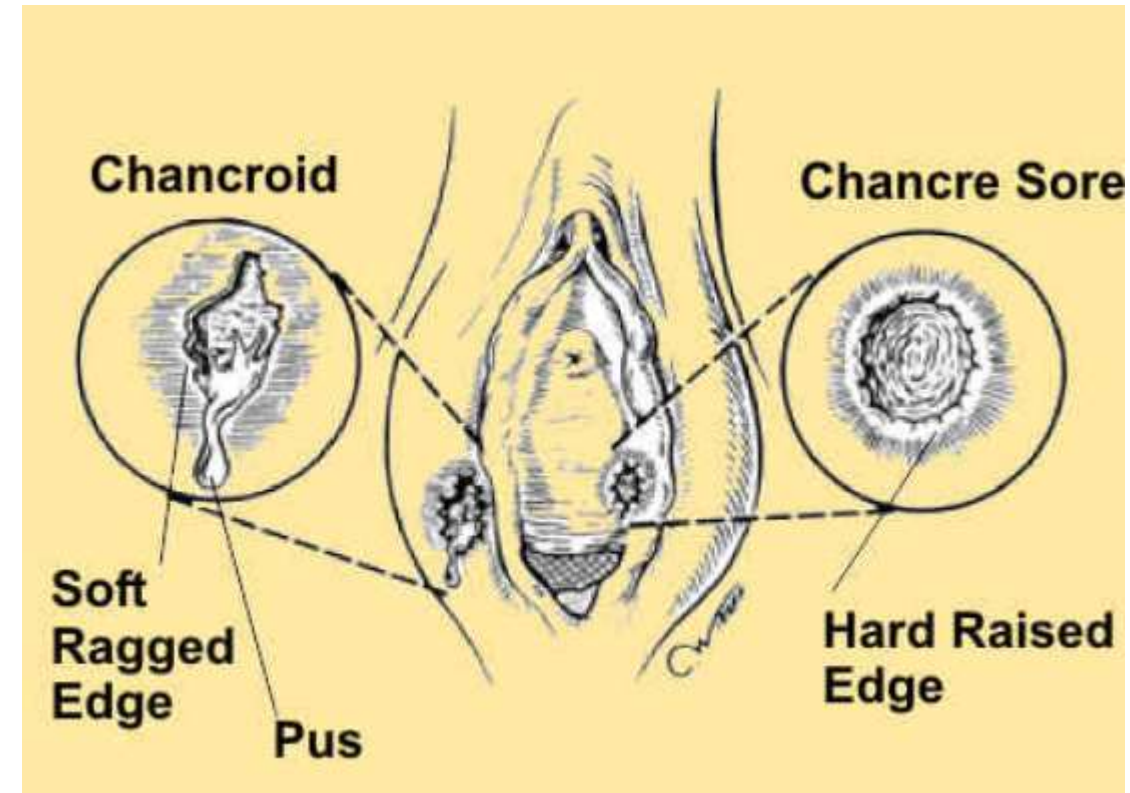
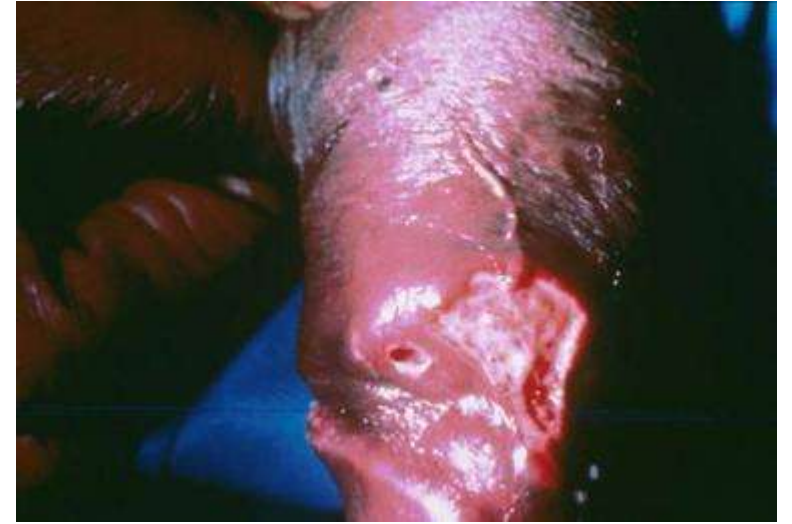- **Viral culture** from vesicular fluid and ulcerated lesions are useful for definitive diagnosis
- **PCR- based viral detection** is rapid and specific. And so is **Viral antigen detection**.
- **Systemic antiviral drugs** especially **acyclovir, valacyclovir, and famciclovir** can partially control the signs and symptoms of genital herpes when used to treat first clinical and recurrent episodes or when used as daily suppressive therapy.
- These drugs **do not eradicate latent virus** nor affect the risk, frequency, or severity of recurrences after the drug is **discontinued**.
- **Symptomatic treatment**— saline bathing, analgesia, and topical local anaesthetic agents (e.g. 5% lidocaine) ointment for painful micturition.



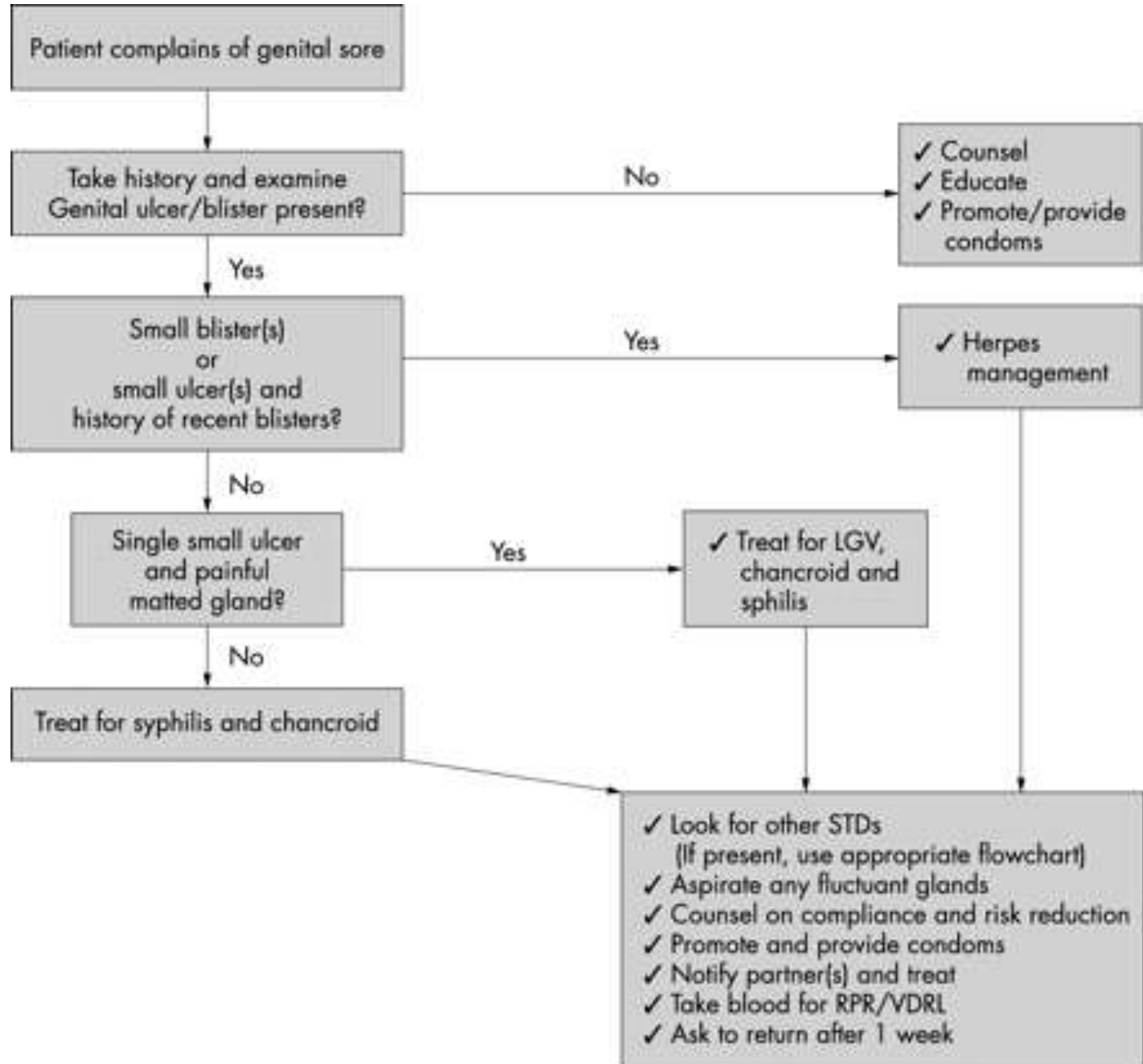






## Ulcerative genital infections / Chancroid

- Chancroid is a sexually transmitted disease (STD) caused by the Gram negative bacterium **Haemophilus ducreyi** and is characterised by **necrotising genital ulceration**
- Painful, erythematous papules develop on the external genitalia develop into pustules, and then erode into **sloughy, non-indurated haemorrhagic ulcers**
- Single dose oral **azithromycin** or **ciprofloxacin** and intramuscular **ceftriaxone** regimens offer advantages in terms of improved patient compliance.



- WHO recommended syndromic management for genital ulceration includes therapy for both chancroid and syphilis.

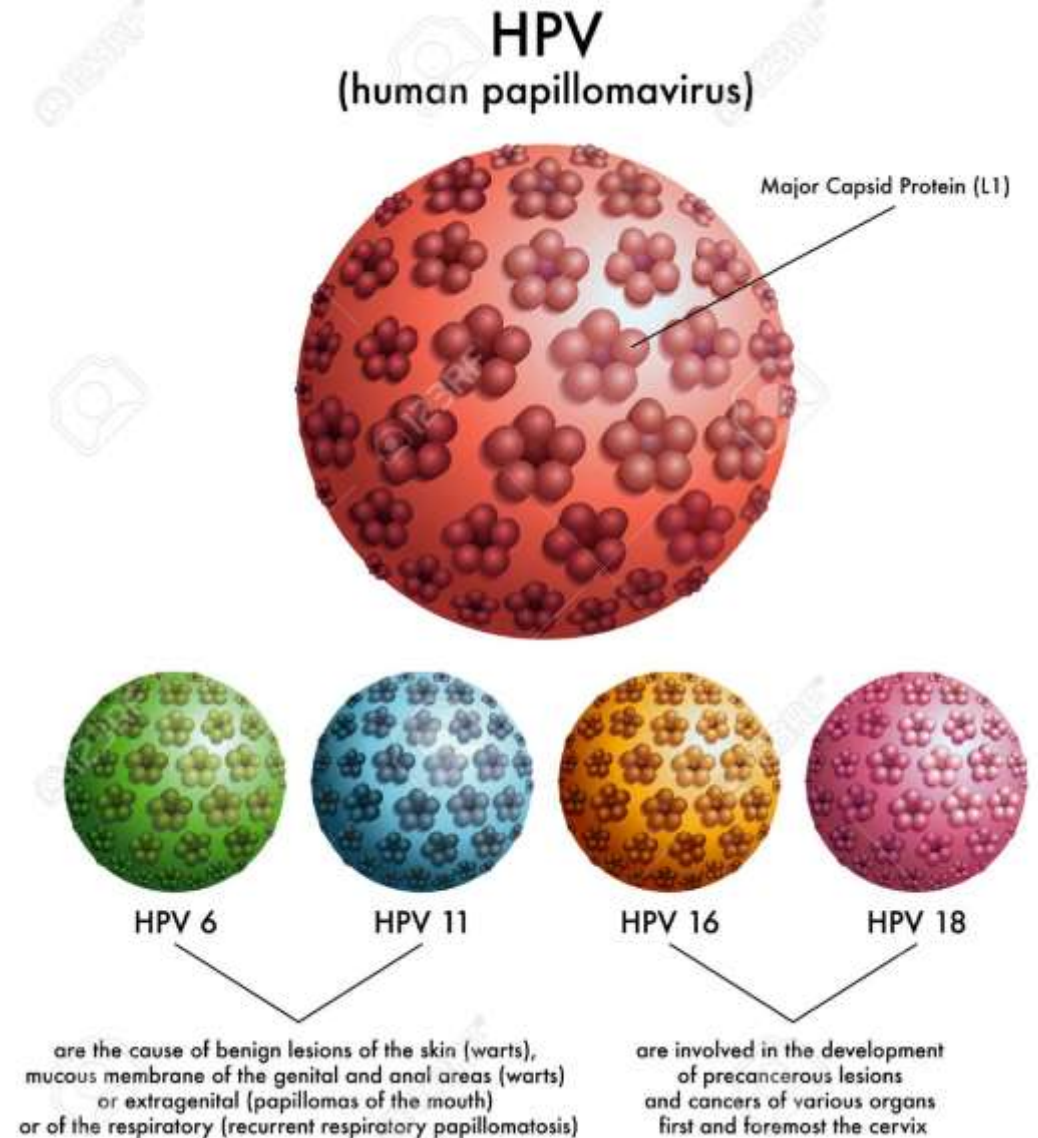


	Genital Herpes	Primary Syphilis	Chancroid	LGV
				
<b>Diagnostic clue</b>	Painful, vesicular lesions --> multi-superficial ulcer	Painless, indurated border	Extremely painful deep ulceration, ragged undermined edge	painless ulcer, heal within a few days " Groove sign "
<b>Treatment</b>	Acyclovir	Benzathine pen G <i>alternative</i> Doxycycline Tetracycline Erythromycin	Ceftriaxone Ciprofloxacin Erythromycin Azithromycin	Doxycycline Erythromycin



## Genital warts/ etiology and epidemiology

- Genital warts are a **sexually transmitted infection** caused by certain types of **human papillomavirus (HPV)**
- Genital warts are a common cause of morbidity, with estimates of up to 50% of the population HPV at some point in their lifetime
- **90% of cases** are related to **HPV subtypes 6 and 11**.
- **HPV Subtypes 16 and 18** are associated with **squamous cell carcinoma**.
- **Women** tend to be affected **more than men** in most settings.



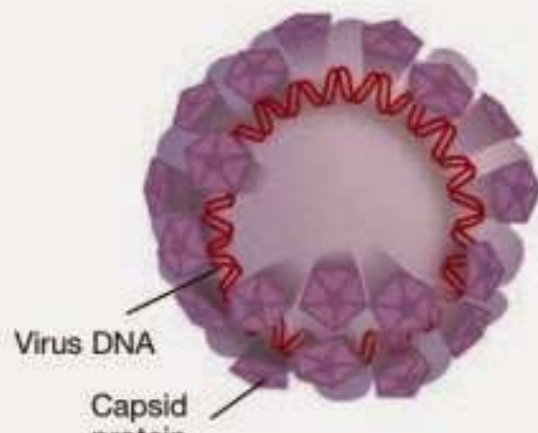


Histopathologically, the hallmark of an HPV-infected cell is the development of morphologically **atypical keratinocytes known as koilocytes**. These are enlarged cells with eccentric, pyknotic nuclei that are often surrounded by a perinuclear halo

## HPV – human papilloma virus

HPV has a circular, double stranded DNA, protected by capsid proteins.

More than 100 HPV-types are known. HPV16 and 18 cause 70% of all cervix cancers.



Virus DNA  
Capsid protein

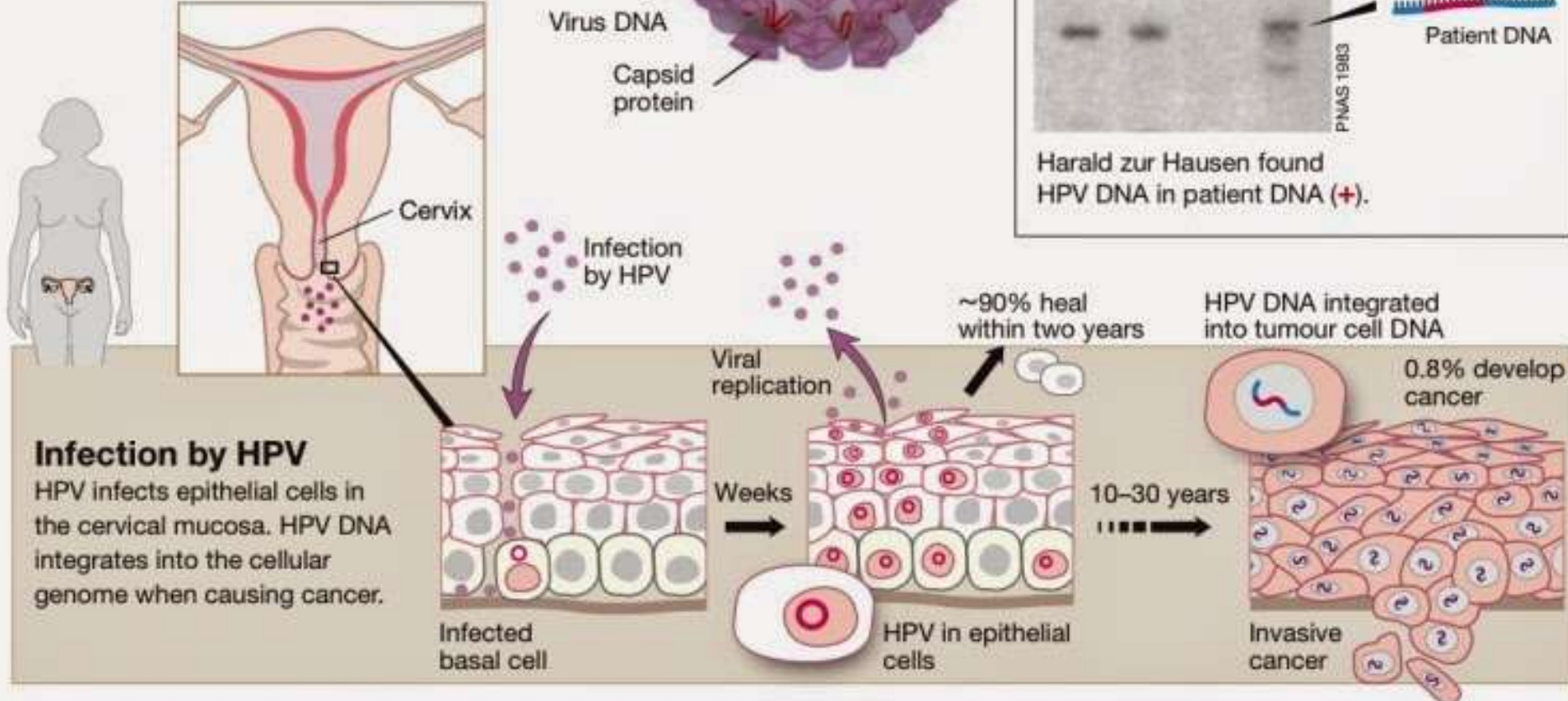
### Discovery of HPV DNA in cancer cells

1	2	3	4
+	+	-	+

Probe for HPV DNA  
Patient DNA

PNAS 1983

Harald zur Hausen found HPV DNA in patient DNA (+).



Infection by HPV

Cervix

Infection by HPV

HPV DNA integrates into tumour cell DNA

~90% heal within two years

0.8% develop cancer

Invasive cancer

10-30 years

Weeks

Viral replication

HPV in epithelial cells

Infected basal cell

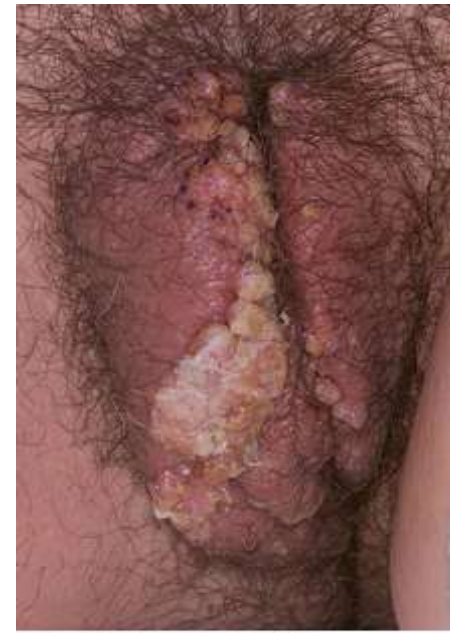### Infection by HPV

HPV infects epithelial cells in the cervical mucosa. HPV DNA integrates into the cellular genome when causing cancer.

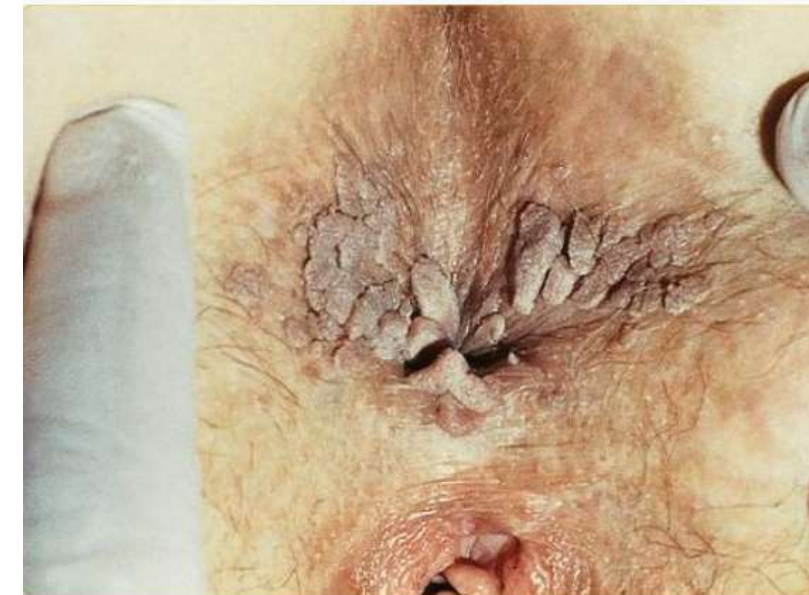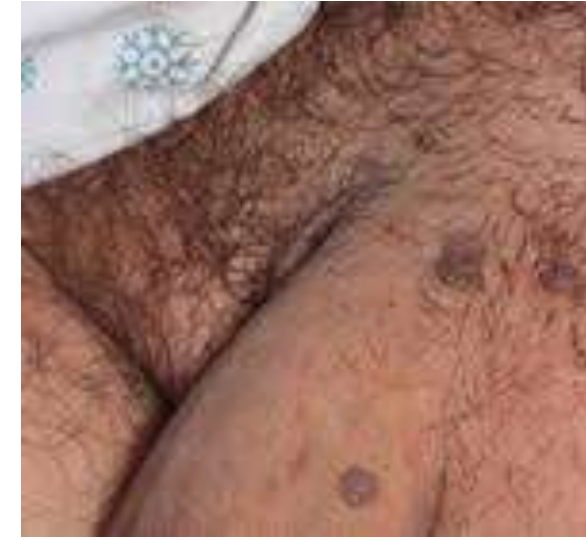© The Nobel Committee for Physiology or Medicine 2008 Illustration: Annika Röhl

## Genital warts/ Signs and symptoms

- On average, physical symptoms begin approximately 2 to 3 months after initial contact, Many studies estimate the rate of **subclinical** HPV infection to be as high as **40%**
- Approximately 30 percent of all warts will regress within the first four months of infection.
- Significant risk factors for long-term wart **persistence** include host **immunosuppression**, infection with **high-risk HPV subtypes**, and an **older patient age**
- Lesions are **rarely** considered to be **painful**; however, they are **often** associated with severe **discomfort, burning, and pruritis**



Female genital warts

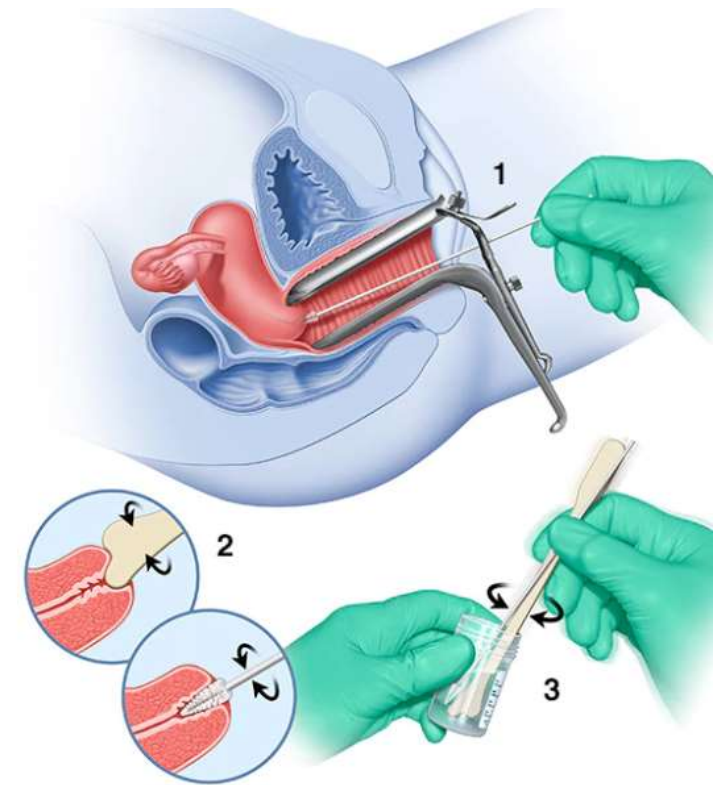


Severe case of genital warts around the anus of a female



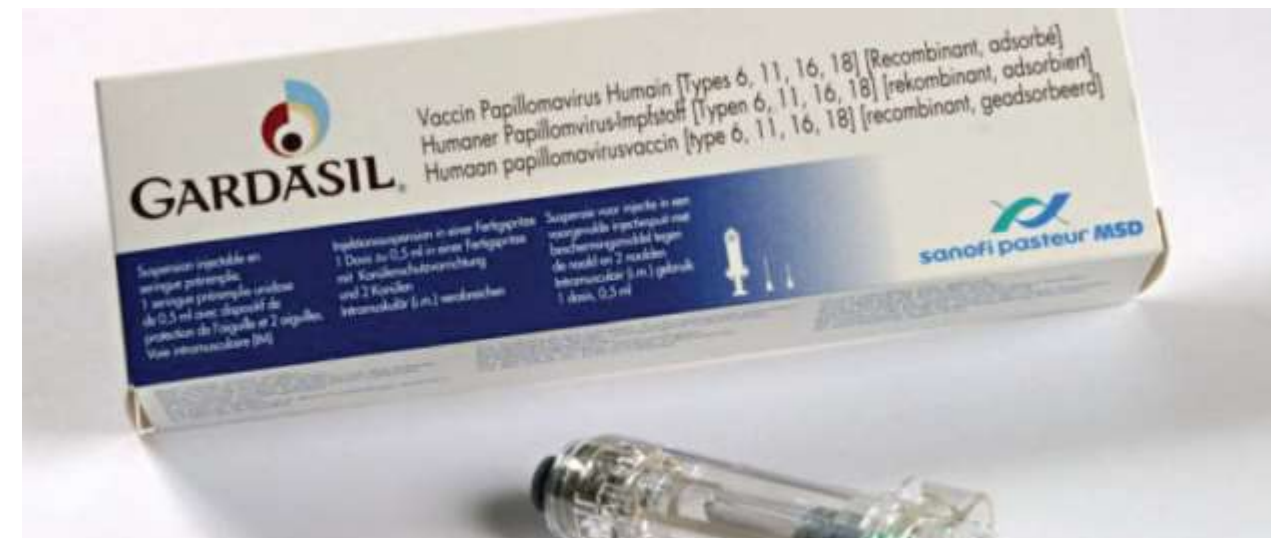## Genital warts/ prevention

- A **vaccine** known as Gardasil protects against four strains of HPV that cause cancer, and is used to prevent genital warts
- These vaccines are most effective if given to children **before they become sexually active**
- **Pap tests**, can help **detect vaginal and cervical changes** caused by genital warts or the early signs of cervical cancer

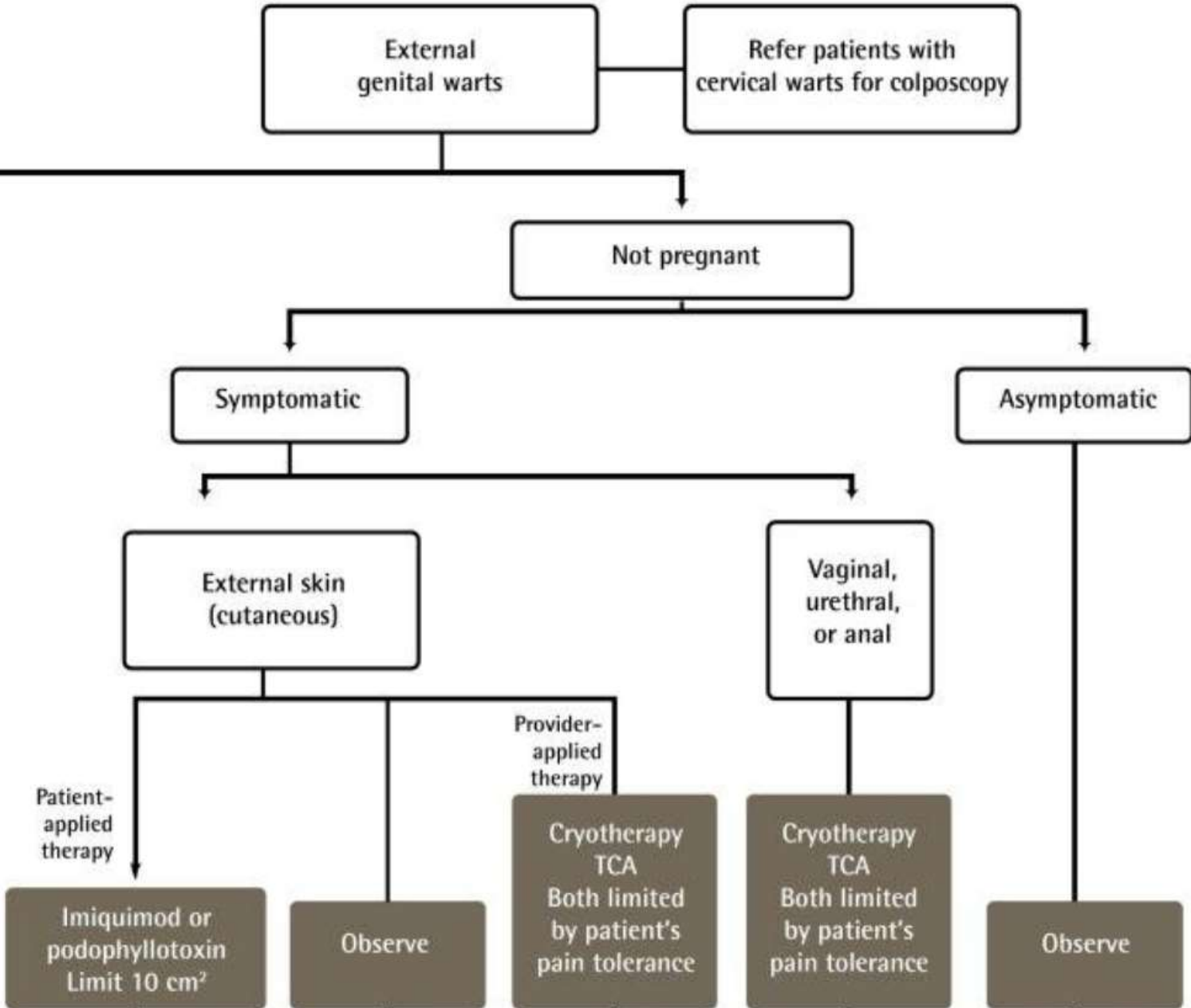


© MAYO FOUNDATION FOR MEDICAL EDUCATION AND RESEARCH. ALL RIGHTS RESERVED.

Pap test



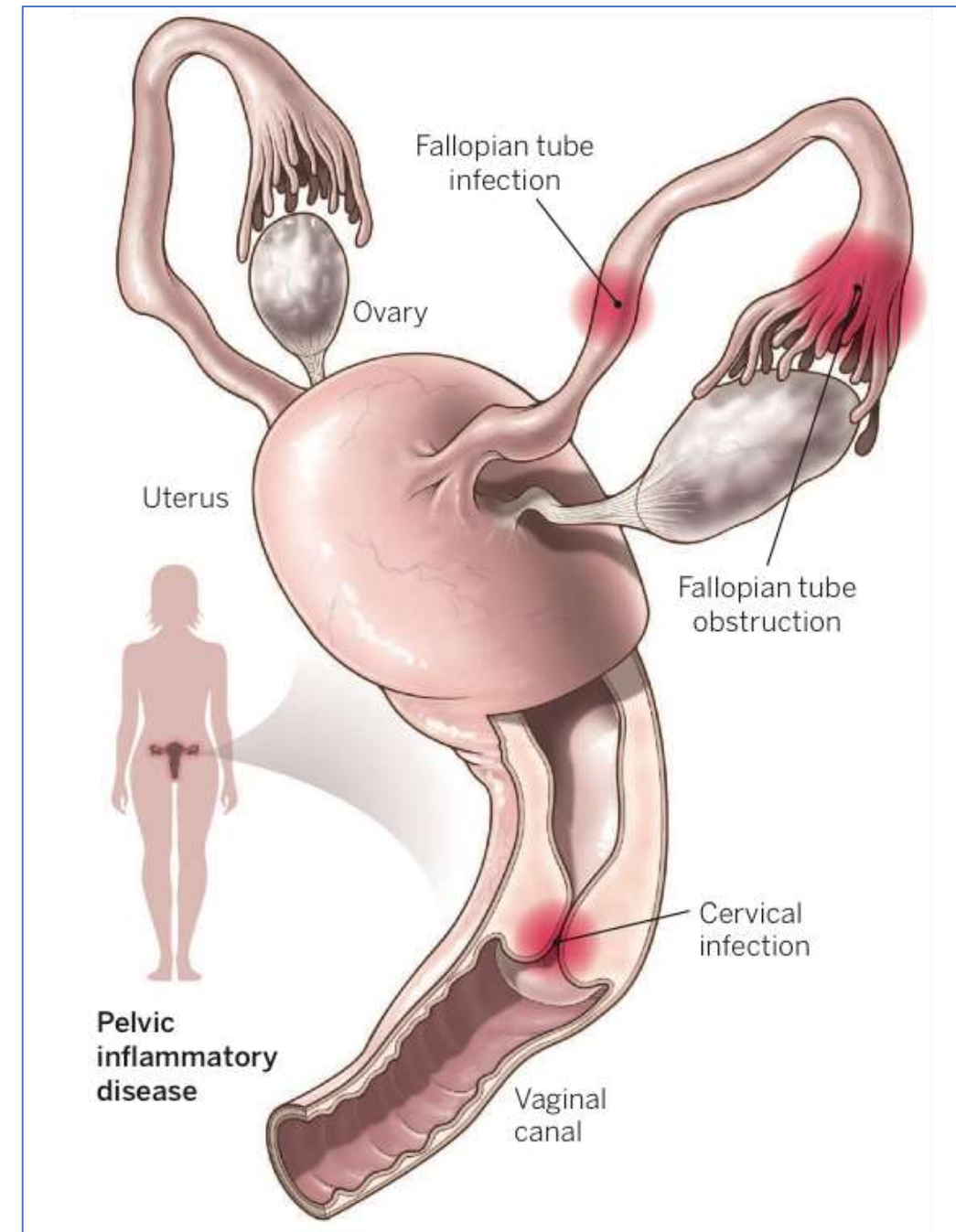
Genital warts/ treatment





## Pelvic inflammatory disease (PID)

- The term pelvic inflammatory disease usually refers to **infection** that ascends from the cervix or vagina to involve the **endometrium** and/ or **fallopian tubes** and **ovaries**.
- Infection can extend beyond the reproductive tract to cause **peritonitis** and **pelvic abscess**.
- Other than primary infections from STDs, infection can also be **secondary** to invasive **intrauterine surgical procedures** (e.g. termination of pregnancy).
- Rarely, infection is not related to specific sexually transmitted pathogens, and originates from **another focus of infection**.



## Pelvic inflammatory disease (PID)

**Table 1. Clinical Classification of Pelvic Inflammatory Disease and Likely Microbial Causes.**

### Clinical Syndrome

### Causes

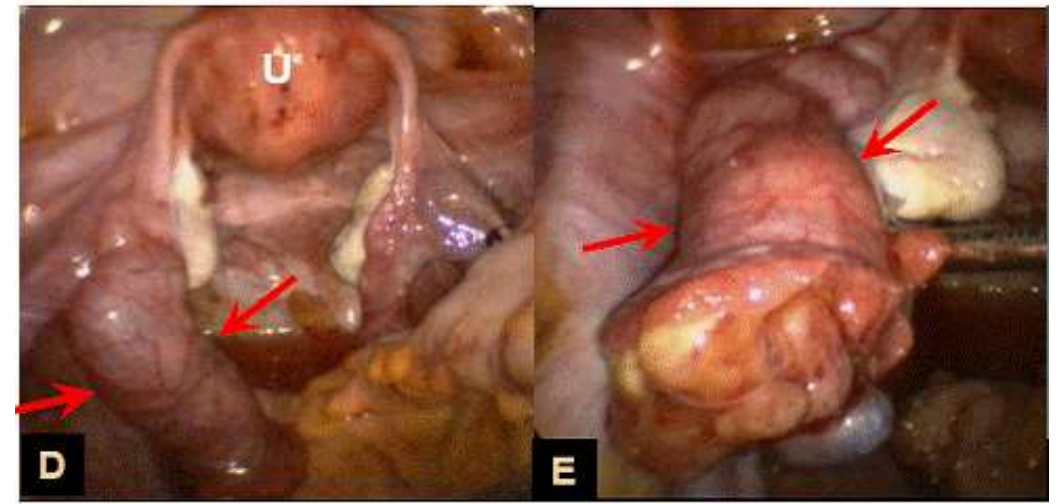
Acute pelvic inflammatory disease (≤30 days' duration)	Cervical pathogens ( <i>Neisseria gonorrhoeae</i> , <i>Chlamydia trachomatis</i> , and <i>Mycoplasma genitalium</i> ) Bacterial vaginosis pathogens (peptostreptococcus species, bacteroides species, atopobium species, leptotrichia species, <i>M. hominis</i> , <i>Ureaplasma urealyticum</i> , and clostridia species) Respiratory pathogens ( <i>Haemophilus influenzae</i> , <i>Streptococcus pneumoniae</i> , group A streptococci, and <i>Staphylococcus aureus</i> ) Enteric pathogens ( <i>Escherichia coli</i> , <i>Bacteroides fragilis</i> , group B streptococci, and campylobacter species)
Subclinical pelvic inflammatory disease	<i>C. trachomatis</i> and <i>N. gonorrhoeae</i>
Chronic pelvic inflammatory disease (>30 days' duration)	<i>Mycobacterium tuberculosis</i> and actinomyces species

## Pelvic inflammatory disease/ Signs and symptoms

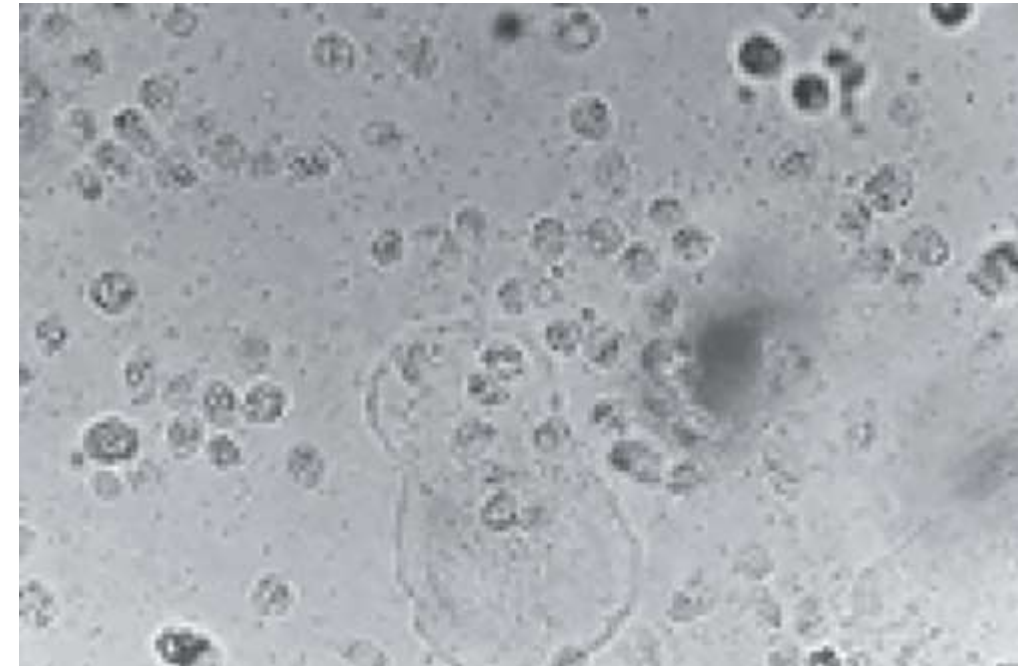
- The hallmark of the diagnosis is **pelvic tenderness** (cervical motion tenderness, adnexal tenderness, or uterine compression tenderness) combined with **inflammation of the lower genital tract**; women with pelvic inflammatory disease often have **very subtle** symptoms and signs
- **Fever** can occur, but systemic manifestations are **not a prominent feature** of PID.
- The abrupt **onset** of severe lower abdominal pain **during or shortly after menses** has been the classic symptom used to identify acute PID.
- Clinical diagnosis is **often imprecise** and more tests are needed to confirm diagnosis.

## Pelvic inflammatory disease/ Diagnosis

- Although **laparoscopy** has been considered the standard for the diagnosis of pelvic inflammatory disease, it has high interobserver variability and is invasive.
- Transcervical endometrial aspiration with **histopathological findings** of increased WBCs is more commonly used to confirm the diagnosis of pelvic inflammatory disease
- **MRI** has high sensitivity, reveals thickened, fluid-filled tubes
- All patients with suspected PID should undergo cervical or vaginal **NAATs** for *N. gonorrhoeae* and *C. trachomatis* infection



Laparoscopy image and close-up image of same patient show sausage-shape dilated right fallopian tube (arrow)

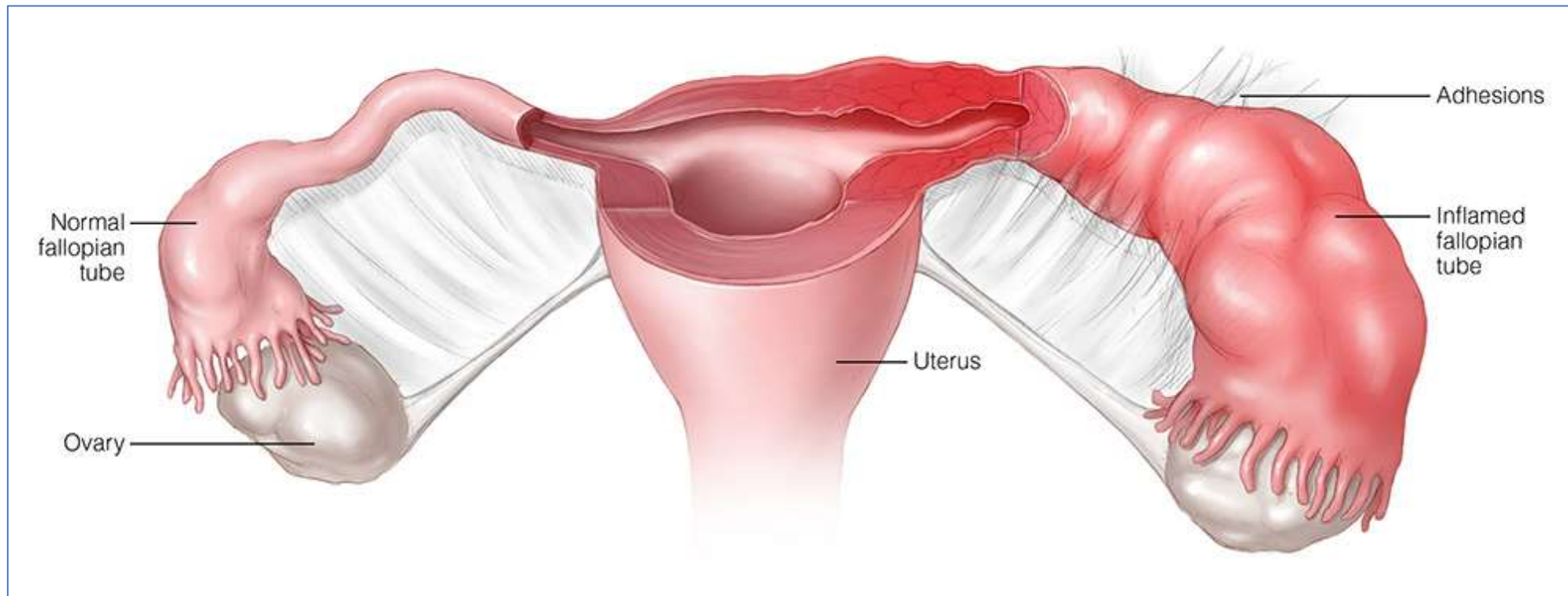


increased numbers of white cells ( $\geq 1$  per vaginal epithelial cell)



## Pelvic inflammatory disease/ Sequelae

- Infection results in **fibrinous** or suppurative **inflammatory damage** along the epithelial surface of the fallopian tubes and the peritoneal surface of the fallopian tubes and ovaries, which leads to **scarring, adhesions**, and possibly partial or total **obstruction of the fallopian tubes**
- Can result in long-term reproductive disability, including **infertility, ectopic pregnancy**, and **chronic pelvic pain**.



- The treatment of pelvic inflammatory disease is **empirical** and involves the use of **broad-spectrum combination** regimens of antimicrobial agents to cover likely pathogens.

**Table 2.** First-Line Antimicrobial Treatment Recommended by the Centers for Disease Control and Prevention (CDC) for Pelvic Inflammatory Disease.\*

**Outpatient regimen for mild-to-moderate pelvic inflammatory disease**

Doxycycline (100 mg orally twice daily for 2 wk) with or without metronidazole (500 mg orally twice daily for 2 wk), plus one of the following:

Ceftriaxone (250 mg intramuscularly in a single dose)

Cefoxitin (2 g intramuscularly) with probenecid (1 g orally) concurrently in a single dose

Other parenteral third-generation cephalosporin (cefotaxime or ceftizoxime)

**Inpatient regimen for moderate-to-severe pelvic inflammatory disease with or without tubo-ovarian abscess†**

One of the following:

Cefotetan (2 g intravenously every 12 hr) plus doxycycline (100 mg orally or intravenously every 12 hr)

Cefoxitin (2 g intravenously every 6 hr) plus doxycycline (100 mg orally or intravenously every 12 hr)

Clindamycin (900 mg intravenously every 8 hr) plus gentamicin (3 to 5 mg per kilogram of body weight intravenously once daily)

\* Complete treatment information, including alternative regimens and additional considerations, is available at the CDC website.<sup>33</sup>

† Transition to oral therapy can usually be initiated within 24 to 48 hours after clinical improvement, and oral therapy should be continued to complete 2 weeks of therapy.

## Further reading:

- Oxford handbook of infectious diseases and microbiology-  
Part4: Clinical syndroms  
Chapter 18: Sexually transmitted infections
- Harrison's Infectious Diseases 3rd Edition  
SECTION III Infections in organ systems  
Chapter 35