

بِسْمِ اللَّهِ الرَّحْمَنِ الرَّحِيمِ

اللَّهُمَّ أَنْتَ رَبِّي لَا إِلَهَ إِلَّا أَنْتَ، خَلَقْتَنِي وَأَنَا عَبْدُكَ، وَأَنَا عَلَى عَهْدِكَ وَوَعْدِكَ مَا اسْتَطَعْتُ، أَعُوذُ بِكَ مِنْ شَرِّ مَا صَنَعْتُ، أَبُوءُ لَكَ بِنِعْمَتِكَ عَلَيَّ، وَأَبُوءُ لَكَ بِدَنِّي، فَاعْفُ لِي؛ فَإِنَّهُ لَا يَغْفِرُ الذُّنُوبَ إِلَّا أَنْتَ .

بالتوفيق أطباء المستقبل، لا تنسونا من الدعاء.

OSCE CHECKLISTS

MADE BY: AHMAD ALKAFWEEN

General

Respiratory

Cardiovascular

Gastrointestinal

Nervous

Musculoskeletal

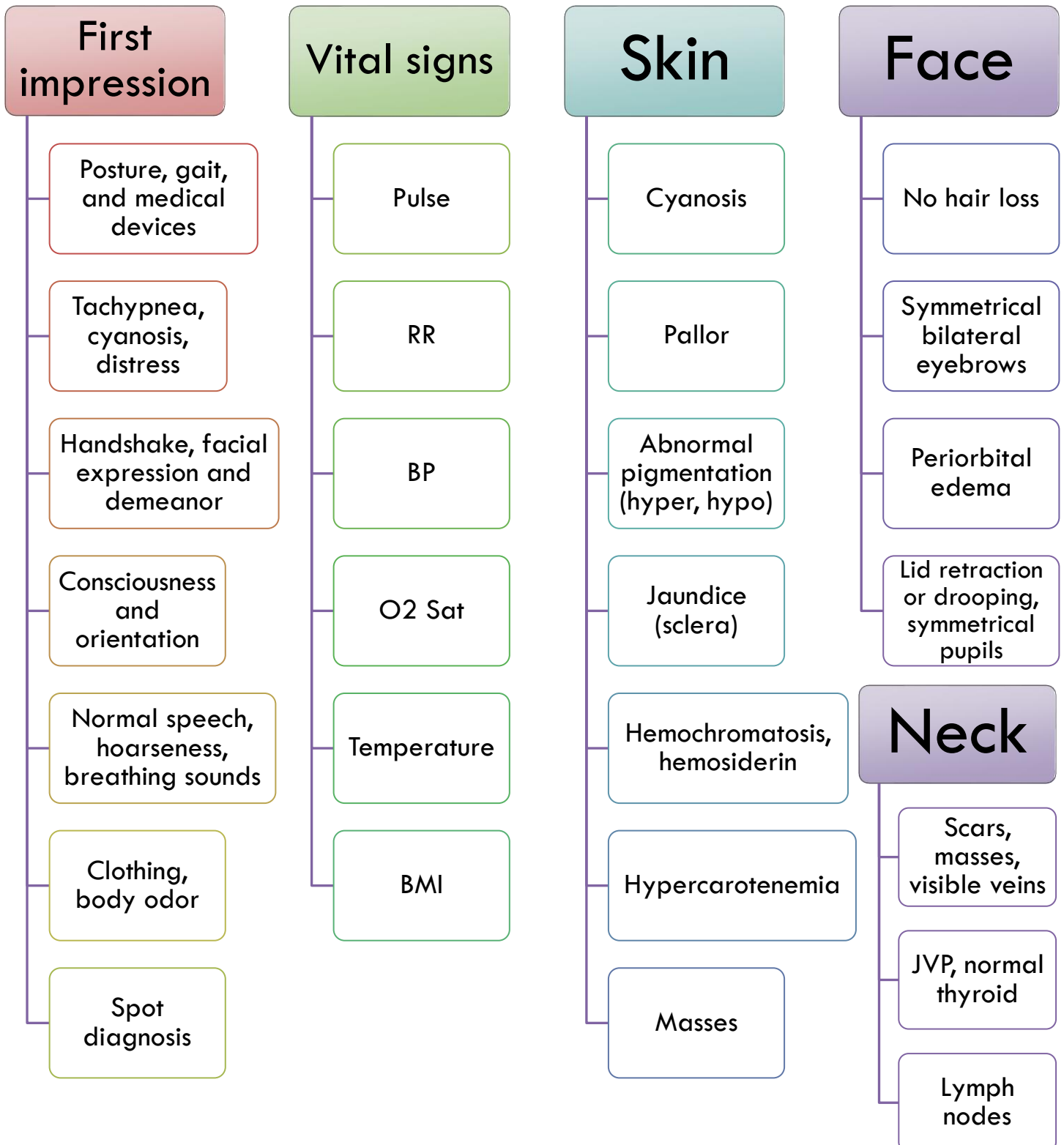
Thyroid

GENERAL EXAMINATION

Keep this list in mind when examining systems.

Introduce yourself, ask for **permission**, ask for a **chaperone**, **wash your hands**, and check **privacy**, **illumination**, and **warmth**. Ask for **exposure** and **position** the patient. Always **stand at the right bedside**.

Inspection general rules: Don't touch the patient, look from all angles (rotate your head around the patient).



Palpation general rules: Ask for permission to put your hands on the patient, **ask for any area of pain & examine it last**, wash your hands, warm your hands up & **maintain eye-to-eye** contact throughout the examination.

Hands examination (More advanced later on): remember to examine both hands, comment on trauma, **tremors (fine, flapping, resting)**, cyanosis, myotonic dystrophy or muscle weakness, look for needle puncture marks.

Dorsum	Palm	Nails	Palpation
<ul style="list-style-type: none"> • Swelling • Scars • Finger count • Deformities (Arachnodactyly, ulnar deviation, arthritis) • Tar staining 	<ul style="list-style-type: none"> • Swelling • Scars • Erythema • Single palmar crease • Pigmentation • Deformities (Dupuytren's) • Muscle wasting 	<ul style="list-style-type: none"> • Cyanosis, capillary refill • Abnormalities (Spoonings, Clubbing, Beau's lines, leuconychia, Lindsay's, Muehrcke's, Telangiectasia, Onycholysis, Onychomycosis, Pitting, Splinter hemorrhages, Yellow nails.) 	<ul style="list-style-type: none"> • Tenderness, masses, skin texture • Temperature • Tendons and joints

Clubbing (Schamroth's window, hyponychial angle, angle depth vs DIP joint depth, nail bed fluctuation.)

Face and neck and lumps examination:

Tongue	Lymph nodes	Hydration	Lump
<ul style="list-style-type: none"> • Central cyanosis • Glossitis (smooth) • Deviation • Wasting • Tremor, fasciculation • Macroglossia • Masses • Tongue furring • Geographic tongue 	<ul style="list-style-type: none"> • *Cervical LN* • Test from behind: Submental, submandibular, preauricular, tonsillar, deep cervical, supraclavicular, scalene. • From front: Posterior auricular, occipital, deep cervical. • Axillary LN: Apical, medial, lateral, anterior and posterior. (examine with your opposite arm) • Epitrochlear LN (same arm) 	<ul style="list-style-type: none"> • Sunken eyes • Dry mucous membranes • Skin turgor • JVP • Axilla sweat • Ankle edema (mobile patient), sacral edema (bedridden) 	<ul style="list-style-type: none"> • SPACESPIT • Size • Position • Attachment • Consistency • Edge (demarcation) • Shape and surface • Palpations, thrills, bruits • Inflammation (Redness, tenderness, warmth) • Transillumination

RS EXAMINATION

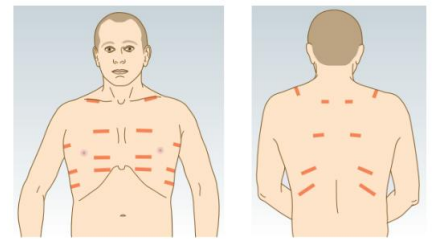
Setting	First impression	Vitals	Hands	Face
<ul style="list-style-type: none"> • Introduce yourself, ask for permission, chaperone • Check privacy, illumination, warmth • Wash your hands • Exposure above the waist • Patient semi-recumbent (45°) • Position yourself (foot of the bed, right bedside) 	<ul style="list-style-type: none"> • Consciousness and orientation. • Patient position (Tripod) • Medical devices. • Respiratory distress (tachypnea, cyanosis, nasal flaring, pursed lips, barrel chest, indrawing of intercostals, accessory muscles) • Breathless, in pain • Breath sounds (wheeze, stridor, hoarseness) • Breath smell (smoke, alcohol) 	<ul style="list-style-type: none"> • Pulse • BP (pulsus paradoxus) • RR • O2 Sat • Temperature • BMI 	<ul style="list-style-type: none"> • Temperature, Sweat • Erythema • Muscle wasting • Nails (yellow nails, clubbing) • Tar staining • Cyanosis • Wrist tenderness (hypertrophic pulmonary osteoarthropathy) • Tremors (fine, coarse (flapping)) 	<ul style="list-style-type: none"> • Central cyanosis (tongue) • Conjunctival pallor, edema • Horner's syndrome (lid drooping, symmetrical pupils, anhidrosis) • Plethora • Swelling <ul style="list-style-type: none"> • Neck • Visible masses, scars, veins • JVP, lymph nodes

Chest examination notes: Stay away from the midline, remember the apex of the lung and test 3 intercostal areas anteriorly and 3 **laterally**. Always test symmetry. Mention your location in relation to patient BED.

CHEST EXAMINATION

Anterior chest exam: Semi-recumbent position & exposure above the waist.

Inspection: Foot of the **BED** (**breathing, expansion, deformities**)



Breathing pattern	Expansion	Deformities
<ul style="list-style-type: none"> • Thoracoabdominal, abdominothoracic • No abnormalities (tachypnea, kussmaul, cheyne-stokes) 	<ul style="list-style-type: none"> • "Chest moves with respiration, symmetric" 	<ul style="list-style-type: none"> • "The chest is symmetrical elliptical in cross-section, no pectus excavatum, no pectus carinatum, no kyphosis, no scoliosis, no barrel chest"

From the **right side** of the bed:

Accessory muscle use, indrawing of intercostals	Visible scars, masses, veins	Hair distribution	Nipples and skin lesions	Audible sounds of breathing (Stridor, wheeze, hoarseness)
---	------------------------------	-------------------	--------------------------	---

Palpation: Ask for permission, ask for any area of pain & examine it last, warm your hands & maintain **eye-to-eye contact** throughout the examination.

Superficial palpation <ul style="list-style-type: none"> •Tenderness •Subcutaneous /Superficial nodules •Subcutaneous emphysema 	Mediastinal deviation <ul style="list-style-type: none"> •Tracheal deviation •Cricosternal distance •Tracheal tug •“Trachea centrally located, cricosternal distance 4 cm and no tracheal tug.” 	Locate apex beat <ul style="list-style-type: none"> •First locate beat roughly then specifically •Apex beat in left 5th ICS in midclavicular line, gently tapping (describe beat) 	Chest expansion <ul style="list-style-type: none"> •Symmetry and distance •“Symmetrical bilateral chest expansion with thumbs 5 cm apart.” 	TVF <ul style="list-style-type: none"> •Symmetrical bilateral TVF all over the chest
				RV or LV heave

Percussion: Stay away from the midline, compare sides. If normal, comment: “Symmetrical bilateral resonant percussion note all over the chest.”. And comment on the location of liver dullness; normally “upper edge of liver dullness in right fifth intercostal space, at MCL.”

Auscultation: Use stethoscope **diaphragm &** warm it, compare symmetry, stay away from midline.

Breathing sounds <ul style="list-style-type: none"> • Vesicular or bronchial • “Symmetrical bilateral vesicular breathing sound, good air entry bilaterally.” • “No wheeze. No crackles. No pleural friction rubs. No clicks.” 	Vocal resonance <ul style="list-style-type: none"> • “Symmetrical bilateral vocal resonance” • Consolidation signs: • Aegophony • Whispering pectoriloquy
---	--

Posterior chest exam: Position the patient sitting upright, exposed above the waist, **hands crossed anteriorly** to pull the scapulas away from midline.

Inspection: Foot of BED Expansion <ul style="list-style-type: none"> •“Chest moves with respiration, symmetric” 	Deformities <ul style="list-style-type: none"> •“The chest is symmetrical elliptical in cross-section, no deformities”
--	---

Right side of bed:

Visible scars, masses, veins	Hair distribution	Skin lesions	Audible sounds of breathing (Stridor, wheeze, hoarseness)
------------------------------	-------------------	--------------	---

Palpation:

Superficial palpation <ul style="list-style-type: none"> •Tenderness •Subcutaneous/Superficial nodules •Subcutaneous emphysema 	Mediastinal deviation <ul style="list-style-type: none"> •Tracheal deviation •Cricosternal distance •Tracheal tug •“Trachea centrally located, cricosternal distance 4 cm and no tracheal tug.” 	Chest expansion <ul style="list-style-type: none"> •Symmetry and distance •“Symmetrical bilateral chest expansion with thumbs 5 cm apart.” 	TVF <ul style="list-style-type: none"> •Symmetrical bilateral TVF all over the chest
---	---	--	---

Percussion: Same anterior comment and do **diaphragmatic excursion** on each side (normally 5-8 cm).

Auscultation: Same for anterior.

Say last: “I’d like to run an **ENT examination for the upper airways and examine the abdomen for hepatosplenomegaly, and check for limb edema or swelling and erythema nodosum**”.

CVS EXAMINATION

Setting

- Introduce yourself, ask for **permission**, ask for a **chaperone**
- Check **privacy, illumination, warmth**
- Wash your hands and warm them
- **Position** the patient (45°) and yourself
- **Exposure** above the waist

First impression

- Consciousness, orientation (place, person, time)
- Patient position, medical devices
- Distress or anxiety
- Breathless, cyanotic
- Overweight, cachectic
- Pallor, jaundice
- Hoarseness, Horner's syndrome
- Breath smell (alcohol, smoke)
- Check for petechiae and mention urinalysis

Vitals

- **Pulse** (see down)
- **BP (Pulsus paradoxus & postural hypotension)**
- RR
- O₂ sat
- Temperature
- BMI

Face

- Xanthelasmas
- Corneal arcus
- Conjunctival pallor or petechial hemorrhage
- Jaundice on sclera
- Malar flush
- Cyanosis (central, peripheral)
- Glossitis and angular stomatitis, dental carries.
- Finish with: "I need fundoscopy to look for DM or HTN retinopathy and Roth spots."
- **Check the NECK for visible masses, scars, veins**

Hands

- **Inspection**
- Tremor (Fine, flapping)
- Needle puncture marks or tracks
- Nails (clubbing, splinter hemorrhage), tobacco staining, cyanosis
- Dorsum > Tendon xanthoma, petechial rash
- Palm > Erythema, crease pallor, Osler nodes & Janeway lesions
- **Palpation**
- Temperature, wet/dry
- Capillary refill time

Pulses, for radial say: "Normal volume and character, though it is better to be assessed in a larger artery"

Common to all

- Rate
- Rhythm
- Volume
- Character (slow rising, collapsing, pulsus bisferiens, pulsus alternans)
- Compressibility

Radial

- **CPR:**
- **Collapsing pulse** (ask for shoulder pain)
- **Pulse deficit**
- **Radio-radial delay**
- **Radio-femoral delay**

Other pulses

- Brachial (arm semi-flexed)
- Carotid (Check bruits by auscultation with diaphragm while the patient is holding his breath)

Say "I'll examine the femoral, popliteal, posterior tibial and dorsalis pedis arteries."

JVP exam, **measure the height (ruler measurement + 5 cm)** after you do these:

General	Inspection	Palpation	Maneuvers
<ul style="list-style-type: none"> Stand to the right of the patient Semirecumbent position Rest his head on a pillow and turn it to the left 	<ul style="list-style-type: none"> Use your torch Inward movement Two peaks per heartbeat 	<ul style="list-style-type: none"> Impalpable Compression at the root of the neck obliterates it 	<ul style="list-style-type: none"> Decreases with inspiration Increases with lying flat Abdominojugular reflux

Comment: **“By inspection**, an inward double waved venous pulse was detected. The venous pulse decreases on inspiration and disappears on sitting upright. **By palpation**, the venous pulse is not palpable, disappears with neck root compression, and increases with abdomino-jugular reflux. **Measured as 9 cm water.**”

Precordium examination: exposure above the waist, position lying at 45 degrees.

Inspection:

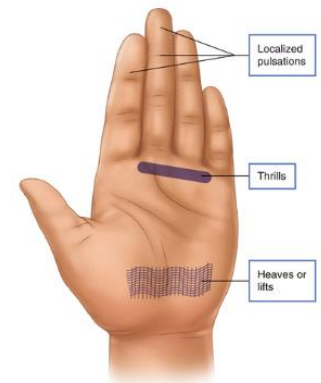
Foot of the BED
<ul style="list-style-type: none"> "Symmetrical bilateral chest moving with breathing." Deformity (excavatum, carinatum)

Right side
<ul style="list-style-type: none"> Hair distribution Scars, skin lesions and masses Dilated veins Visible pulsation (aneurysm) + look for apex beat (torch)

Palpation:

Remember **eye contact** and **asking about tender areas**, start by **checking for tenderness**.

Apex beat	Heave	Thrill
<ul style="list-style-type: none"> Position Character "Left 5th ICS, mid-clavicular line, localized, gently tapping" 	<ul style="list-style-type: none"> Ask patient to hold breath at expiration. Apex (LV) Left parasternal area (RV) 	<ul style="list-style-type: none"> Apex Left parasternal area Right parasternal area



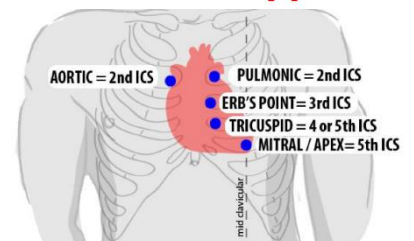
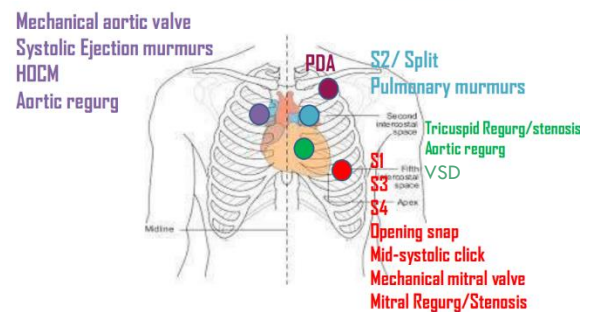
Auscultation: Palpate the carotid while auscultating. Warm the stethoscope.

- Auscultate the 4 valve areas with **diaphragm**, then listen with **bell** at **apex (Mitral stenosis)** and lower left sternal border (Tricuspid stenosis/regurgitation).

- Auscultate over the left axilla (Radiation of mitral regurgitation).
- Auscultate the carotid artery (Radiation of aortic stenosis).
- Auscultate below left clavicle (PDA).

- Roll the patient on his left side and auscultate the apex with the **bell** (Mitral stenosis). - Ask the patient to sit up, lean forward and hold breath in full expiration to auscultate Erb's point with **diaphragm** (Aortic regurgitation).

“Normal S1, S2. Normal S2 splitting. No S3, S4. No added sounds (opening snap, ejection click, midsystolic click, mechanical valves or friction rub). No murmurs.”



Say “I’ll complete my examination by auscultating the lungs’ bases for crackles and pleural effusion. I’ll auscultate for carotid bruit. And I’ll examine the abdomen for ascites and hepatosplenomegaly and sacral edema. I’ll examine lower limb for edema, ulcers, pulses. And I’ll examine JVP.”

PERIPHERAL VASCULAR EXAMINATION

General exam: (This checklist is a continuation to CVS checklist, refer to it for introduction, first impression, vitals, **pulses**)
Exposure up to umbilicus, but due to cultural concerns up to mid-thigh (Both legs).

Arterial system examination, remember to examine pulses and BP for both arms

Face and Neck

- Xanthelasma, corneal arcus
- Horner's syndrome (ptosis, miosis, anhidrosis)
- Hoarseness
- Visible veins in the neck, shoulders, anterior chest

Hands

- Tobacco stain
- Discoloration of fingertips
- Pits and healed scars in finger pulps
- Calcinosis and visible nail fold capillary loops
- Muscle wasting

Abdomen

- **Inspection:**
- Epigastric/umbilical pulsation
- Mottling
- Weight loss
- Scars
- **Palpation** for pulsatile mass over the aorta (epigastrium, below umbilicus)

Lower limbs examination: (Position: start flat then elevated 45 degrees and then dependent position) (Compare limbs)

Inspection

- Color changes, scars
- Hair distribution & shiny skin
- Swelling, ulcers
- Muscle wasting
- Superficial dilated veins
- Venous guttering
- Onycholysis and hypertrophic nails, clubbing
- Fungal infection between toes
- Look between toes (ulcers) and at heels (pressure sores)

Palpation

- Muscle tenderness
- Temperature difference
- Capillary refill (<2 seconds)
- **Pulses: (comment if palpable)**
- Femoral (Mid-inguinal point, halfway between the ASIS and pubic symphysis) (radio-femoral delay)
- Popliteal (lying flat, knee flexed 30 degrees)
- Posterior tibial (2 cm below and 2 cm behind the medial malleolus)
- Dorsalis pedis (lateral to tendon of extensor hallucis longus)

Auscultation & Special tests

- Bilateral auscultation over the femoral artery for bruits (using diaphragm, warm it)
- -----
- Buerger's test (patient supine)
- "To finish my exam I need to test the Ankle:brachial pressure index (ABPI)"

Venous system examination (DVT exam) > Patient standing then lying supine

Check if the patient is stable, breathless or in pain. Risk factors: pregnancy, immobility, cast, recent surgery or trauma.

Inspection

- Skin color changes (lipodermatosclerosis, hemosiderin)
- Ulcers
- Swelling
- Venous dilation

Palpation

- Temperature difference (≥ 3 sites)
- Tenderness of skin and muscle (squeeze ankle, calves and thighs)
- Pitting edema (if present > check JVP)
- Leg circumference (10 cm below tibial tuberosity) (<3 cm difference insignificant)

GI EXAMINATION

Setting	First impression	Hands	Face	
<ul style="list-style-type: none"> • Introduction, ask for permission and chaperone • Wash hands, ensure privacy, warmth and illumination • Exposure ideally from the nipples to mid-thigh but for cultural concerns exposure from the xiphisternum to symphysis pubis. • Position: lying flat with head rested on pillow 20° above horizontal, ask the patient to put hands by his side and stretch his legs. • To relax the abdominal muscles if tense, flex hip joint 45° and flex knee joint 90°. 	<ul style="list-style-type: none"> • Conscious, oriented (place, person, time) • Not in pain • Looks well • Cachectic or obese • Skin redundancy or striae • Vital signs <ul style="list-style-type: none"> • Pulse • BP • RR • O2 sat • Temperature • BMI, waist circumference, distribution of weight (truncal or generalized) 	<ul style="list-style-type: none"> • Nails (clubbing, koilonychia, leukonychia) • Tar stain • Dupuytren's contracture • Muscle wasting • Palmar erythema • Crease pallor • Fine and flapping tremors • Temperature • Arms: needle tracks, tattoo, paucity of axillary hair 	<ul style="list-style-type: none"> • Jaundice (sclera and under tongue) and pallor (conjunctival) • Angular stomatitis • Atrophic glossitis (pale, smooth) • Beefy, raw tongue • Aphthous ulcers • Dental hygiene • Bilateral parotid swelling • Feter hepaticus, uremia, ketones, alcohol smell • Spider nevi • Lymph nodes: <ul style="list-style-type: none"> • Cervical <ul style="list-style-type: none"> • Troisier's sign (Lt. supraclavicular LN) • Axillary • Inguinal 	
		<th>Chest</th> <td></td>	Chest	
		<ul style="list-style-type: none"> • Spider nevi • Scratch marks • Hair distribution • Gynecomastia (male) • Breast atrophy (female) 		

Abdominal Exam:

Inspection:

Foot of the bed	Right side of patient
<ul style="list-style-type: none"> • Symmetrical, flat or scaphoid (contour), not distended. • Abdominal respiration (abdomen moves with respiration (diaphragmatic) + breathing pattern) • Umbilicus in the midline and inverted 	<ul style="list-style-type: none"> • Scars, striae, stoma, spider nevi, skin lesions, scratch marks • Bruising, masses, dilated veins (caput medusa), hair distribution • Visible peristalsis and pulsation • Ask patient to cough (to his left side) > look for hernial orifices (no visible cough impulse), and observe his facial expressions for pain • Ask patient to raise his head and look for divarication of recti


Palpation: Ask for any area of pain, sit on a chair, or kneel besides the bed, warm your hands, maintain eye contact. Keep your right hand flat and in contact with the abdominal wall, palpate the nine abdominal segments, and ask the patient to report any tenderness.

Superficial palpation	Deep palpation
<ul style="list-style-type: none"> • Superficial masses, tenderness, guarding. • "Soft lax abdomen, no rigidity" 	<ul style="list-style-type: none"> • Deep masses, tenderness. • Mention that you will "test for rebound tenderness".

Percussion: Do **general percussion** of the entire abdomen (Normal **tympanic** percussion note), then percuss from the umbilicus downwards for **suprapubic (bladder) dullness**.

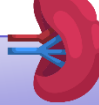
Enlarged Organs testing: (Notice that we **palpate all organs with deep inspiration**, and we percuss from above with the patient holding his breath in full expiration).

RIF = right iliac fossa



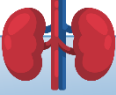
Liver

- **Palpation:** Start from RIF and start going upwards 1 cm at a time until you reach the liver edge or the costal margin. If you find the edge then describe it, if you don't then you have to percuss upwards until you find liver dullness, ask the patient to hold his finger there.
- **Percussion:** From the 2nd right ICS MCL, until you reach liver dullness.
- Measure **liver span** (8-12cm).



Spleen

- Start **palpation** from the RIF and go upwards diagonally 1 cm at a time until you reach the left costal margin, tell the patient to roll towards you and with your left hand pull his ribcage outwards while palpating again with your right hand. (Normally not palpable)
- **Percussion** for splenic dullness from umbilicus diagonally. And then left mid-axillary line below 9th-11th ribs (normal dullness).



Kidneys

- Remember to test **both kidneys**.
- Always put your right hand above and your left below the patient.
- **Palpation:**
 - Bi-manual test
 - Ballotable
- Test for **renal angle tenderness** with palpation first then light percussion with a closed fist. (remember to observe the patient's face)
- While patient is sitting up examine **sacral edema**.

Ascites test:

Shifting dullness

- Percuss to find most tympanic point anteriorly, then percuss laterally to find dullness, ask the patient to roll away from you, wait for 10 seconds and percuss the same area, if the dullness stays dull then there is no shifting dullness

Fluid thrill

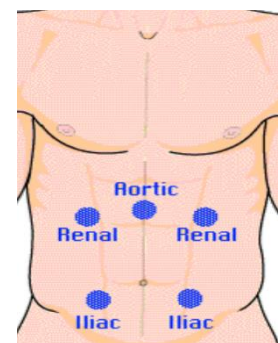
- Place the palm of your left hand flat against the left side of the patient's abdomen and ask the patient to place the edge of his hand on the midline, and flick a finger of your right hand against the right side of the abdomen, if you don't feel a ripple against your left hand, then there is no fluid thrill

Auscultation: Use your **diaphragm, warm it**. 1) RIF for **bowel sounds** (say you need to listen for 2 minutes) 2) Listen above the umbilicus for **aortic bruits**. 3) Listen above and lateral to umbilicus (3 cm) for **renal arteries bruits** [Y]. 4) Listen down and lateral to umbilicus (3cm) for **iliac arteries bruits** [^]. 5) Listen over the liver & spleen for **bruits & friction rub**.

“Normal gurgling bowel sounds, no aortic bruits, no renal bruits, no iliac arteries bruits, no liver or spleen bruits or friction rub.”

Finish your examination by saying:

“I'll test for succussion splash, and I need to do digital rectal examination. I'll examine the external genitalia and hernial orifices. I'll examine the back, and I'll examine Virchow's LN. I'll examine the lower limbs for edema, loss of hair, pyoderma gangrenosum and auscultate for bruits above the femoral artery.”



NERVOUS SYSTEM EXAMINATION

Setting	First impression	Speech examination	Dysphasia examination
<ul style="list-style-type: none">• Introduction, ask for permission and chaperone• Wash hands, ensure privacy, warmth and illumination• Expose needed areas• Position the patient as needed	<ul style="list-style-type: none">• Conscious, alert, oriented (place, person, time)• Looks well• Facial expression, general demeanor• Stance (feet together with eyes open then closed) & gait (normal + tandem + on toes and heels)• Involuntary movement• Speech• VITALS	<ul style="list-style-type: none">• Note volume, rhythm, clarity.• Ask the patient to repeat phrases (tongue and lip sounds, tongue twister)• & Count to 30 to assess fatigue• & Cough then say 'Ah', observe the soft palate rising bilaterally• No dysarthria, no dysphonia, no dysphasia.	<ul style="list-style-type: none">• Fluency, appropriateness of speech content.• Give a simple three-stage command.• Ask the patient to:<ul style="list-style-type: none">• Name a common object• Repeat a simple sentence• Read a passage from a newspaper• Write a sentence, examine his handwriting

Meningeal irritation signs: Neck stiffness, Brudzinski's sign, Kernig's sign.

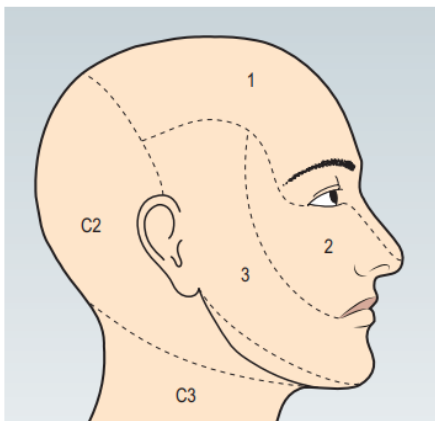


Fig. 7.6 The sensory distribution of the three divisions of the trigeminal nerve. 1, Ophthalmic division. 2, Maxillary division. 3, Mandibular division.

Cranial nerves examination:

[I] Olfactory

- Check nasal passages for clearance.
- Ask the patient to close his eyes and close one nostril at a time, use scratch and sniff test cards.

[VIII] Vestibulocochlear

- Whispered voice test
- Tuning fork tests: Weber's & Rinne's (normally both positive)

[V] Trigeminal

- **Sensory:** Light touch, superficial pain, **mention nasal tickle test and testing common sensation of the anterior 2/3 of the tongue.**
- **Motor:** Inspection for wasting of muscles of mastication (masseters, temporalis)
- Ask the patient to clench his teeth and palpate the muscles' bulk
- Test the jaw against resistance (power, no deviation)
- **Jaw jerk** (normally absent).
- **Corneal reflex**

[VII] Facial

- **Inspection** for asymmetry (note blinking, eye closure, nasolabial folds), involuntary movements
- Ask patient to **raise eyebrows** (symmetrical wrinkling of forehead), to **bare his teeth** (symmetry), to **open his mouth** (platysma).
- Test **power** (close your eyes tightly and resist me opening them, blow out your cheeks with your mouth closed against resistance)
- **Corneal reflex and taste sensation from the anterior 2/3 of the tongue.**

[IX, X] Glossopharyngeal & Vagus

- **Speech:** Dysarthria, dysphonia
- Say 'Ah' (use torch) (symmetrical elevation of **soft palate with uvula** in midline)
- Ask pt. to puff his cheeks with lips closed (no nasal escape)
- **Cough** (Normal, no bovine cough)
- **Swallow test, gag reflex, common and taste sensation from the posterior 1/3 of the tongue.**

[XI] Accessory

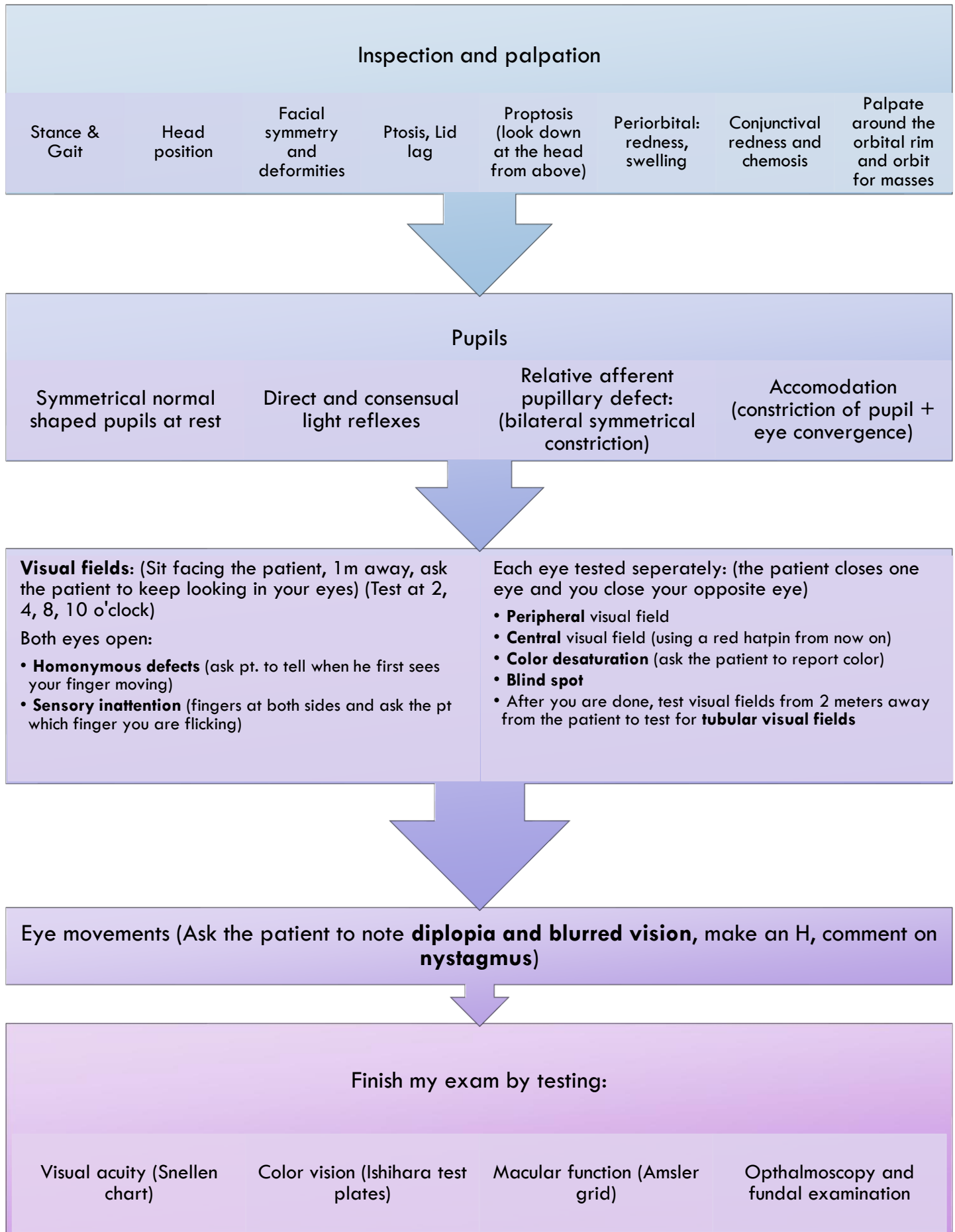
- **Exposure above the waist**
- **Sternocleidomastoid** (wasting, hypertrophy, muscle bulk) & **trapezius** from behind (wasting or asymmetry)
- Ask the patient to shrug his shoulders against resistance
- Ask the patient to resist head turning left and right and then test both SCM muscles by asking pt. to flex his neck and resist with your palm on their forehead.

[XII] Hypoglossal

- Ask the patient to open his mouth
- **Inspection** for wasting, fasciculation or involuntary movement
- Ask the patient to put out his tongue (deviation and involuntary movement)
- Ask him to move it from side to side
- Test **power** (patient pressing his cheek with you opposing externally)
- Assess **speech** by asking the pt. to say 'lalala'
- **Swallow test**

Corneal reflex & lacrimation reflex: afferent trigeminal (ophthalmic) and efferent facial.

Visual system examination:



Motor examination: (Warm your hands before touching the patient, and ask for any area of pain or movement limitation, maintain eye contact when palpating tenderness)

Stance (standing with feet together and eyes open then closed) & **Gait** (normally + tandem + toes and heels)

Inspection & palpation

Symmetry

Deformities, wasting or hypertrophy

Abnormal movements
(**fasciculations (flick skin), tremors, myoclonic jerks, dystonia, chorea, athetosis, ballism, tics**)

Palpation of bulk (hypertrophy, wasting) & tenderness

Tone (ask patient to relax, move joint through full range of motion)

Lower limb: no clonus (ankle, knee), no myotonia

Power (Compare limbs)

Against gravity

Against resistance

Grip strength

Pronator drift

Truncal strength (ask patient to sit up or stand without using his arms)

Reflexes (Compare limbs, relax patient)

Upper limb: Biceps (C5,6), Triceps (C6,7), Supinator or brachioradialis (distal end of radius) (C5,6), finger jerk, Hoffmann's reflex (both UMNL)

Lower limb: knee jerk (L3,4), ankle jerk (S1)

Plantar response (S1,2)
"Absent babinski sign", abdominal (T8-T12), **mention** cremasteric (L1,2)

Mention you will test for **primitive reflexes** (snout, grasp, palmomental, glabellar tap)

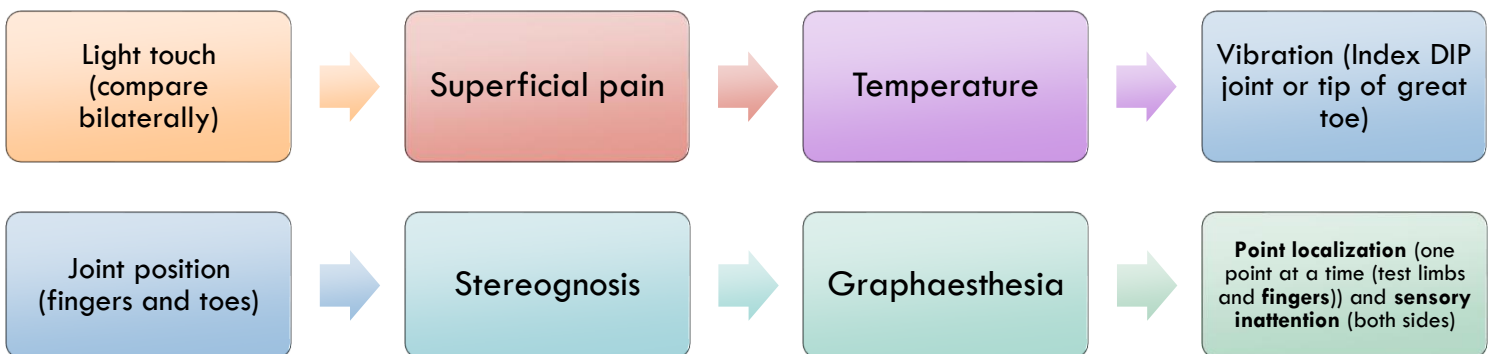
Reflex reinforcement: asking the patient to clench teeth or make a fist with the contralateral hand (upper limb) or to interlock the fingers and pull one hand against the other (lower limb).

Coordination test (Cerebellar function)

First off	Upper limb	Lower limb
<ul style="list-style-type: none"> • Stance & Gait • Speech (dysarthria, staccato or slurred speech) • Eye movement: horizontal nystagmus 	<ul style="list-style-type: none"> • Tone • Reflexes • Finger-to-nose test (no dysmetria, no intention tremor, no dysynergia) • Rapid alternating movement (No dysdiadochokinesia) • Rebound phenomenon (normal) 	<ul style="list-style-type: none"> • Tone • Reflexes • Heel-to-shin test (no dysmetria or intention tremor)

Apraxia examination (Higher cortical dysfunction): ask the patient to perform an imaginary act (drinking a cup of tea), ask the patient to copy your finger movement (draw in the air), ask the patient to copy a geometrical shape, ask the patient to put on his clothes, ask him to lie down and perform cycling movement.

Sensory examination: patient palms upward, looking at the ceiling or closing his eyes, use sternum as reference



Mention testing two-point discrimination.

Upper limbs: C5 > Deltoid area // C6 > Biceps, lateral forearm, thumb // C7 > Middle finger // C8 > Little finger // T1 > Medial forearm

Lower limbs: L2 > Lateral thigh // L3 > Medial knee // L4 > Medial leg // L5 > Lateral leg, foot dorsum // S1: little toe, lateral side of the foot

MSS EXAMINATION

Setting	First impression	General Inspection	Nodules
<ul style="list-style-type: none"> • Introduction, ask for permission and chaperone • Wash hands, ensure privacy, warmth, illumination • Exposure for any joint test is ideally one joint above and one joint below, but keep in mind cultural concerns • Position the patient • Ask for any site of pain and warm your hands before touching the patient, maintain eye-eye contact 	<ul style="list-style-type: none"> • Conscious, alert, oriented (place, person, time) • Looks well, not in pain • VITALS <ul style="list-style-type: none"> • Pulse • BP • RR • O2 sat • Temperature • BMI 	<ul style="list-style-type: none"> • Pallor, rashes, hair changes • Thickened tight skin (facial feature) • Eye redness, blue sclera • Mouth ulcers • Psoriasis • Hands flexion contractures, calcium deposits in finger pulps, ulceration, pulp atrophy, finger pallor • Nail pitting, onycholysis, telangiectasia, nail-fold infarcts 	<ul style="list-style-type: none"> • Rheumatoid arthritis (hands, extensor surface of forearm, sacrum, Achilles tendon) • Osteoarthritis (DIP > Heberden, PIP > Bouchard) • Gouty tophi (Olecranon bursa, helix of the ear, extensor aspects of the fingers, hands, knees, toes)

Always **compare limbs**, **active before passive movements**. Demonstrate actions to the patient.

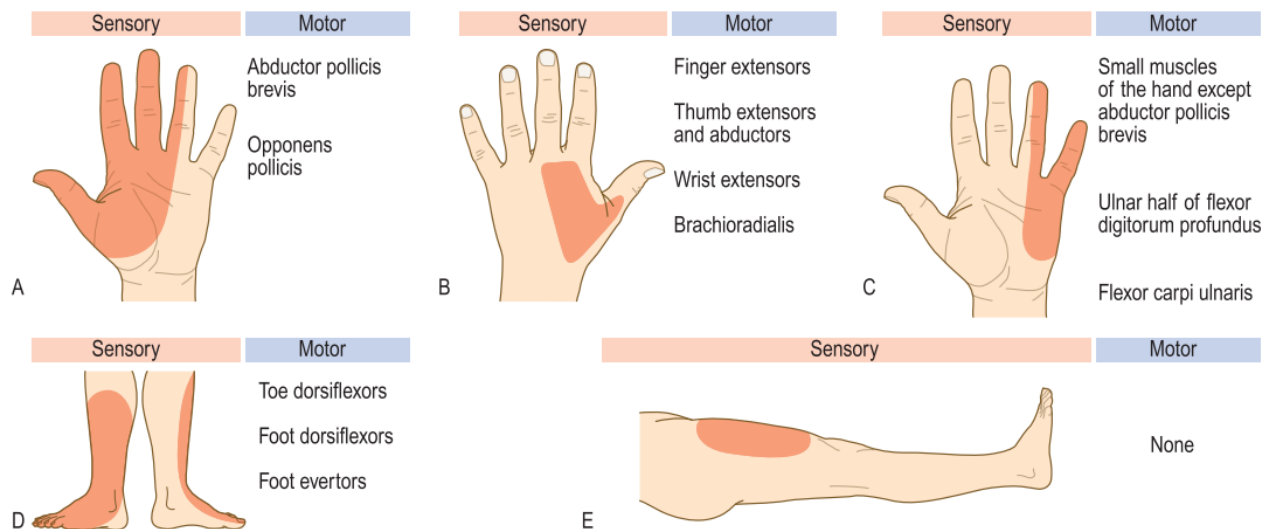


Fig. 7.27 Sensory and motor deficits in nerve lesions. **A** Median. **B** Radial. **C** Ulnar. **D** Common peroneal. **E** Lateral cutaneous of the thigh.

Common peroneal exam: Weakness of ankle dorsiflexion and eversion, extension of the big toe. (Note inversion and ankle reflex will be preserved) // Sensory loss over the dorsum of the foot.

Lateral cutaneous nerve of the thigh exam: lateral aspect of the thigh sensation. // Palpate the abdomen and groin for masses or inguinal lymph nodes.

Hand and wrist examination (Seat the patient facing you, with their arms exposed to elbow)

Look

- Skin changes (Erythema)
- Swelling (note loss of interknuckle indentation (fist))
- Hair distribution
- Deformity
- Extra-articular signs

Deformity

- Arachnodactyly
- Boutonniere (buttonhook), swan neck, mallet
- Bouchard (PIP) and Heberden (DIP)
- Subluxation, ulnar deviation at MCP joints
- Wrist displacement or deviation
- Rotational deformity: Flex fingers, they don't cross and point to scaphoid tubercle

Extra-articular signs

- Dupuytren's contracture
- Muscle wasting (interossei, thenar, hypothenar)
- Psoriasis
- Nail-fold infarcts (vasculitis), telangiectasia, scars
- Nail pitting and onycholysis
- Rheumatoid nodules on the extensor surface of forearm, and psoriatic plaques at elbow

Feel (DIP,PIP,MCP,Wrist)

- Temperature, sweaty/dry
- Swelling (hard, soft spongy)
- Tenderness
- MCP squeeze test
- Crepitation (MCP, wrist)
- Ask the pt. to flex and then extend their fingers (triggering, locking)
- Palpate flexor tendon sheaths (Swelling & tenderness)

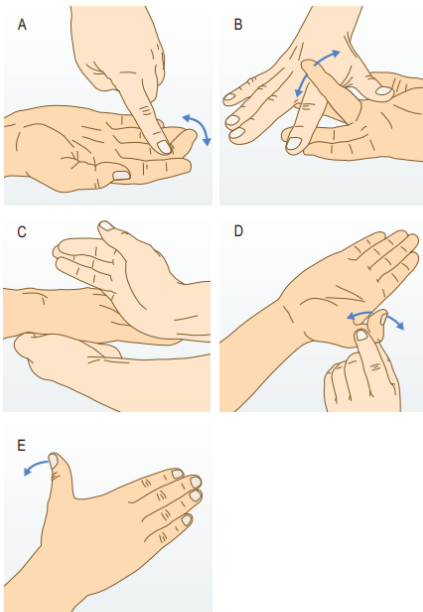


Fig. 13.24 Testing the flexors and extensors of the fingers and thumb. [A] Flexor digitorum profundus. [B] Flexor digitorum superficialis. [C] Extensor digitorum. [D] Flexor pollicis longus. [E] Extensor pollicis longus.

Move (intact tendon)

- **Active**
 - Make a fist then extend fingers
 - **FDP** (ask the patient to flex DIP while you hold PIP extended)
 - **FDS** (hold all fingers extended but one, ask to flex the PIP of the tested finger)
 - **Extensor digitorum** (extend fingers with the wrist in neutral position)
 - **Flexor and extensor pollicis longus** (hold the proximal phalanx and ask to flex and extend the IP joint of thumb)
 - **Extensor pollicis longus** (extend thumb with palm flat on surface)
 - **Thumb opposition, abduction, adduction**
 - Test **grip**
 - **Wrist:** test phalen's and reverse phalen's, flexion & extension, check pronation and supination, ulnar and radial deviation
- **Passive** (Move all joints)
- Mention using **finkelstein test** (De Quervain's tenosynovitis)

Peripheral nerve exam (intact motor & sensation)

- **Median (carpal tunnel)**
 - Wasting of thenar eminence
 - Thumb abduction (resist)
 - Finger flexion (**stone**)
 - Anterior interosseous nerve (**Ok sign**, resist)
 - Test **sensation**
 - Carpal compression test
 - Tinel's sign
 - Phalen's and reverse phalen's test
- **Radial**
 - Wrist and finger extension (**paper**) (resist)
 - Test **sensation**
 - Triceps movement & jerk
 - Brachioradialis elbow flexion
- **Ulnar**
 - Hypothenar wasting and claw hand, dorsal guttering
 - Finger abduction (resist), adduction (**scissors**)
 - Adduction power (hold a paper between fingers) (thumb adduction > pt. NOT flexing his thumb)
 - Test **sensation**
 - Trauma or scars on the medial elbow

Knee examination: Expose both legs up to mid-thigh. Patient standing and walking then laying supine.

Look

Stance and gait (valgum, varum), asymmetry

Leg length discrepancy

Scars, sinuses, erythema, rashes, hair distribution

Muscle wasting, measure **thigh girth** 20 cm above tibial tuberosity

Flexion deformity

Swelling (housemaid's knee, posteriorly baker's cyst)

Parapatellar hollow (**effusion test**)

Feel

Joint lines, patella, patellar tendon, tibial tuberosity

Head of fibula

Warmth (compare), tenderness

Effusion test:

- Ripple (milking) test
- Patellar tap
- Patellar fluctuation
- Transmitted thrill

Synovitis (sponginess)

Move (normal range 0-140 degrees)

Active flexion and extension (crepitation)

Ask the patient to lift their leg extended and note any **extensor lag**

Passive flexion and extension

Assess hyperextension (**recurvatum**) by lifting both legs by the feet

Ligament testing & Special

Anterior & Posterior cruciate ligaments

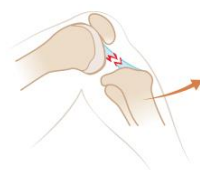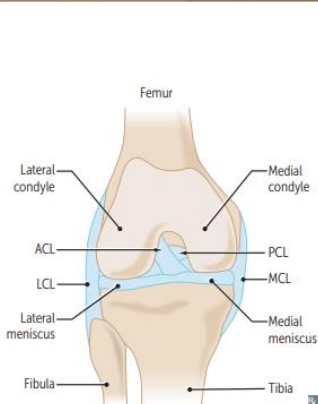
- No posterior sag
- Posterior then Anterior drawer sign
- Lachmann test

Collateral ligaments

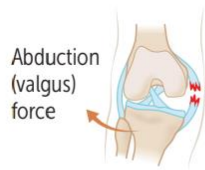
- Valgus & Varus stress on 0 and 30 degrees

Meniscus tear (McMurray test) (flex knee first)

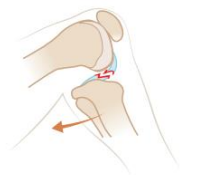Patellar apprehension test



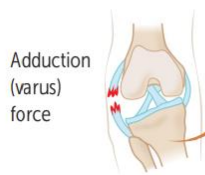ACL tear



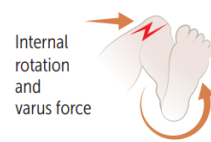
MCL tear



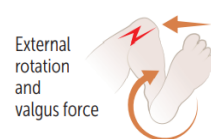
PCL tear



LCL tear



Lateral meniscal tear



Medial meniscal tear



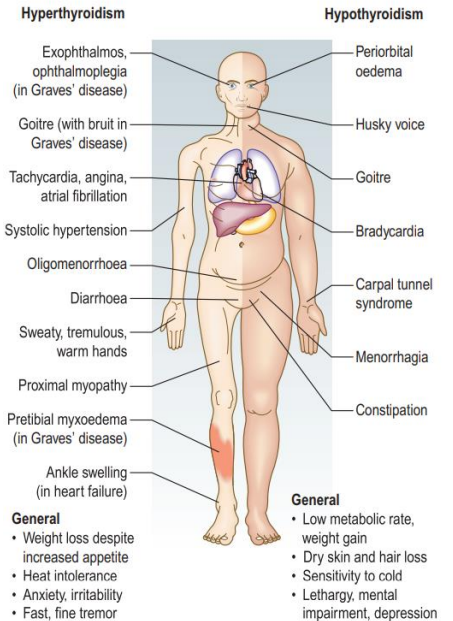
THYROID EXAMINATION

Setting

- Introduction, ask for permission and chaperone
- Wash hands, ensure privacy, warmth, illumination
- **Exposure** of neck and upper chest
- **Position** the patient sitting upright with neck slightly extended
- Ask for any site of pain and warm your hands before touching the patient, **maintain eye-eye contact**

First impression

- Conscious, alert, oriented (place, person, time)
- Looks well, not in pain
- Not agitated, restless, apathic or slow in movement
- Normal speech (not pressured, not slow and deep) (No hoarseness or bovine cough)
- Fat, thin
- Appropriate clothing to the weather
- **VITALS** (Pulse (rate, rhythm, volume, atrial fibrillation, collapsing pulse) and BP, BMI, temperature, RR, O₂ sat)



General examination

- **Facial** appearance, dry skin, excessive sweating, hair loss, loss of lateral third of eyebrows, enlarged tongue and lingual goiter
- **Hands** for thyroid acropachy (mimics clubbing), onycholysis, palmar erythema, temperature, sweaty/dry hands, vitiligo, fine tremor, carpal tunnel syndrome tests
- Test **proximal muscle weakness** (stand with arms crossed), **tendon reflexes** (biceps, knee jerk, ankle)
- **Auscultate** the heart for a midsystolic flow murmur (hyperthyroidism)
- Inspect the **limbs** for coarse, dry skin and **pretibial myxedema, ankle swelling**

Eyes

- **Inspect** for periorbital puffiness or edema, lid retraction, ptosis, lid swelling or erythema, lid lag, proptosis
- Conjunctival redness or swelling (chemosis), corneal ulceration.
- Test **eye movements** (make an H) (diplopia, ophthalmoplegia, pain)

Inspection

- (Front and side with neck extended) Asymmetry or scars, masses (goiter). (normally thyroid not visible)
- Ask the patient to **swallow** and note any mass moving.
- Ask the patient to **protrude his tongue** and note any mass moving.
- **Pemberton's sign** (both arms flexed anteriorly, note any change in facial color)

Palpation

- **Palpation** from behind or front of the patient with **neck slightly flexed**, feel for thrills
- Comment on (palpable or not, if palpable: Symmetry, size and surface, consistency, tenderness, mobility)
- Ask the patient to **swallow** while you feel symmetrical elevation of the thyroid lobes, then ask the patient to **protrude his tongue**
- **Cervical lymphadenopathy palpation**
- **Percuss** the manubrium (directly on bone) to assess dullness due to retrosternal extension of goiter
- **Auscultate** for a thyroid bruit