

Ectopic Pregnancy

“Every idea progress in human mind through three stages:

First: what nonsense; then

Second: there is something to it; and finally

Three: everyone knows about it.”

Alexander von Humboldt

*“The true sign of intelligence is not knowledge
but imagination”*

Albert Einstein

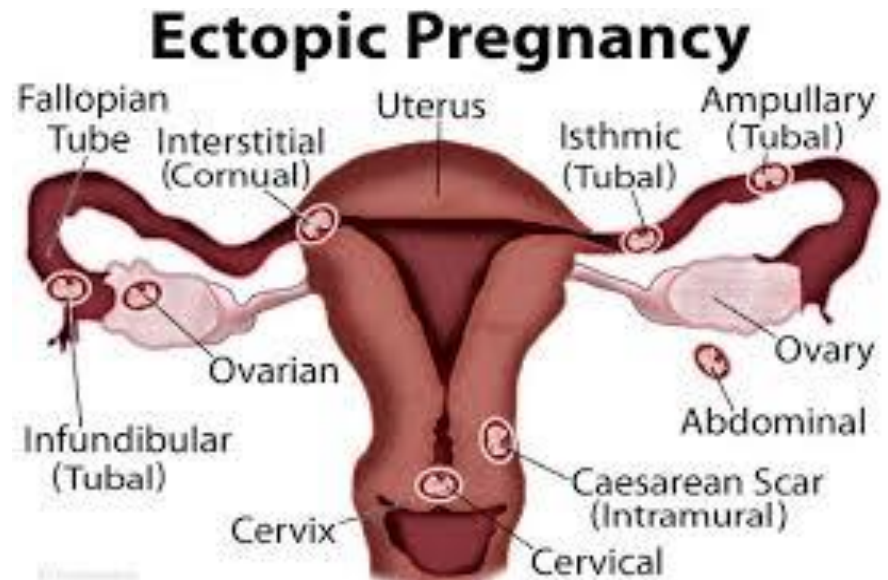
“Leadership is a potent combination of strategy and character. But if you must be without one, be without the strategy”

Norman Schwarzkopf

*Money does not buy happiness, but it makes you
live your grief in good fortune*

Ectopic Pregnancy

- *Definition.*
- *Incidence. Doubled after ARTs to [2-3%]*
- *Usually found in the first 6-8 weeks of pregnancy; but later if not located in the tube.*
- *Heterotopic pregnancy.*



Mortality risks

- *Before the 19th century, → exceeded 50%.*
- *By the end of the 19th century, dropped to 5%.*
- *Current advances in early detection, improved to less than 5 in 10,000.*
- *Remains the leading cause of pregnancy-related death in the first trimester of pregnancy.*

Strong Risk Factors: 1/2

- *previous ectopic pregnancy*
- *previous tubal sterilization surgery*
- *intrauterine device (IUD) use*
- *previous genital infections*
- *chronic salpingitis*
- *salpingitis isthmica nodosa*
- *infertility*
- *multiple sexual partners*
- *smoking* *continue.....*

Week Risk Factors: 2/2

- *assisted reproductive technology (ART)*
- *first sexual encounter <18 years*
- *maternal age >35 years*
- *tubal reconstruction surgery*

Land Marks

- * *The most common cause of tubal abnormality associated with ectopic pregnancy is **salpingitis**.*
- *Chromosomal abnormalities **do not cause** ectopic pregnancies.*
- *? A role for the conceptus.*

Incidence/ Sites

	Natural Conception	ARTs
Overall incidence	About 1%	2-3%
Fallopian tube	> 95%	< 90%
Ovarian & abdominal	1-2%	5%
Cervical	0.15%	1.5%
Cesarean scar	1 in 1800	Unknown
Heterotopic	1 in 30.000	1 in 100

Bilateral fallopian tube ectopic occur in 1 in 200.000

Symptoms

- *Vaginal bleeding.*
- *Nausea and vomiting.*
- *Pain; lower abdominal, sharp abdominal, iliac fossa.*
- *Pain; shoulder, neck, rectal: → diarrhea.*
- *Pain and bleeding → fainting; rupture ectopic.*

Pain

- The onset of the pain may be abrupt or slow.
- The pain may be continuous or intermittent.
- The pain may be dull or sharp.
- The pain may be mild or severe.
- The pain is not crampy.

The classic signs and symptoms:

- *Abdominal pain,*
 - *Amenorrhea,*
 - *Vaginal bleeding.*
-
- *Hypotension, ± syncope.*

Diagnostic Factors

* *Common factors mainly are:*

- *abdominal pain*
- *amenorrhoea*
- *vaginal bleeding*
- *abdominal tenderness*
- *adnexal tenderness or mass*
- *blood in vaginal vault*

* *Uncommon factors mainly are:*

- *haemodynamic instability, orthostatic hypotension*
- *cervical motion tenderness*
- *urge to defecate*
- *referred shoulder pain*

*Bleeding: → dissect into the lumen →
endometrium → spotting.*

*→ some passes into the
peritoneal cavity.*

*→ most trapped between the serosal
and mucosal layers.*

Pathophysiology

Effective transport of embryos in the fallopian tube requires a delicately regulated complex interaction between the tubal epithelium, tubal fluid, and tubal contents. This interaction ultimately generates a mechanical force, composed of tubal peristalsis, ciliary motion, and tubal fluid flow, to drive the embryo towards the uterine cavity. This process is subject to dysfunction at many different points that can ultimately manifest as ectopic pregnancy.

Pathophysiology

- *Damage of the tubal cilia by infection, →egg transport becomes disrupted.*
- *Formation of pocket like pools that engulf the fertilized eggs.*
- *Infection-related scarring and partial blockage of the Fallopian tubes.*
- *Bleeding-related scarring and partial blockage of the Fallopian tubes.*

Clinical Presentation

- *Acutely ruptured; **top surgical emergency.***
- *Probable ectopic in a symptomatic women.*
- *Possible ectopic in mild symptomatic women with pregnancy of unknown location.*

Diagnosis

- *History. Using the mind judgment.*
- *Physical examination.*
- *Ultrasound evaluation; but often the findings are not conclusive.*
- *Blood tests; serial β -hCG levels in maternal serum, CBC.*

Diagnosis | 1

- ✓ *Equivocal ultrasound results should be combined with quantitative beta hCG levels.*
- ✓ *Diagnostic uterine curettage presence or absence of intrauterine chorionic villi; The presence of chorionic villi confirms a failed intrauterine pregnancy*
- ✓ *Clinical judgment; If a patient has a beta hCG level of 1,500 mIU/mL or greater, but the transvaginal USS does not show an IUS, ectopic pregnancy should be suspected.*
- ✓ *Laparoscopic Role*

The Discriminatory Zone

- *The range of β -hCG values in which the ultrasound image can first detect the sign of intra uterine pregnancy.*
- *Most centers quote a range of 1500 to 3510 mIU/ml AS the DZ.*

Diagnosis /2

Clinical examinations are not diagnostic;

- * Up to 30% of patients with ectopic pregnancies have no vaginal bleeding,*
- * About 10% have a palpable adnexal mass,*
- * Up to 10% have negative pelvic examinations.*
- * No combination of physical examination findings can reliably exclude ectopic pregnancy*

** Combined transvaginal ultrasonography and serial quantitative beta-hCG measurements are approximately 96 percent sensitive and 97 percent specific for diagnosing ectopic pregnancy.*



** Transvaginal ultrasonography followed by quantitative beta-hCG testing is the optimal and most cost-effective strategy for diagnosing ectopic pregnancy.*

Diagnostic approach

- *Step one: Confirm pregnancy and ectopic pregnancy symptoms*
- *Step two: Evaluate hemodynamic stability*
- *Step three: Assess pregnancy location*
- *Step four: Follow with hCG and ultrasound to confirm or exclude ectopic pregnancy*
- *Step five: plan of management*

Signs of a ruptured fallopian tube ectopic

- *Sudden, severe, sharp pain,*
- *Feeling faint and dizzy,*
- *Feeling or being sick,*
- *Diarrhea.*
- *Shoulder tip pain,*
- *The dangerous of rupturing the large artery runs on the outside of each Fallopian tube.*

Differential Diagnosis

Only 50% of patients with an ectopic pregnancy present with the classic triad of amenorrhea, pain, and vaginal bleeding.

- *Appendicitis.*
- *Salpingitis.*
- *Ruptured corpus luteum cyst or ovarian follicle.*
- *Spontaneous abortion or threatened abortion.*
- *Ovarian torsion.*
- *Urinary tract disease.*

Differential Diagnosis

A study by Huchon et al found that the *following 4 symptoms independently contributed to the diagnosis of tubal rupture:*

- *Vomiting during pain,*
- *Diffuse abdominal pain,*
- *Acute pain for longer than 30 minutes,*
- *Flashing pain,*

The sensitivity was 93% in the presence of 1 or more of these items

Treatment Options

- *Observation*; resolve on their own without the need for any intervention.
- *Laparoscopy*; for diagnosis and management.
- *Laparotomy*; urgent surgery due to life-threatening bleeding.
- *Medication*; under certain circumstances.

Expectant Management

- *General health appears to be stable,*
- *Pain levels are considered to be acceptable,*
- *An ultrasound scan shows a small ectopic pregnancy with no worrying bleeding into the abdomen.*
- *Initial β -hCG titers below 200 mIU/mL?? 1000 mIU/mL.*
- *The level of β -hCG titers decreasing.*
- *Able and willing to comply with close follow up.*
- *The lady prefer expectant management than methotrexate therapy.*

Emergency surgery

- *Hemodynamically unstable*
- *Signs or symptoms of impending or ongoing rupture of ectopic*
- *Indications for a concurrent surgical procedure, which may include:*
 - *•Desire for sterilization*
 - *•Planned in vitro fertilization for future pregnancy with known hydrosalpinx*
- *Heterotopic pregnancy with coexisting viable intrauterine pregnancy*
- *Contraindications to MTX therapy*
- *Failed MTX therapy*

Surgery: Laparotomy vs. Laparoscopy

Applied for both options; salpingectomy or salpingostomy

- If suspicion that the fallopian tube has ruptured, emergency surgery.*
- If the fallopian tube has not ruptured, laparoscopic surgery may be all that is needed to remove the embryo and repair the damage.*
- Salpingostomy is preferred because it is a conservative surgical option*

Medical

Methotrexate

Antimetabolite chemotherapeutic agent that binds to the enzyme dihydrofolate reductase, which is involved in the synthesis of purine nucleotides. This interferes with deoxyribonucleic acid (DNA) synthesis and disrupts cell multiplication.

Treatment with methotrexate is an attractive option when the pregnancy is located on the cervix or ovary or in the interstitial or the cornual portion of the tube or the scar of cesarean section.

Establishing the diagnosis 1/3

By one of the following criteria:

- Abnormal doubling rate of the (β -hCG) level less than 5000 & USS identification of a GS outside of the uterus.*
- Abnormal doubling rate of the β -hCG level, an empty uterus, and menstrual aspiration with no chorionic villi.*

Establishing the diagnosis 2/3

- *The patient must be haemodynamically stable, with no signs or symptoms of active bleeding or haemoperitoneum.*
- *The patient must be reliable, compliant, and able to return for follow-up care.*
- *The size of the GS should not exceed 4cm at its greatest dimension.*

- Take into account that great love and great achievements involve great risk
- Lost time is never found again
- Nobody can make you feel inferior without your permission

- *It is the province of knowledge to speak, and it is the privilege of wisdom to listen*

- *If you talk to a man in a language he understands, that goes to his head. If you talk to him in his language, that goes to his heart.*

Establishing the diagnosis 3/3

- *Absence of fetal cardiac activity on USS findings - The presence of fetal cardiac activity is a relative contraindication.*
- *No evidence of tubal rupture - Evidence of tubal rupture is an absolute contraindication.*
- *β -hCG level less than 5000 mIU/mL - Higher levels are a relative contraindication.*
- *Evidence of hepatic or renal compromise is a contraindication to methotrexate therapy.*

Contraindications to Medical Therapy

- *A β -hCG level of greater than 5,000 mIU/mL,*
- *Fetal cardiac activity,*
- *Free fluid in the cul-de-sac*
- *"There is an inverse association between β -hCG levels and successful medical management of an ectopic pregnancy".*

Adverse Drug Effects

- *Nausea*
- *Vomiting*
- *Stomatitis*
- *Diarrhea*
- *Gastric distress*
- *Dizziness*

Treatment Effects

- *An increase in abdominal pain (occurring in up to two thirds of patients),*
- *An increase in β -HCG levels during the first 1-3 days of treatment, and*
- *Vaginal bleeding or spotting.*
- *Increased abdominal pain is believed to be caused by the separation of the pregnancy from the implanted site.*

Day 1:

- *Level of β -hCG,*
- *CBC,*
- *Liver function,*
- *kidney function tests.*
- *Blood type, Rh status,*

Day 1

Methotrexate (50 mg/m²) is administered by IM injection.

Advise patients not to take vitamins with folic acid until complete resolution of the ectopic pregnancy.

Day 4

- *The patient returns for measurement of her β -hCG level.*
- *The level **may be higher** than the pretreatment level.*
- *The day-4 hCG level is the **baseline level** against which subsequent levels are measured.*

Day 7

- *Draw β -hCG curve, perform a complete blood count.*
- *If the β -hCG level has dropped 15% or more since day 4, obtain weekly β -hCG levels until they have reached the negative level for the lab.*
- *If the weekly levels plateau or increase, a second course of methotrexate may be administered.*

- *If the β -hCG level has not dropped at least 15% from the day-4 level, $\rightarrow \downarrow$*
- *Administer a second IM dose of methotrexate (50 mg/m²) on day 7, and*
- *Observe the patient similarly.*
- *If no drop has occurred by day 14, surgical therapy is indicated.*

If the patient develops increasing abdominal pain after methotrexate therapy, repeat a transvaginal ultrasonographic scan to evaluate for possible rupture.

Conception/ Recurrence

- *Approximately 30% of women treated for ectopic pregnancy later have difficulty conceiving.*
- *The overall conception rate is approximately 75% regardless of treatment.*
- *Rates of recurrent ectopic pregnancy are between 5 and 20%.*
- *The risk increases to 30% in women who have had two consecutive ectopic pregnancies.*

Ectopic Pregnancy Facts

- *An ectopic pregnancy is a pregnancy located outside the inner lining of the uterus.*
- *Risk factors for ectopic pregnancy include previous ectopic pregnancies and conditions (surgery, infection) that disrupt the normal anatomy of the Fallopian tubes.*
- *Hormonal imbalances or abnormal development of the fertilized egg also might play a role.*
- *An ectopic pregnancy can't proceed normally. The fertilized egg can't survive.*

Continue....

- *Early treatment of an ectopic pregnancy can help preserve the chance for future healthy pregnancies.*
- *The major health risk of an ectopic pregnancy is internal bleeding.*
- *Diagnosis of ectopic pregnancy is usually established by proper history, physical exam, blood hormone tests, pelvic ultrasound, and on top thinking of it.*
- *Treatment options for ectopic pregnancy include conservative approach, surgery and medical.*

continue.....

- *Obviously, the clinical challenge is to avoid tubal rupture by making a correct and timely diagnosis, thereby optimizing fertility prospects.*
- *There is no difference in the reproductive outcome after treatment of EP by laparotomy versus laparoscopy. Salpingostomy is associated with higher subsequent IUP and recurrent EP rates compared with salpingectomy.*
- *Methotrexate is a viable alternative to laparoscopic salpingostomy for a selected group of patients.*
- *All Rh-negative, unsensitized women who have EP should receive anti-D immunoglobulin.*
- *Avoid pregnancy for at least 3 months to permit the tube normalize and the methotrexate completely eliminated.*

*“Education is not the learning of facts, but
The training of the mind to think”.*

Albert Einstein

Great minds discuss ideas; average minds discuss events; small minds discuss people

Our greatest fear should not be of failure... but of succeeding at things in life that don't really matter

