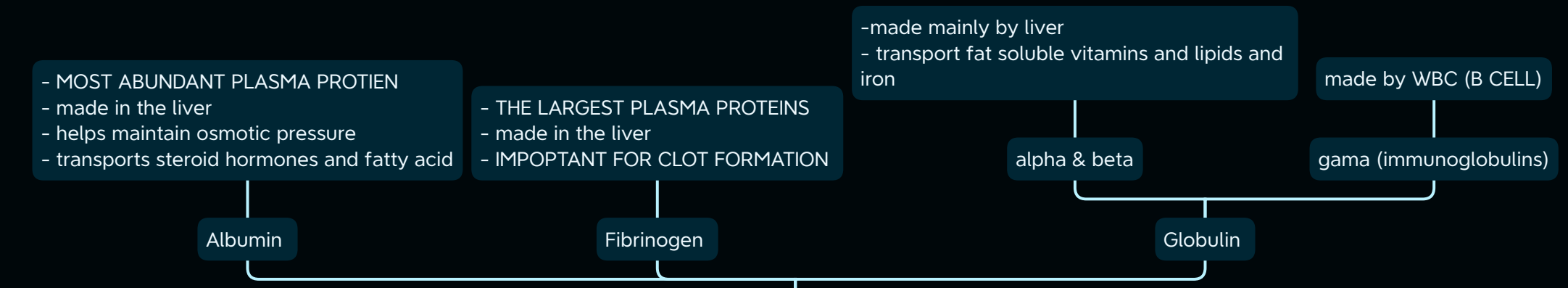
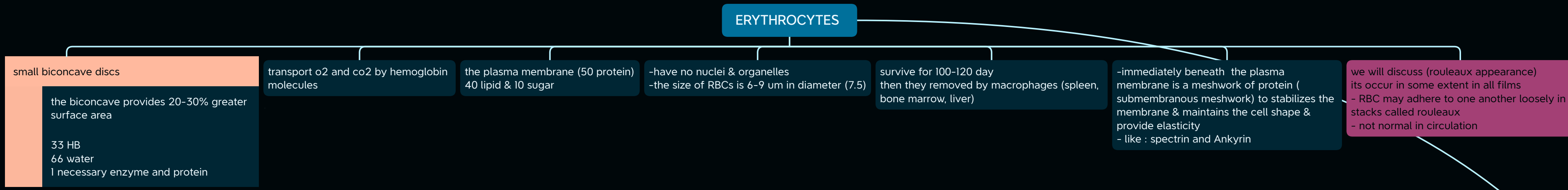


how we can know if the RBC is normal in shape or not under microscope ??
 - if you can see lighter color in middle of RBC then its normal because the biconcave shape mean less Hb in middle this lead to less stain



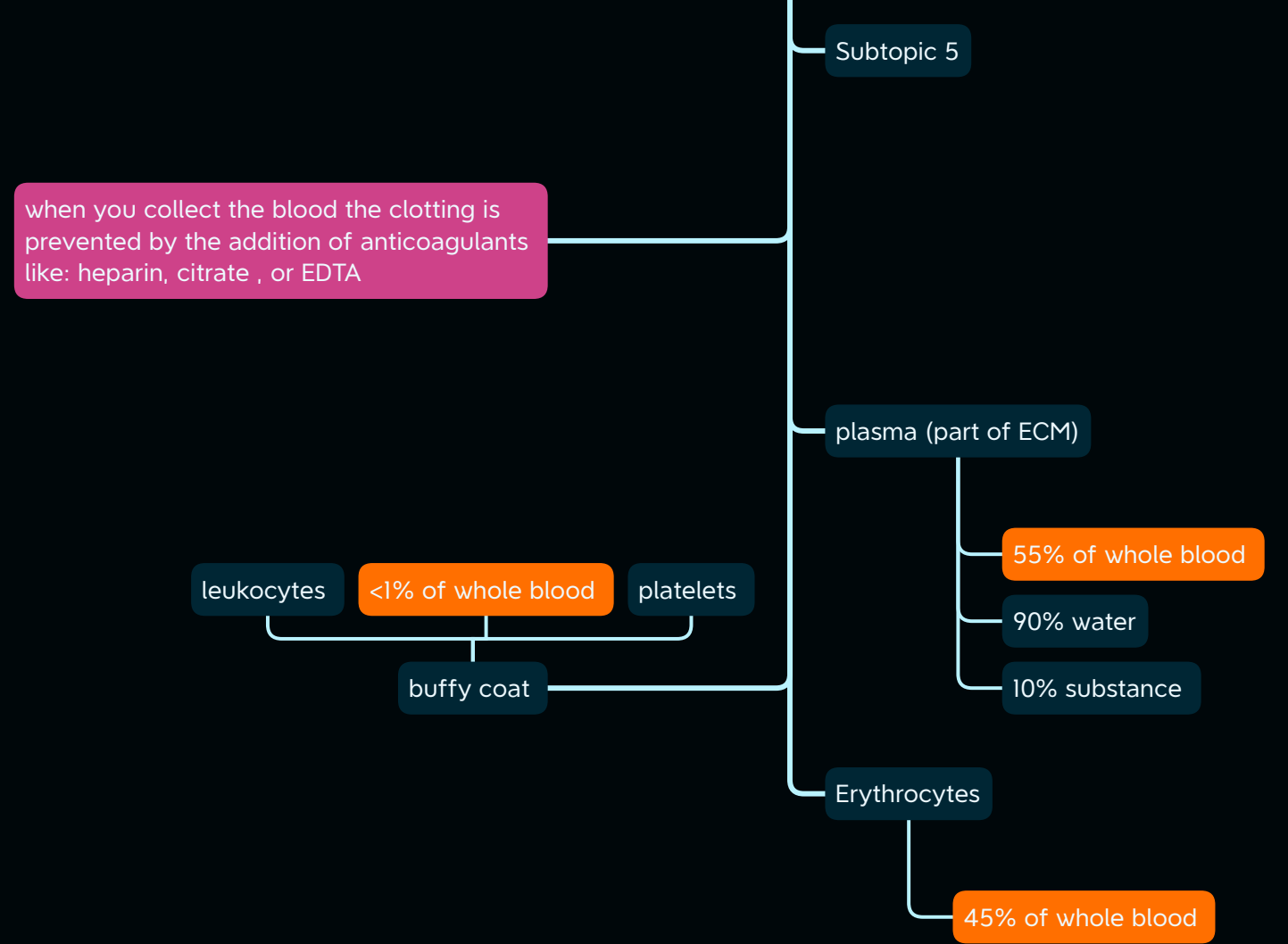
BLOOD

- blood is specialized form of connective tissue
 - HEMATOCRIT : ratio of the volume of RBC to the whole blood
 in the males: 40-53%
 in the female: 36-48%

STAIN

	neutral stain	SOME INFORMATION ABOUT STAIN
GIEMSA		
WRIGHT		-eosin : acidic dye stain basic component (red)
LEISHMAN		-hemotoxilin: basic dye stain acidic component (blue)

DIVIDE



FUNCTION

