

The respiratory system examination



The physical examination

- ❖ Inspection
- ❖ Palpation
- ❖ Percussion
- ❖ Auscultation

MAKE SURE THAT THE PATIENT IS IN APPROPRIATE POSTURE AND EXPOSURE:

- ❖ exposure: thorax fully exposed
- ❖ position: sitting in 45 degrees with a pillow beneath the head



General Inspection: start from the foot of the bed!

- ❖ Consciousness, alertness, orientation
- ❖ Position of the patient (Sitting or lying flat)
- ❖ Respiratory distress (he is using accessory muscles, he is sitting in tripod position, he has pursed lips) and respiratory rate (he looks tachypnic)
- ❖ Presence on nebulizers, inhalers and oxygen therapy
- ❖ Cyanosis (does the patient look cyanosed)
- ❖ Any audible sounds (wheeze, hoarseness of voice, stridor)
- ❖ Respiratory rate (Quietly observe and time the RR without drawing patient's attention)
(normal 12-20 breaths/min)
- ❖ Chest deformities
- ❖ Breathing Pattern



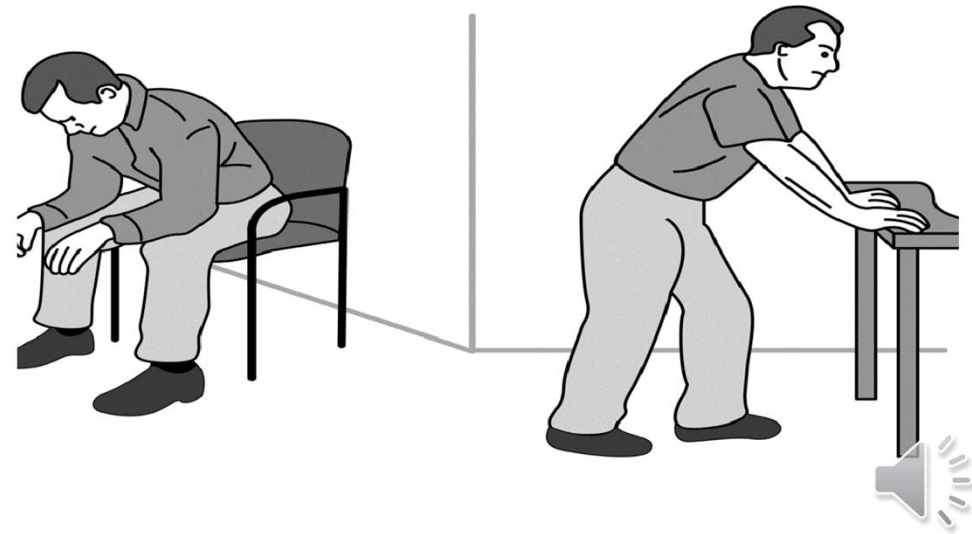
Respiratory distress

- ❖ Tachypnea
- ❖ Indrawing of the intercostal spaces
- ❖ Using accessory muscles (sternocleidomastoid, trapezius and scalene muscles)



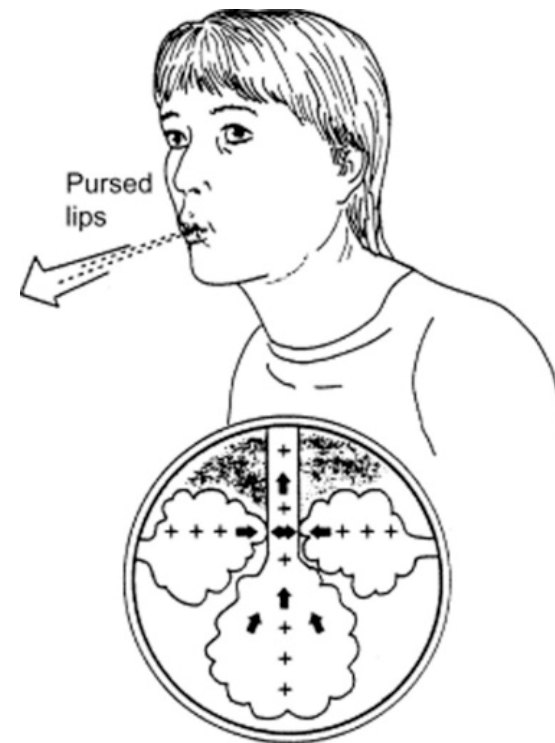
Tripod position

- ❖ Sitting forward and bracing arms on table, allowing them to use pectoralis major to pull the ribs outward during inspiration. Thus, increasing lung volume and achieving negative intrathoracic pressure.



Pursed lips

- ❖ This manoeuvre increases positive end-expiratory pressure, reducing small-airway collapse and improving ventilation.
- ❖ May be seen in patients with severe COPD



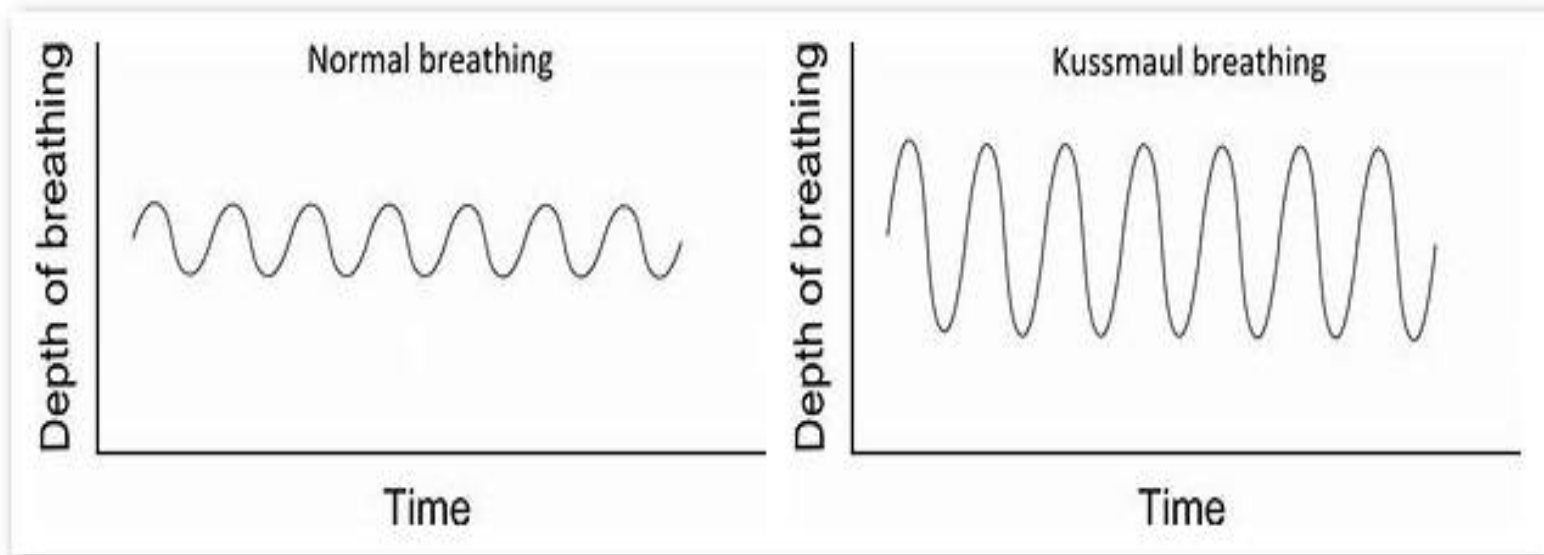
Respiratory pattern

- ❖ Cheyne–Stokes breathing: is cyclical with increasing rate and depth of breathing, followed by diminishing respiratory effort and rate, ending in a period of apnoea or hypopnoea.
- ❖ This relates to altered sensitivity of the respiratory centre to CO₂ and delay in circulation time between the lung and chemoreceptors.
- ❖ Can be seen in healthy adults at high altitude, elderly people and patients of HF.



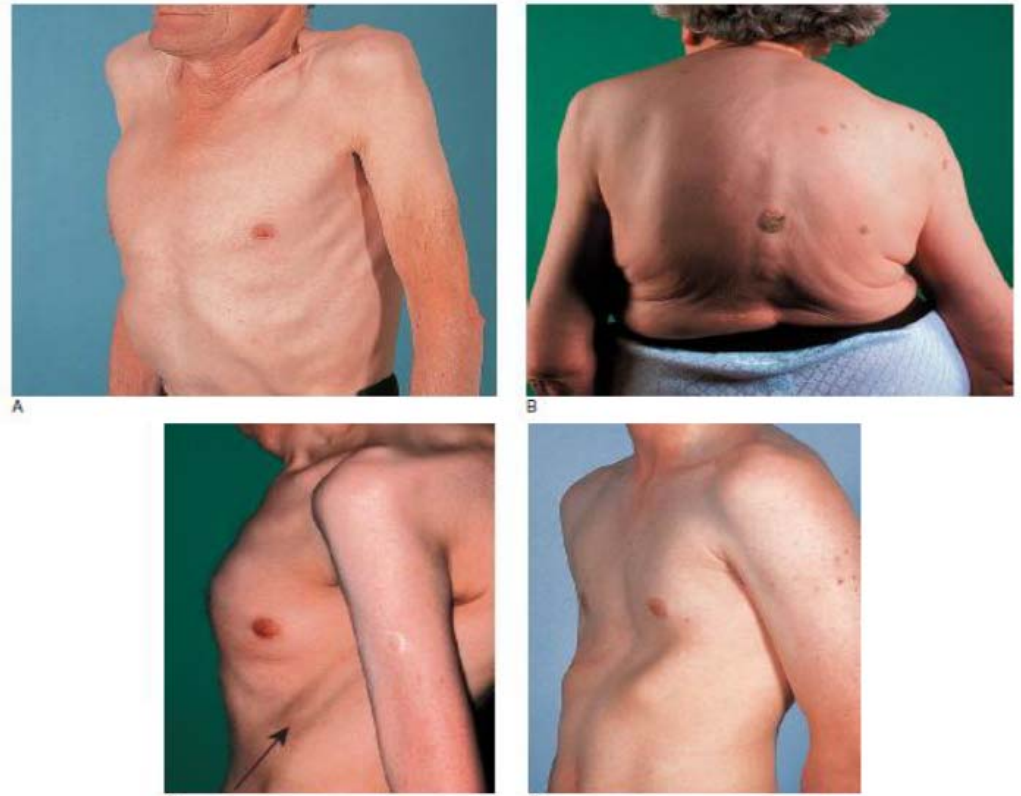Respiratory pattern

❖ **Kussmaul breathing:** is a type of hyperventilation that is the lung's emergency response to acidosis. **Kussmaul breathing** causes a labored, deeper **breathing** rate. It is most commonly associated with conditions that cause metabolic acidosis, particularly diabetes.



Chest deformity

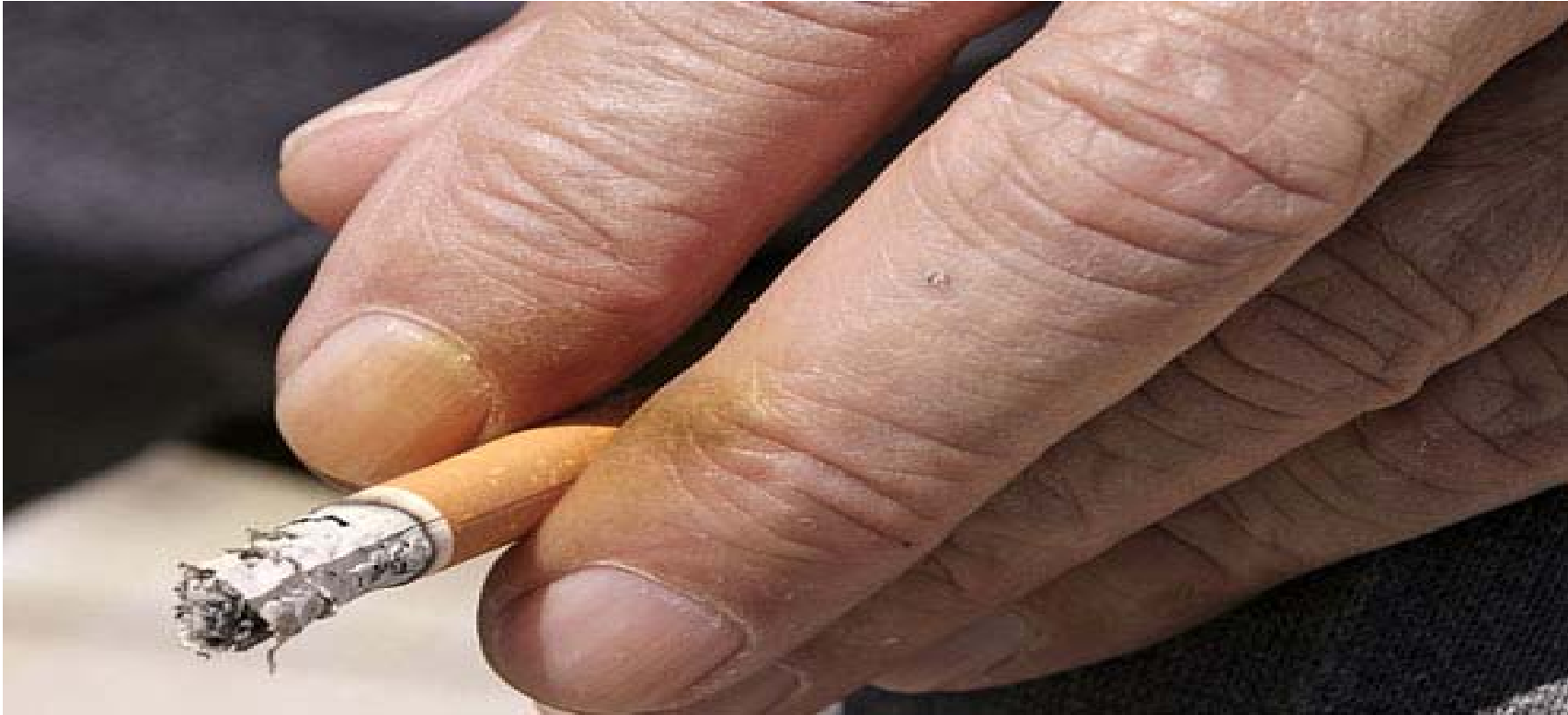- ❖ Normally; The chest should be symmetrical. The anteroposterior diameter should be less than the lateral diameter.
- ❖ Congenital as in pectus excavatum
- ❖ Acquired as in pectus carinatum
- ❖ Asymmetry of the chest
- ❖ Kyphosis, scoliosis

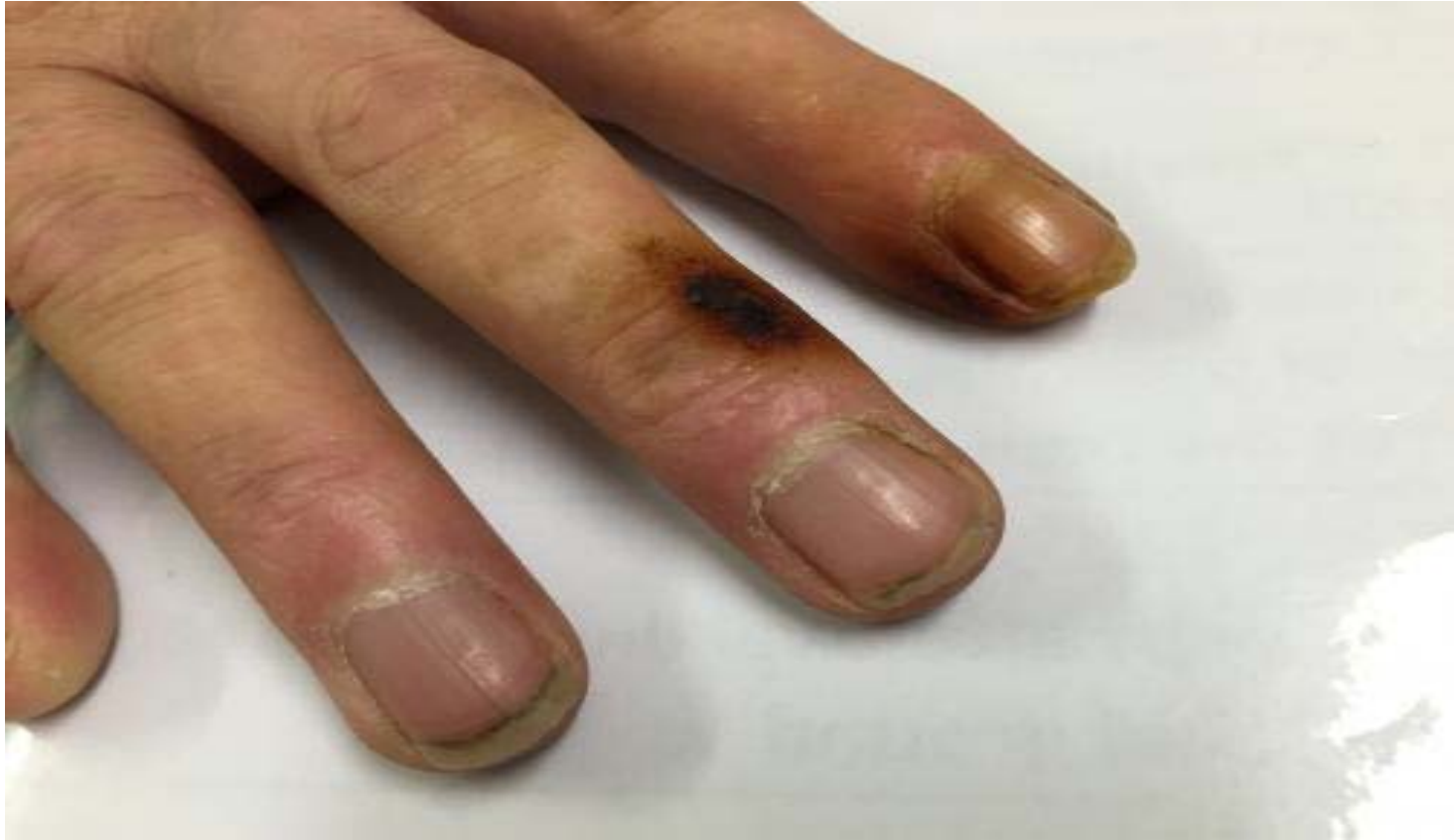

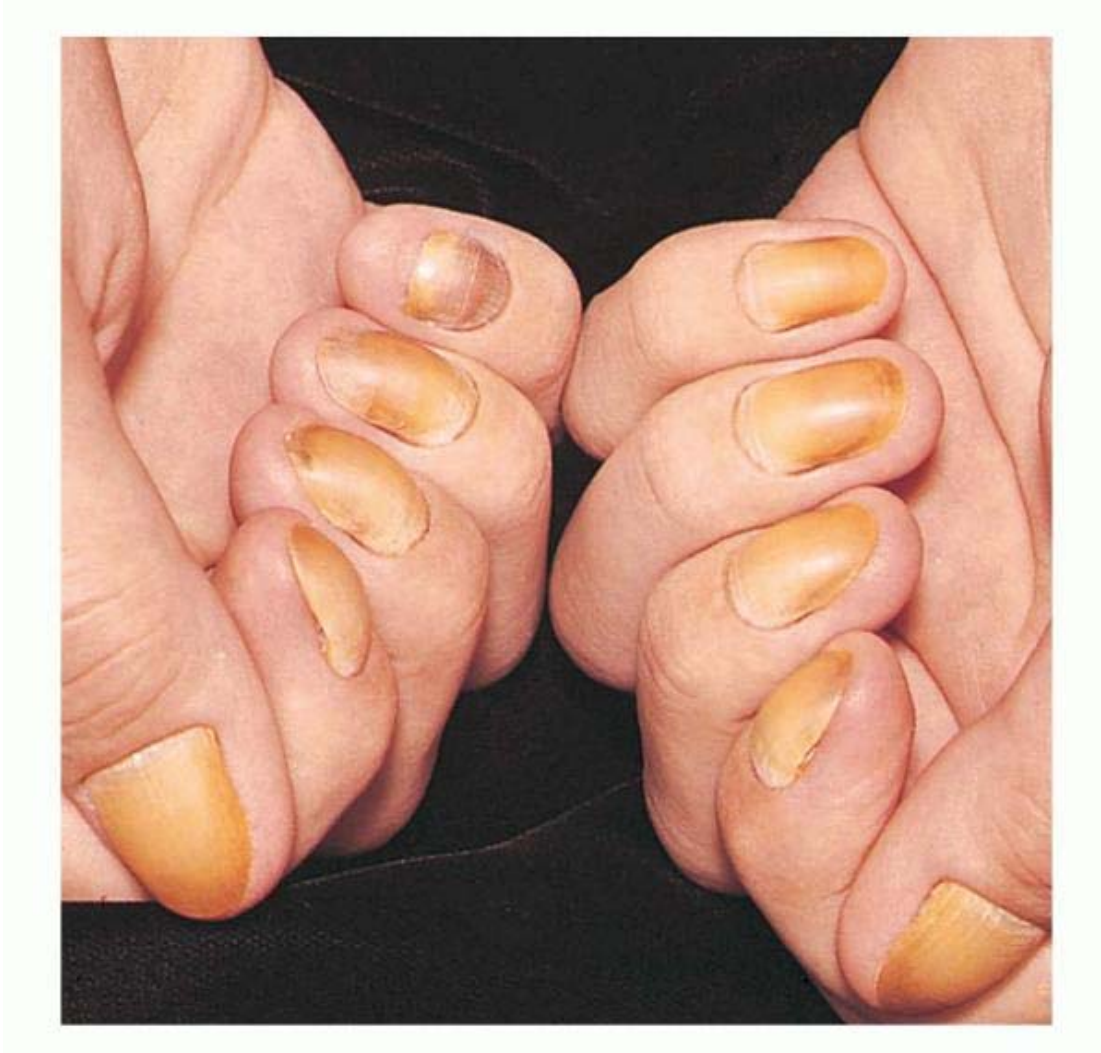Hands and arms

- ❖ Examine hands for **cyanosis**, **tar staining** and **nail discoloration** as yellow brown nail discoloration as in yellow nail syndrome
- ❖ Examine for **small muscle wasting** which may indicate T1 root damage by apical lung tumor
- ❖ Examine for **finger clubbing** and **hypertrophic pulmonary osteoarthropathy** (painful tender swelling on wrists and ankles)= **check for any tenderness in distal forearm!**
- ❖ Examine for **fine tremor** and **flapping tremor**
- ❖ Check the **pulse** and **BP**, calculate **RR!**









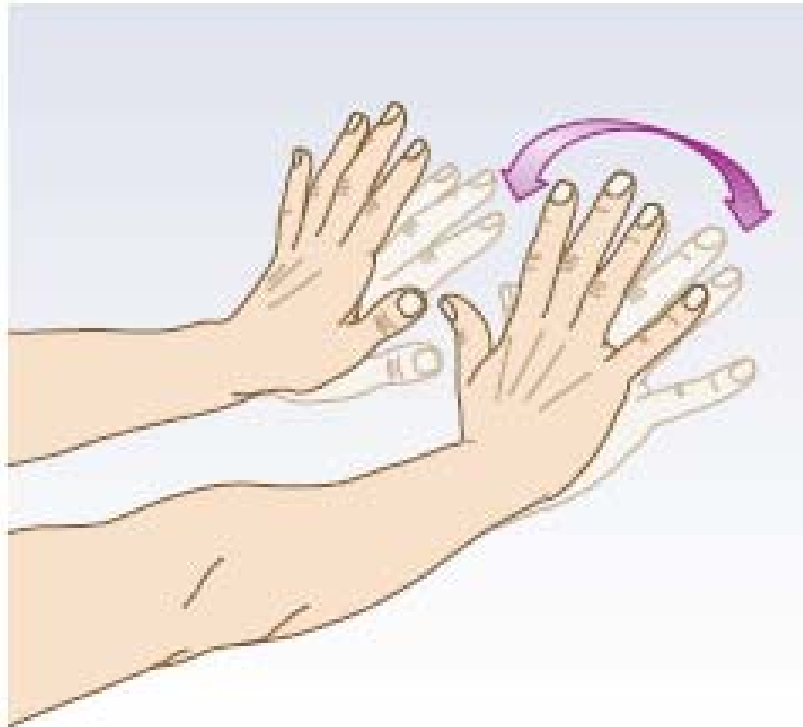

Fig. 7.10 Asterixis. Hand and arm position for observing the 'flapping tremor' of CO₂ retention.



Hypertrophic pulmonary osteoarthropathy

- ❖ Painful tender swelling of the wrists and ankles
- ❖ Rare complication of lung cancer
- ❖ Accompanies pronounced finger clubbing
- ❖ X-ray shows subperiosteal new bone formation overlying the cortex of the long bone



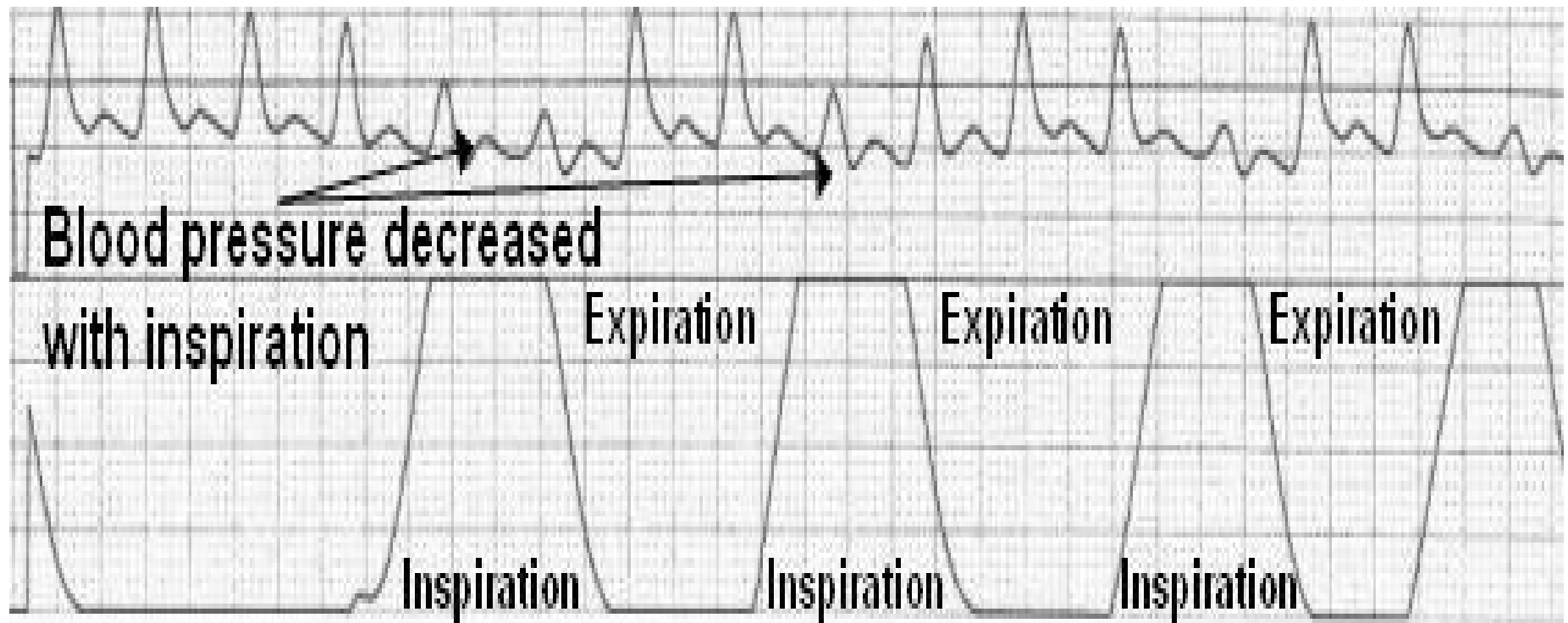
Pulsus Paradoxus

an exaggerated fall in a patient's systolic blood pressure during inspiration by greater than 10 mm Hg.

Causes:

1. Pericardial diseases: cardiac tamponade, constrictive pericarditis.
2. Non-pericardial cardiac diseases: right ventricular myocardial infarction and restrictive cardiomyopathy.
3. Non-cardiac diseases: severe chronic obstructive pulmonary disease [COPD], asthma, tension pneumothorax, large bilateral pleural effusions, pulmonary embolism.
4. Any cause of cardiac compression (iatrogenic during surgery, marked obesity, pectus excavatum).





Face

- ❖ Check conjunctiva for anemia
- ❖ Check tongue for central cyanosis
- ❖ Check for ptosis and pupil asymmetry
- ❖ Check for **Plethoric complexion**: a congested red-faced appearance associated with polycythaemia (e.g. COPD) and CO₂ retention (e.g. type 2 respiratory failure)



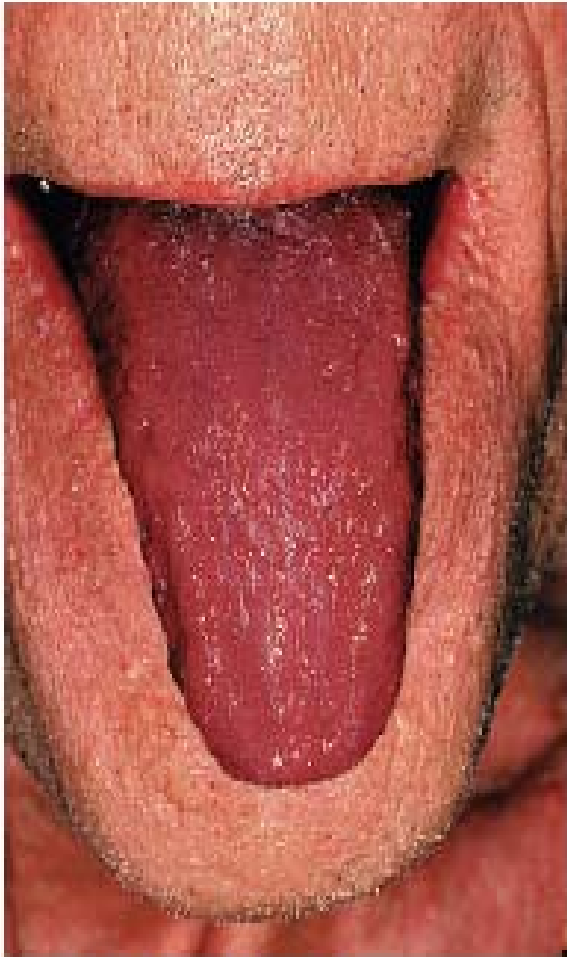
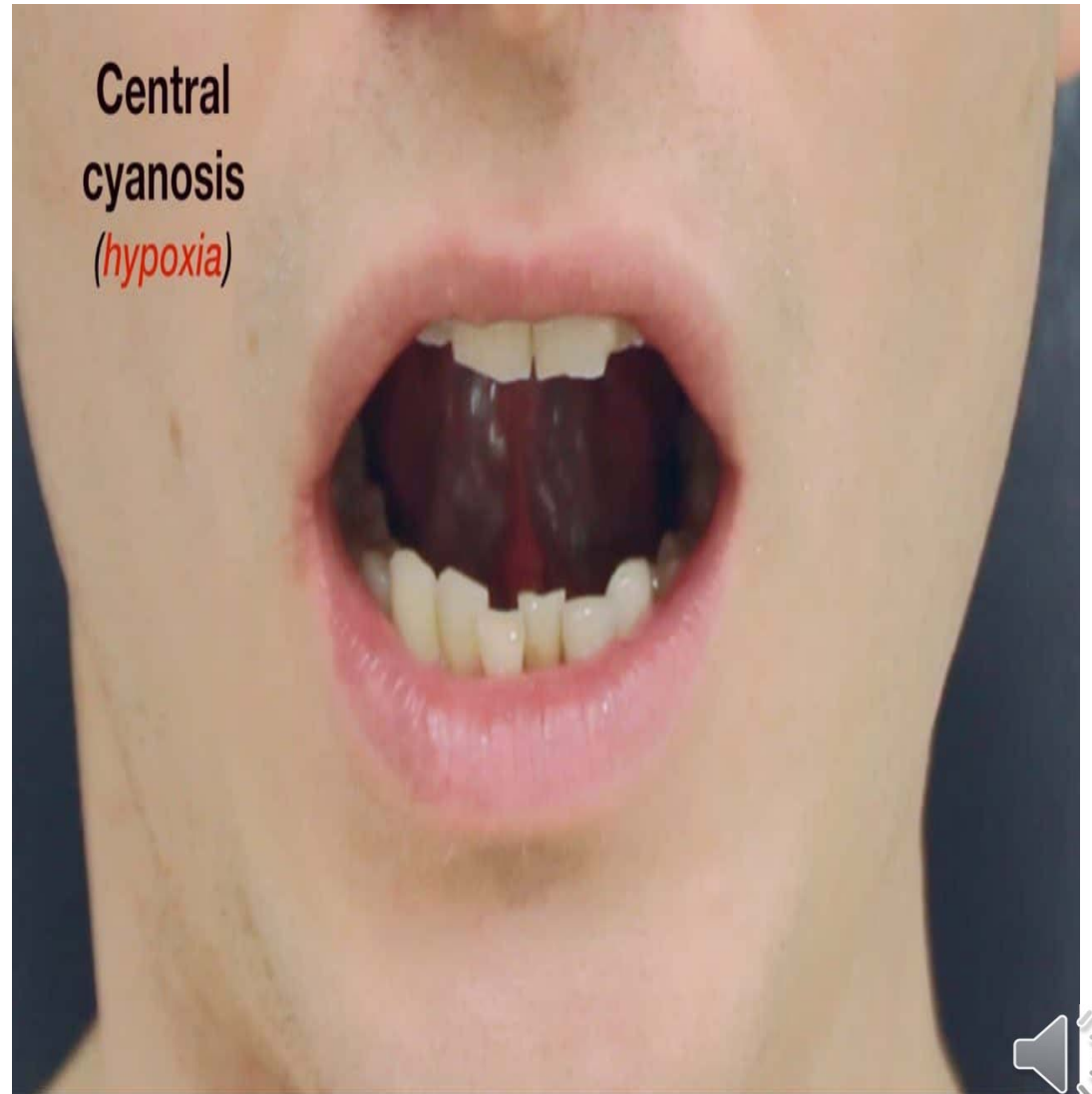


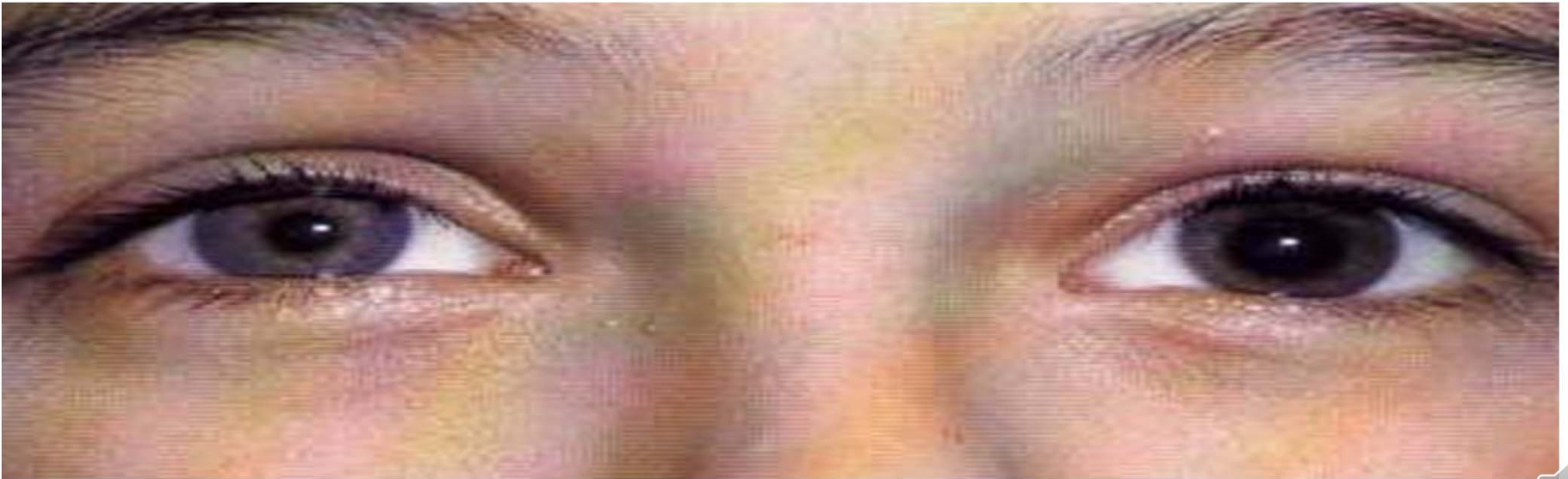Fig. 7.5 Central cyanosis of the tongue.



Central
cyanosis
(hypoxia)

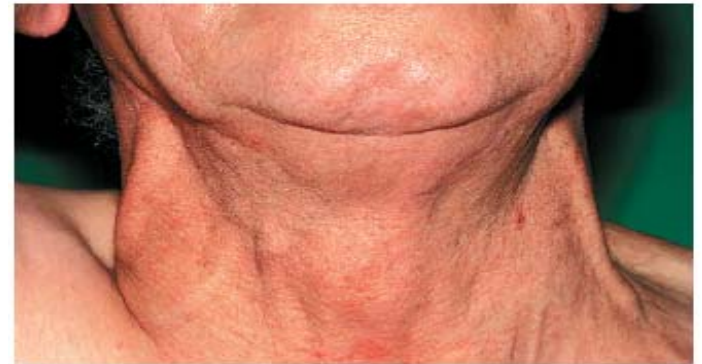Horner's syndrome

- ❖ Tumor at the root of the neck may disrupt the sympathetic nerves to the eye
- ❖ Causes unilateral ptosis and pupillary constriction

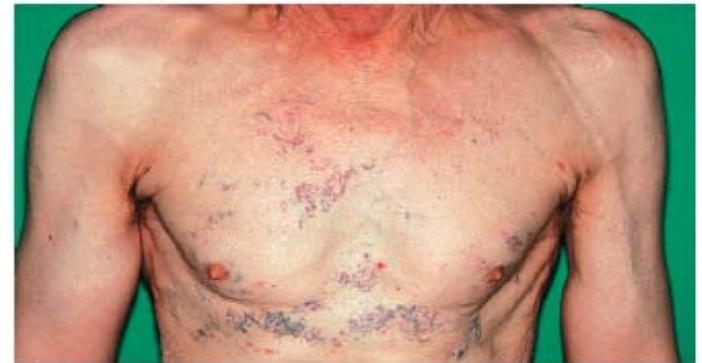

Superior vena cava obstruction

- ❖ Usually indicates tumor invasion of the upper mediastinum.
- ❖ Causes dusky generalized swelling of the head, neck and face with subconjunctival edema.



A



B

Fig. 7.11 Superior vena caval obstruction. (A) Distended neck veins. **(B)** Dilated superficial veins over chest.



Neck

- ❖ Support the patients head with a pillow
- ❖ Examine JVP (JVP is a reflection of right atrial pressure)
- ❖ Examine cervical LN from behind with the patient sitting forward (Scalene LN which is matted in TB)



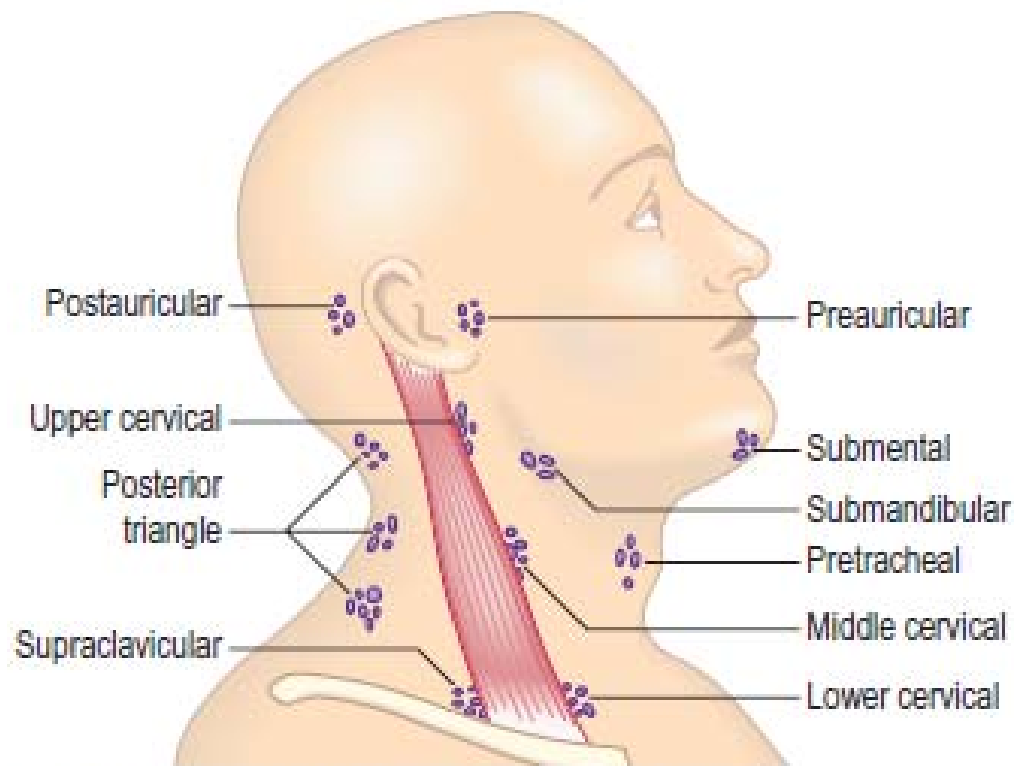


Fig. 7.12 The lymph node groupings in the neck.



Thorax

Inspection

Palpation

Percussion

Auscultation



Inspection

- From the foot of the bed:

Shape

symmetry

pattern of breathing

chest deformities, AP diameter

- From the side of the patient:
Visible Scars (Thoracotomy scar)

Drains

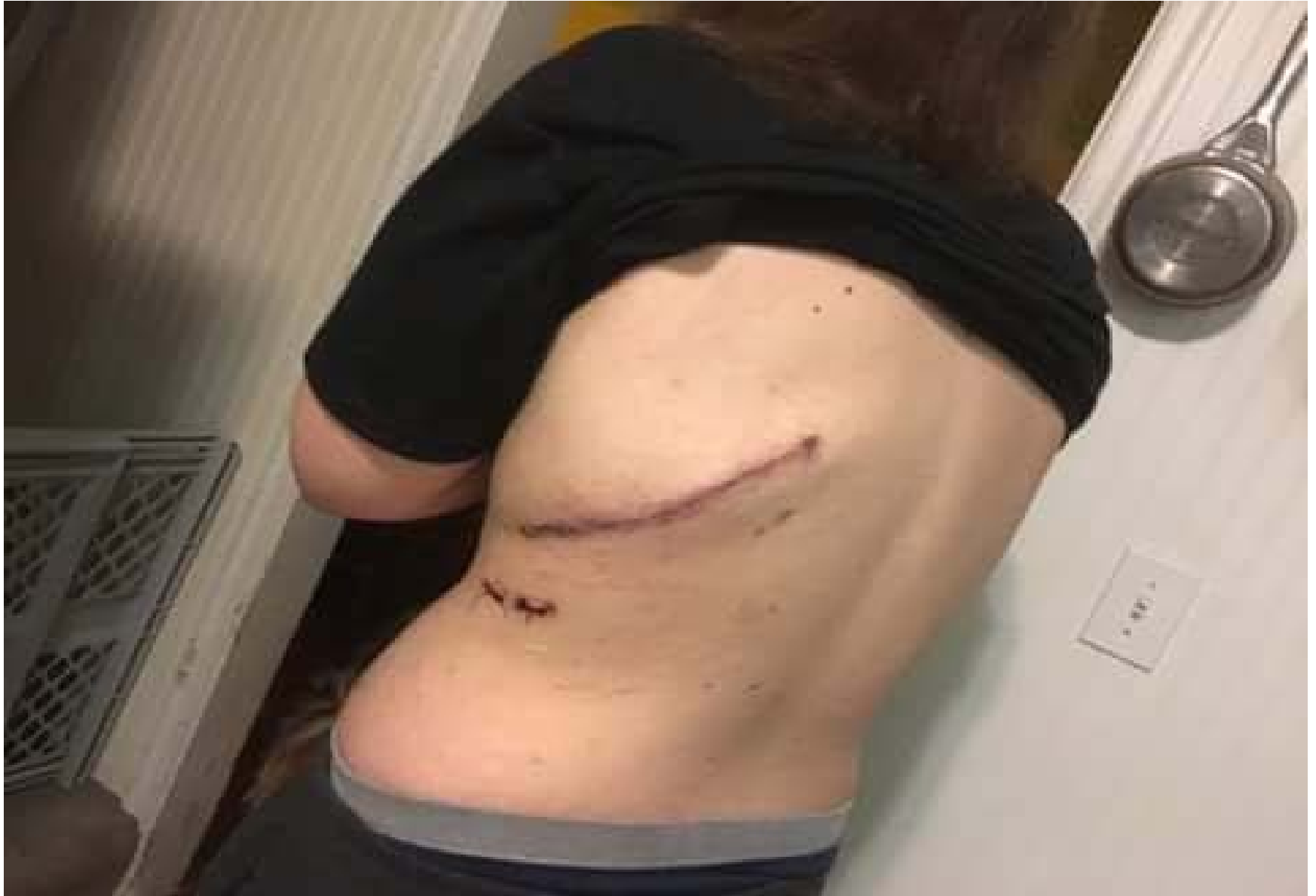Skin lesions

Superficial masses or swellings

Dilated veins

Axilla

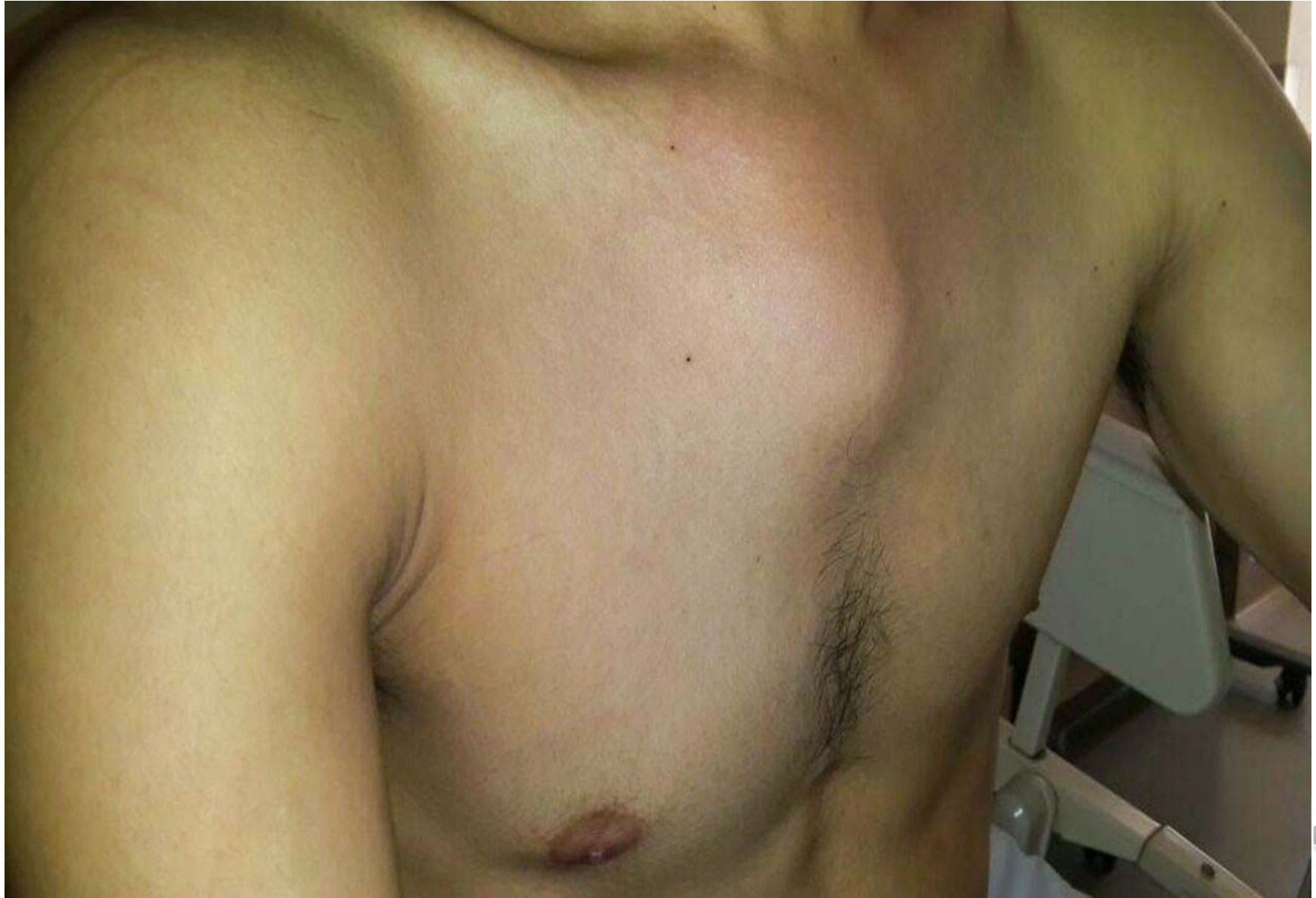



Palpation (try to move your hand over chest wall without gaps)

- ❖ Superficial palpation (superficial masses, superficial tenderness, SC emphysema)
- ❖ Examination of Trachea (upper mediastinum)
- ❖ Apex beat examination (lower mediastinum)
- ❖ Palpate for right ventricular heave
- ❖ Tactile vocal fremitus
- ❖ Assess thoracic expansion



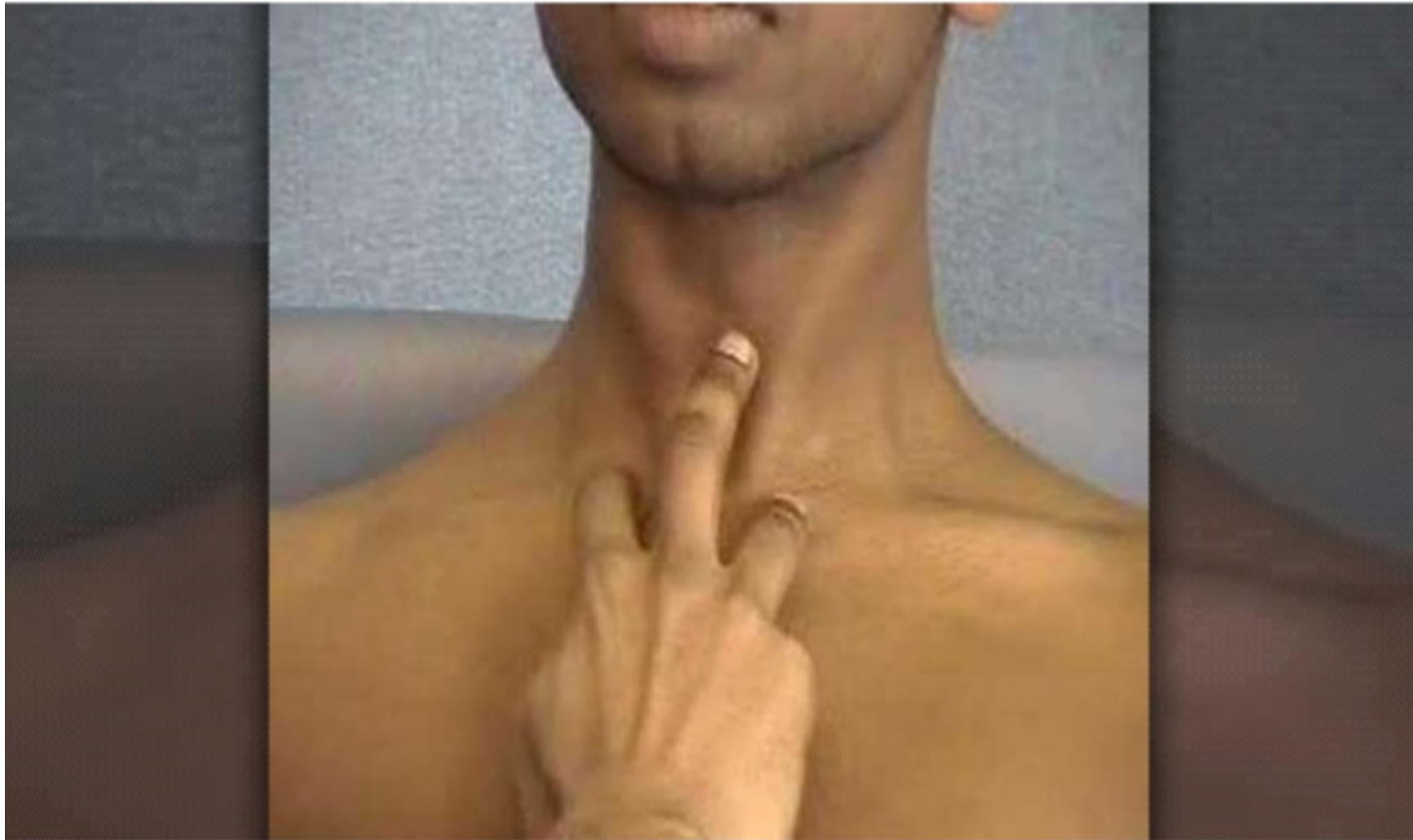


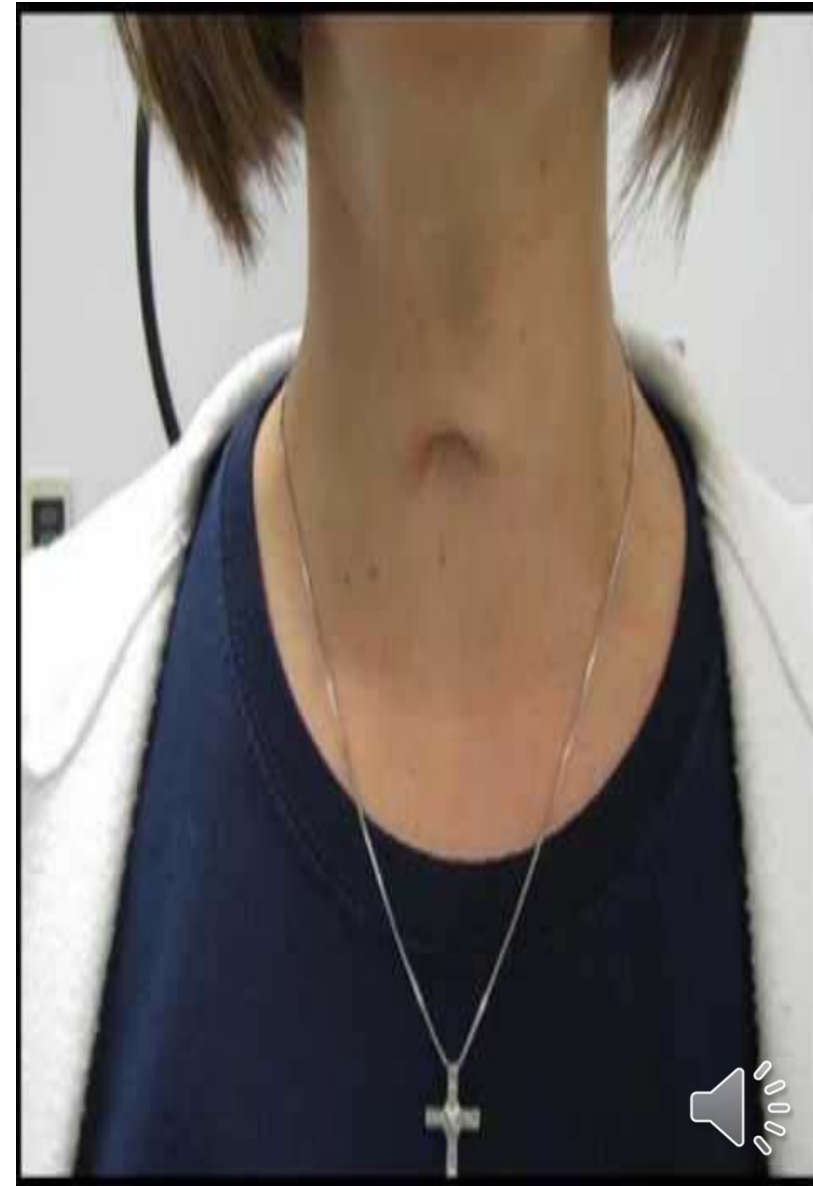
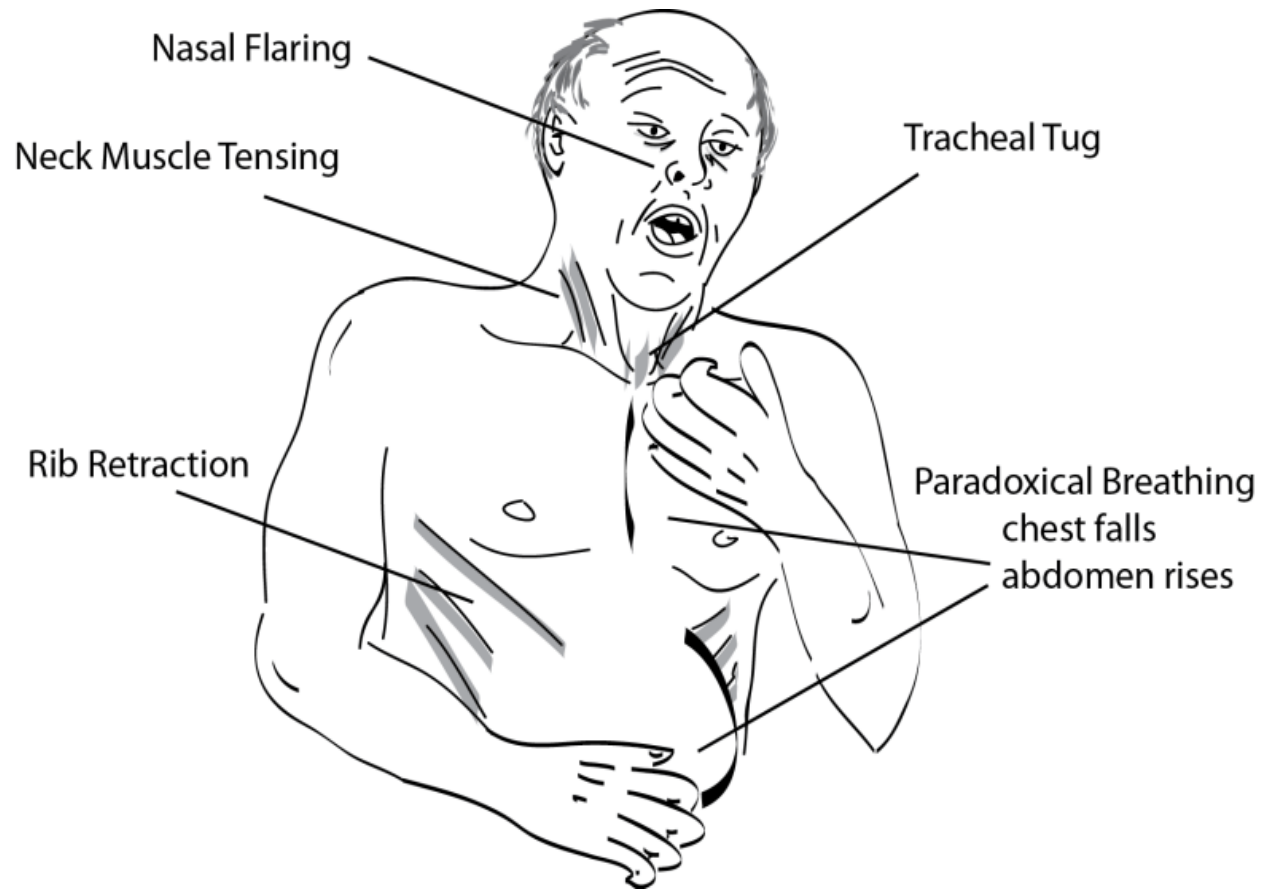
Examination of Trachea

- ❖ Check for tracheal deviation by gently advancing a single finger resting in the sternal notch in the midline, if the finger tip meets the centre of the trachea then it is not deviated
- ❖ Check the cricosternal distance (the vertical distance between the sternal notch and the cricoid cartilage). Normally up to 5 cm!
- ❖ Tracheal tug

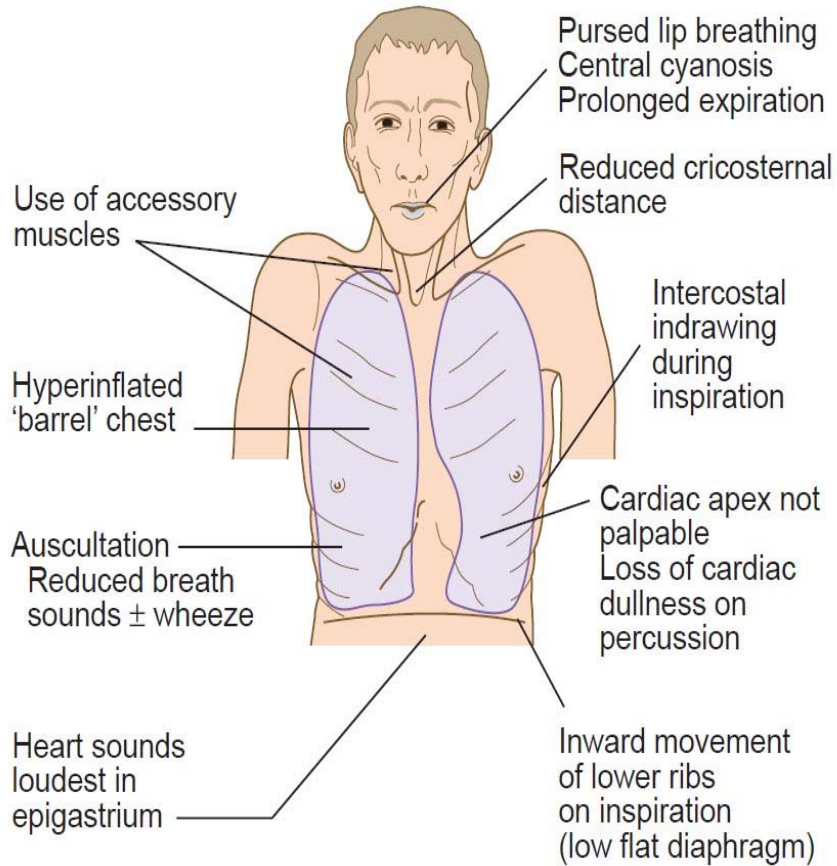


Position of Trachea



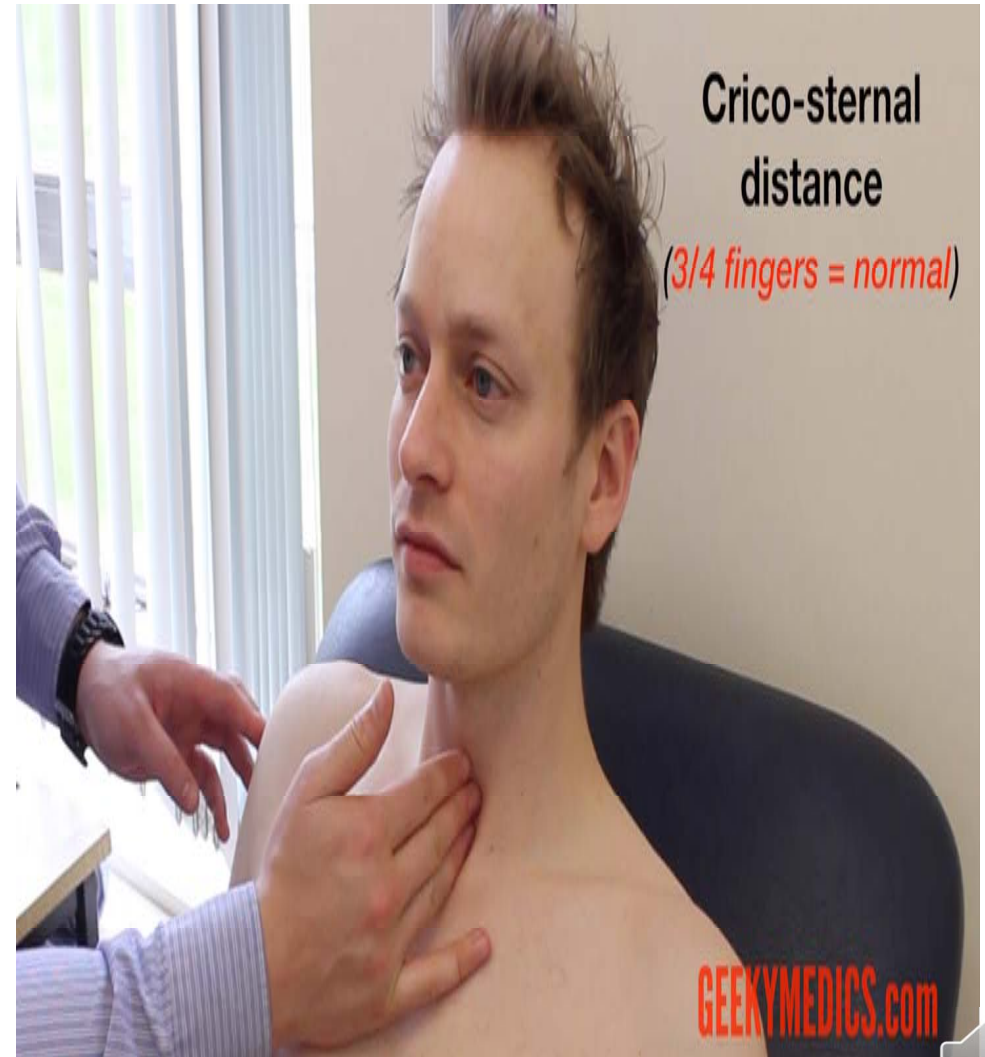

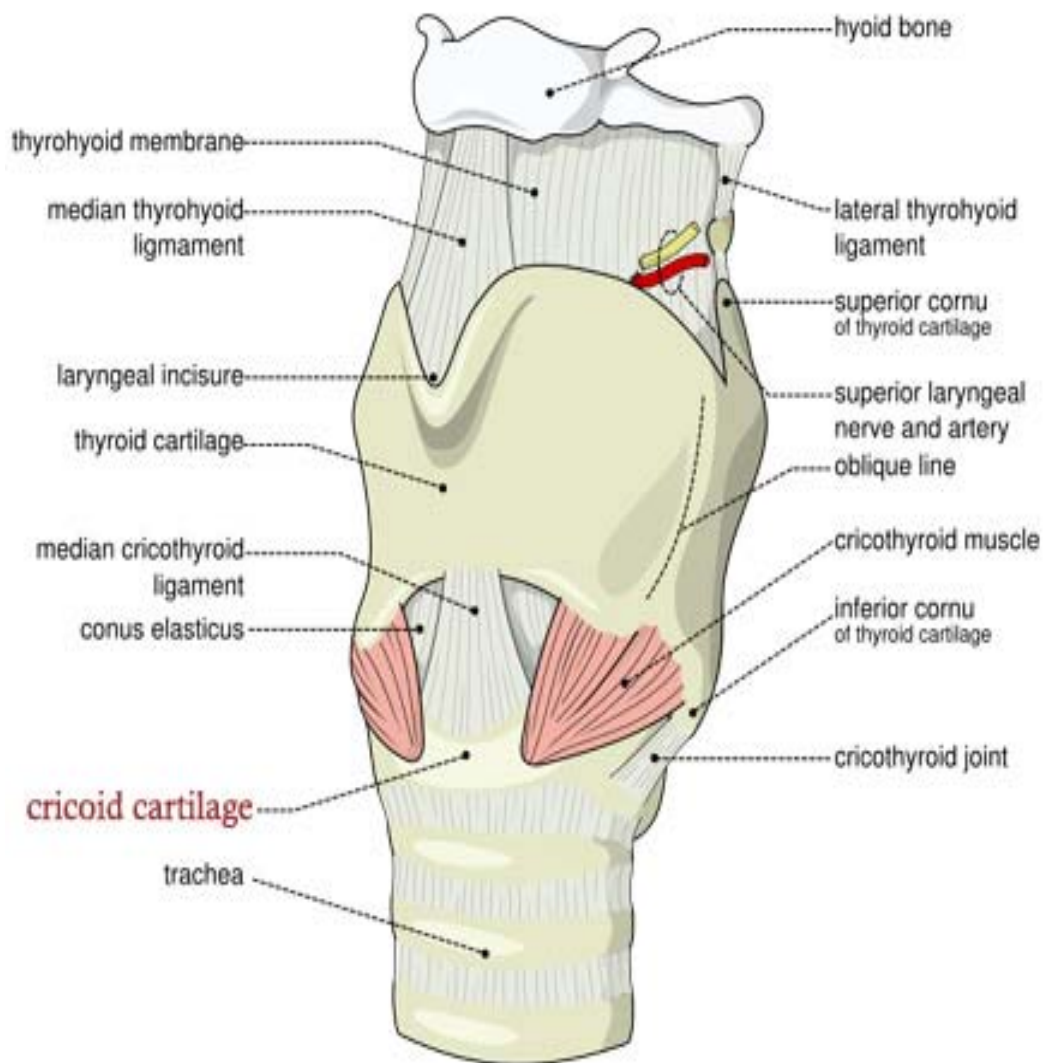
Chronic obstructive pulmonary disease



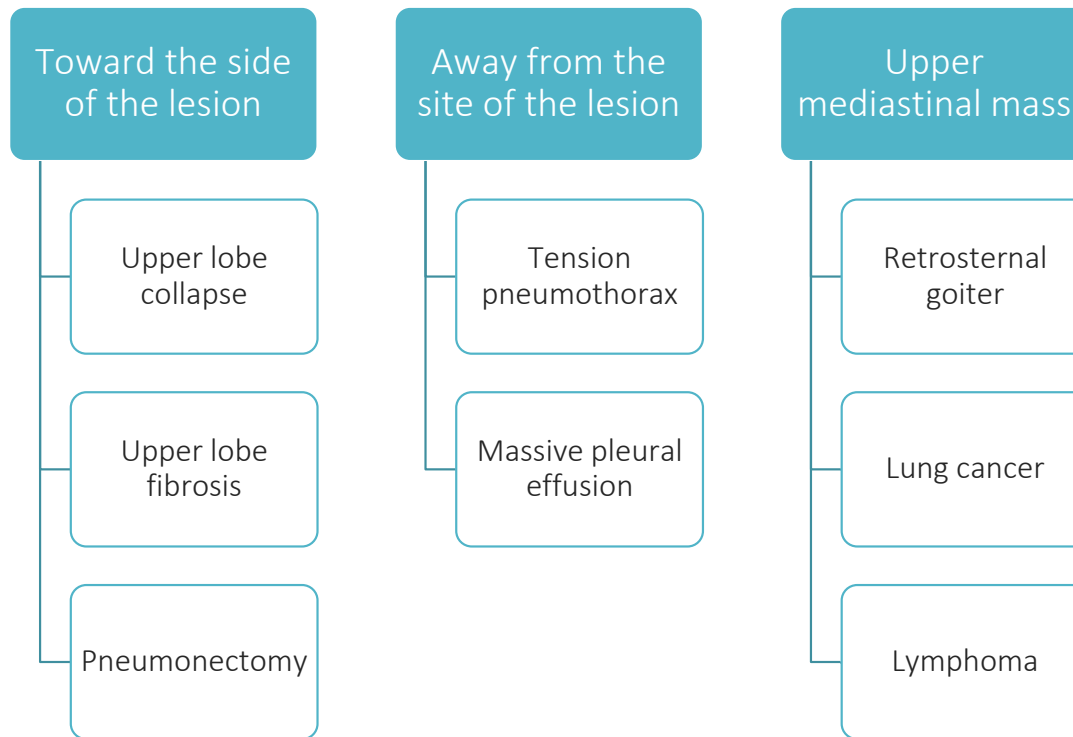
Key features on examination in COPD.

Source : Davidson's Essentials of Medicine 2e





Tracheal deviation



❖ Apex beat: **5th ICS in midclavicular line (palm of fingers then localize with 1 finger)**

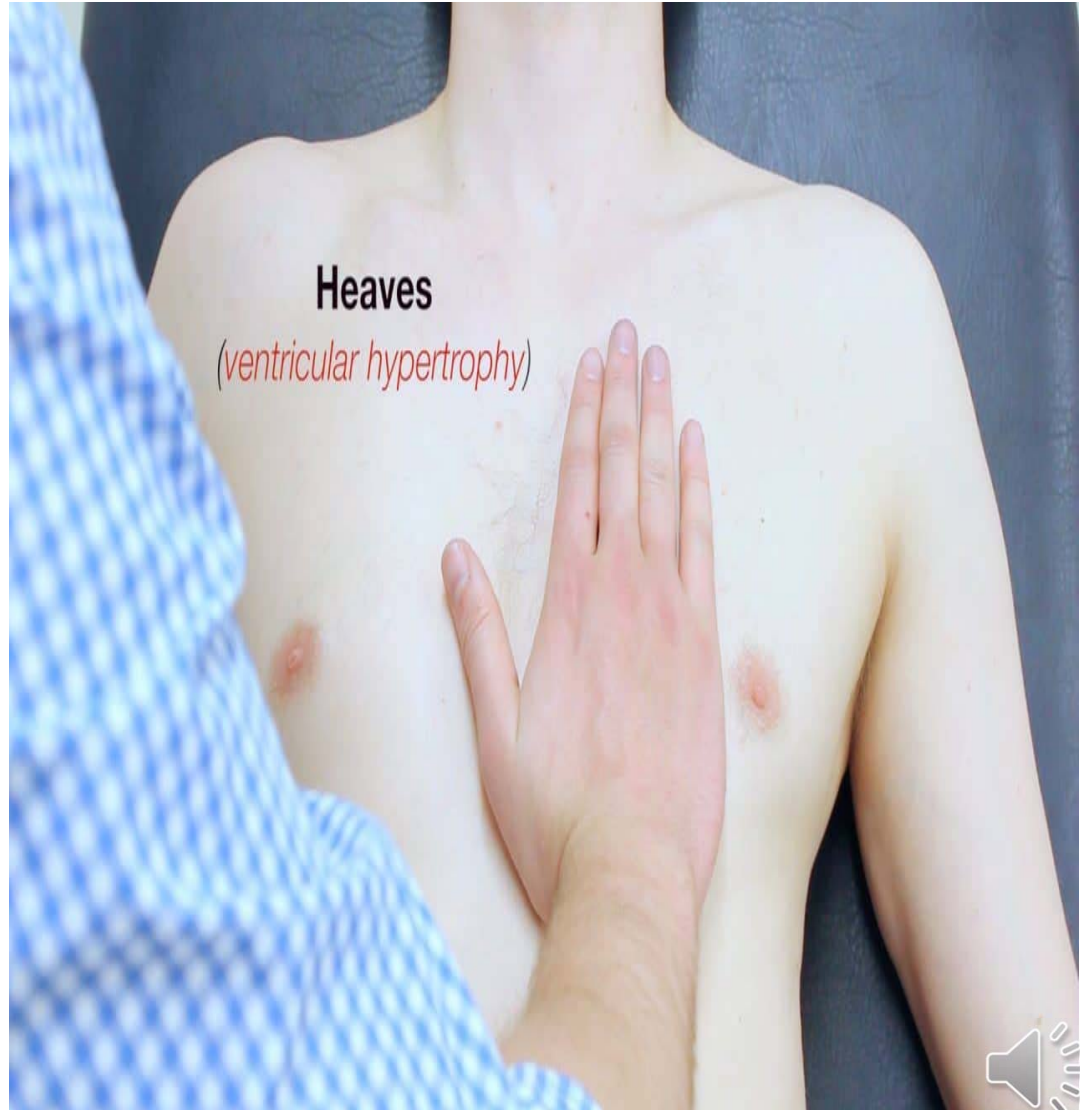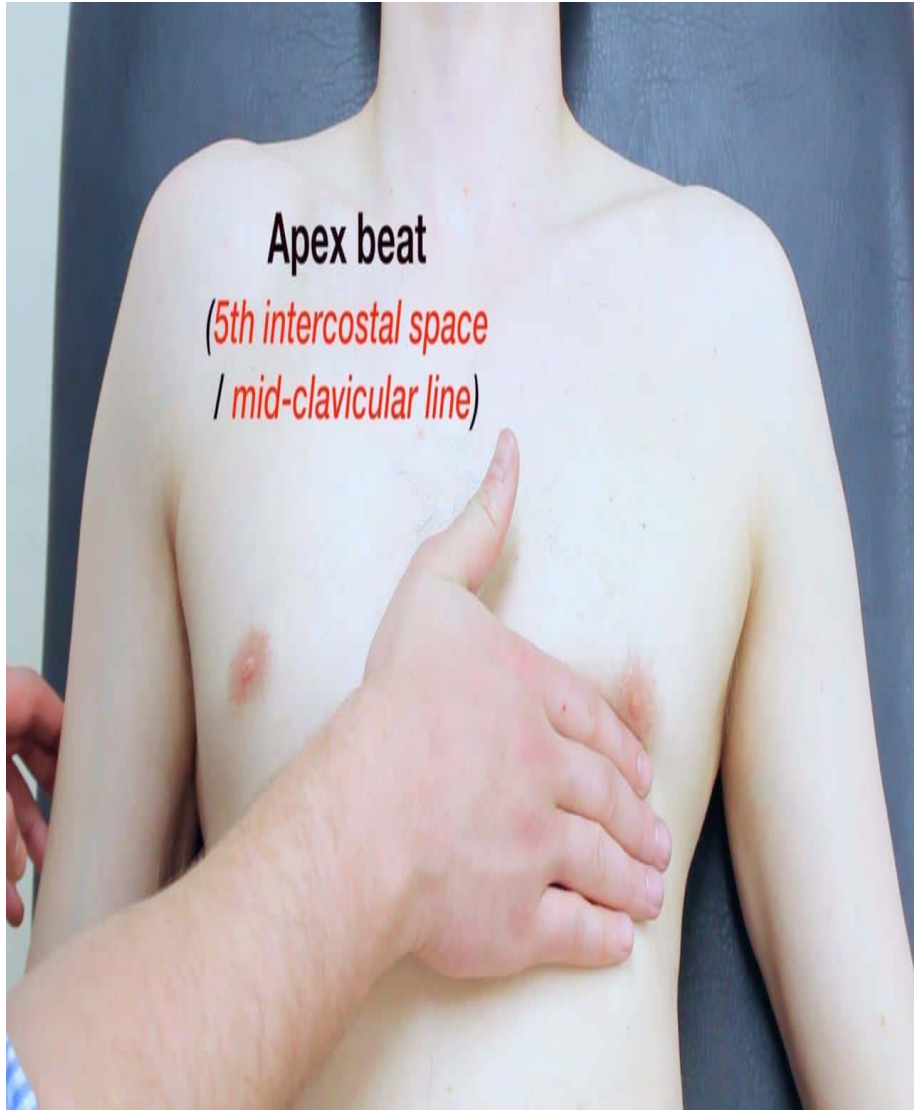Displaced by dilatation of ventricle or displacement of lower mediastinum

Impalpable in hyperinflation in obstructive lung disease when the lingula comes between the heart and the chest wall (due to hyperinflation)

❖ Right ventricular heave: (**use a straight arm with the palm over the left lower sternum**)

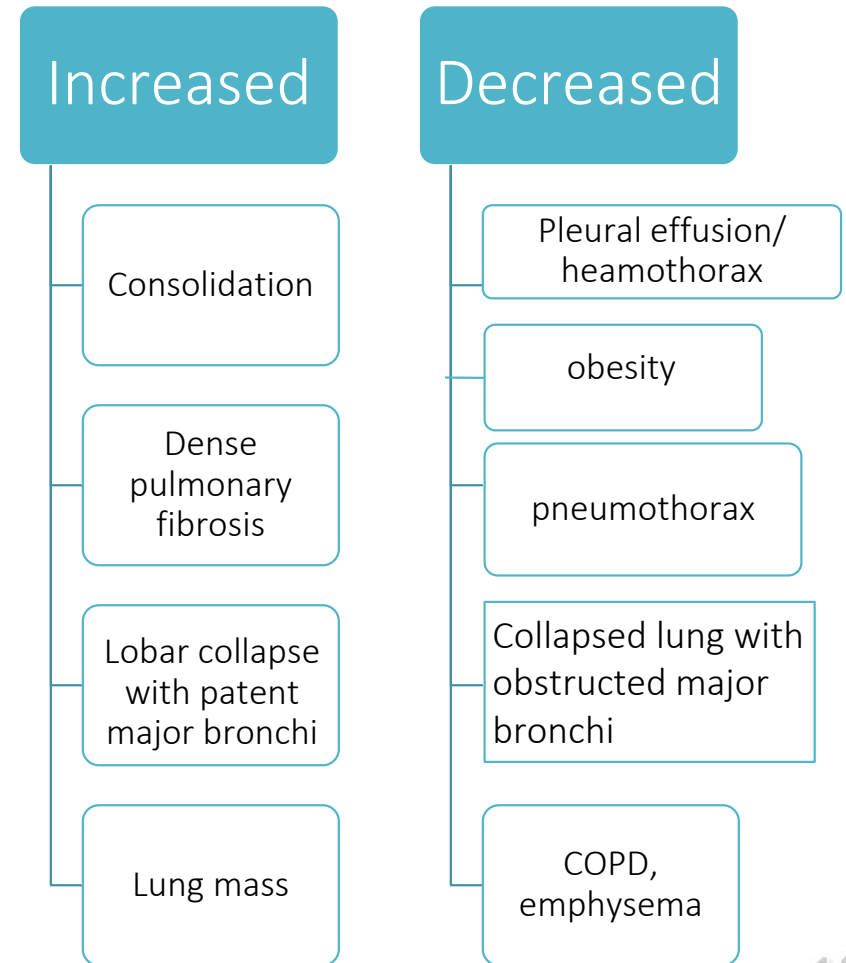
found in severe pulmonary hypertension, is best felt at the left sternal edge

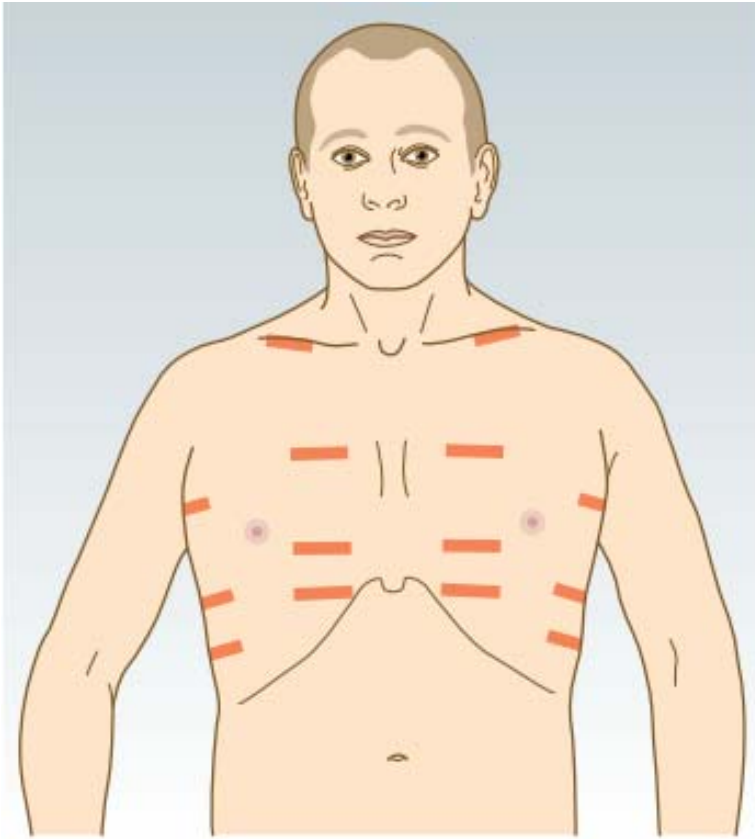




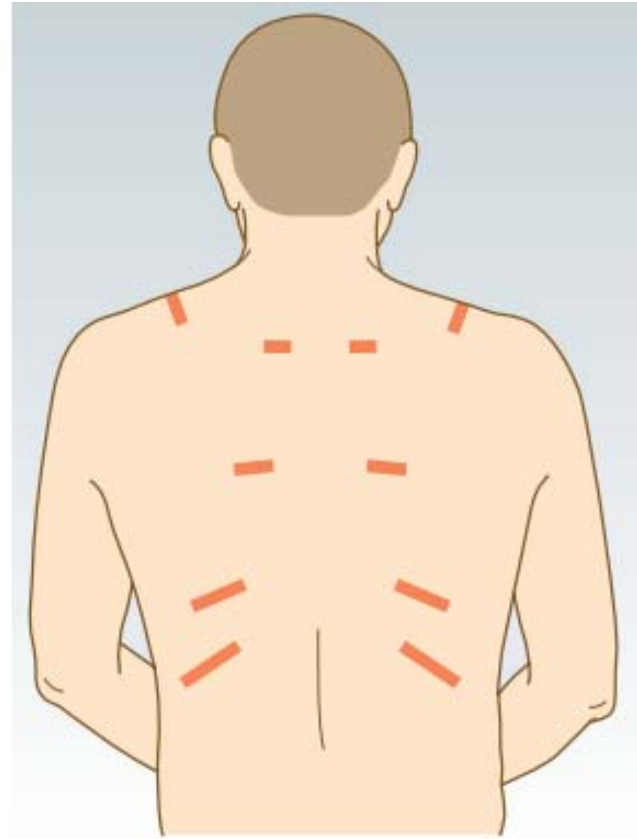
Tactile vocal fremitus

- ❖ Is the palpable vibration (of non vascular origin) that reaches the body surface during low frequency vocalization and is felt by examiner's palms.
- ❖ Sound waves travels faster and is conducted better in solid media rather than air/fluid.
- ❖ Palpate the chest wall with palm of hand while patient repeats one, one, one.
- ❖ The cause of change in vocal fremitus is same as these for vocal resonance.





B



Chest expansion

- ❖ Normally; Both sides of the thorax should expand equally during normal breathing and ribs move out and up with inspiration.
- ❖ Reduced expansion on one side indicates abnormality on that side: for example, pleural effusion, lung or lobar collapse, pneumothorax and unilateral fibrosis.
- ❖ Bilateral reduction in chest wall movement is common in severe COPD and diffuse pulmonary fibrosis.
- ❖ Paradoxical inward movement may indicate diaphragmatic paralysis or, more commonly, severe COPD.
- ❖ **Assess chest expansion in upper and lower anterior chest exam and just on one level in posterior chest exam**



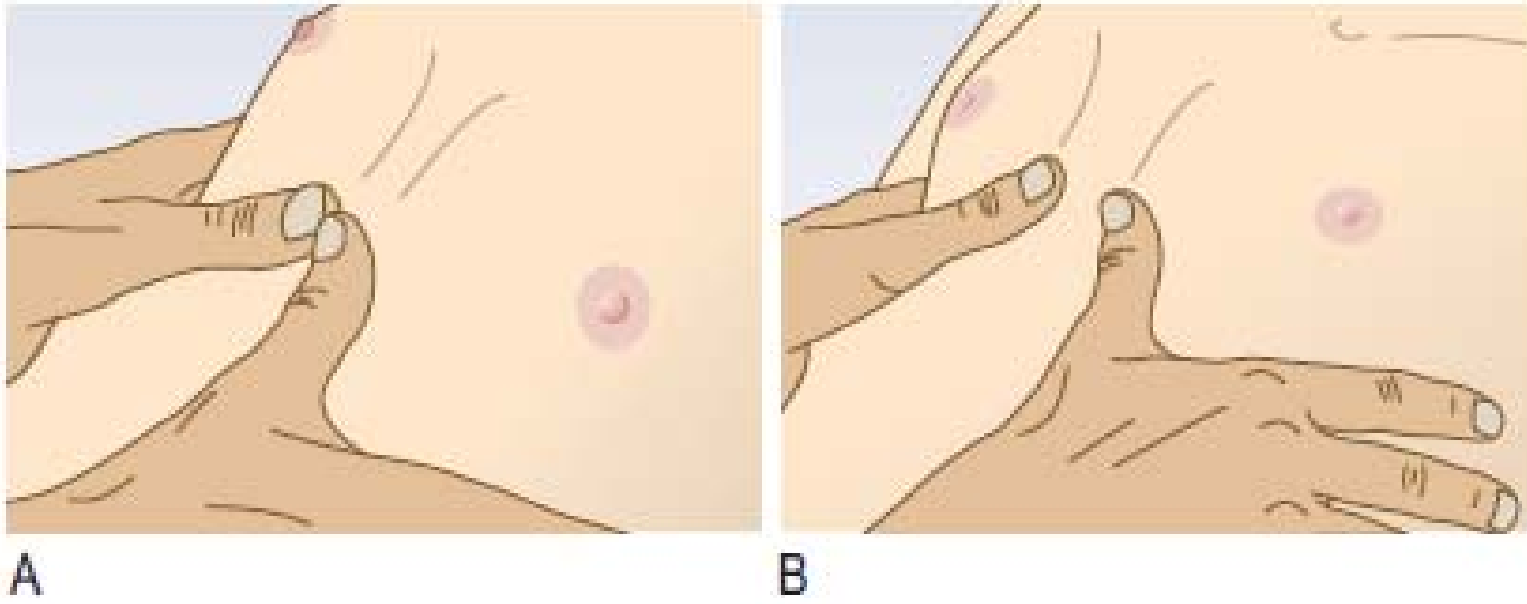
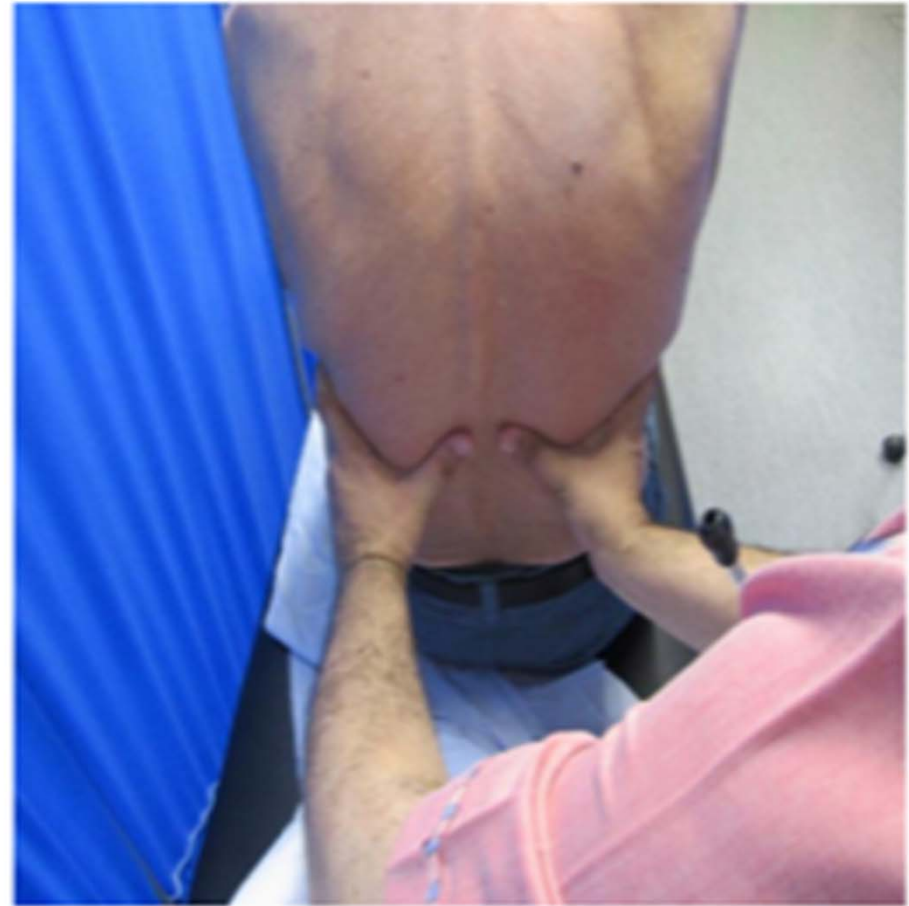
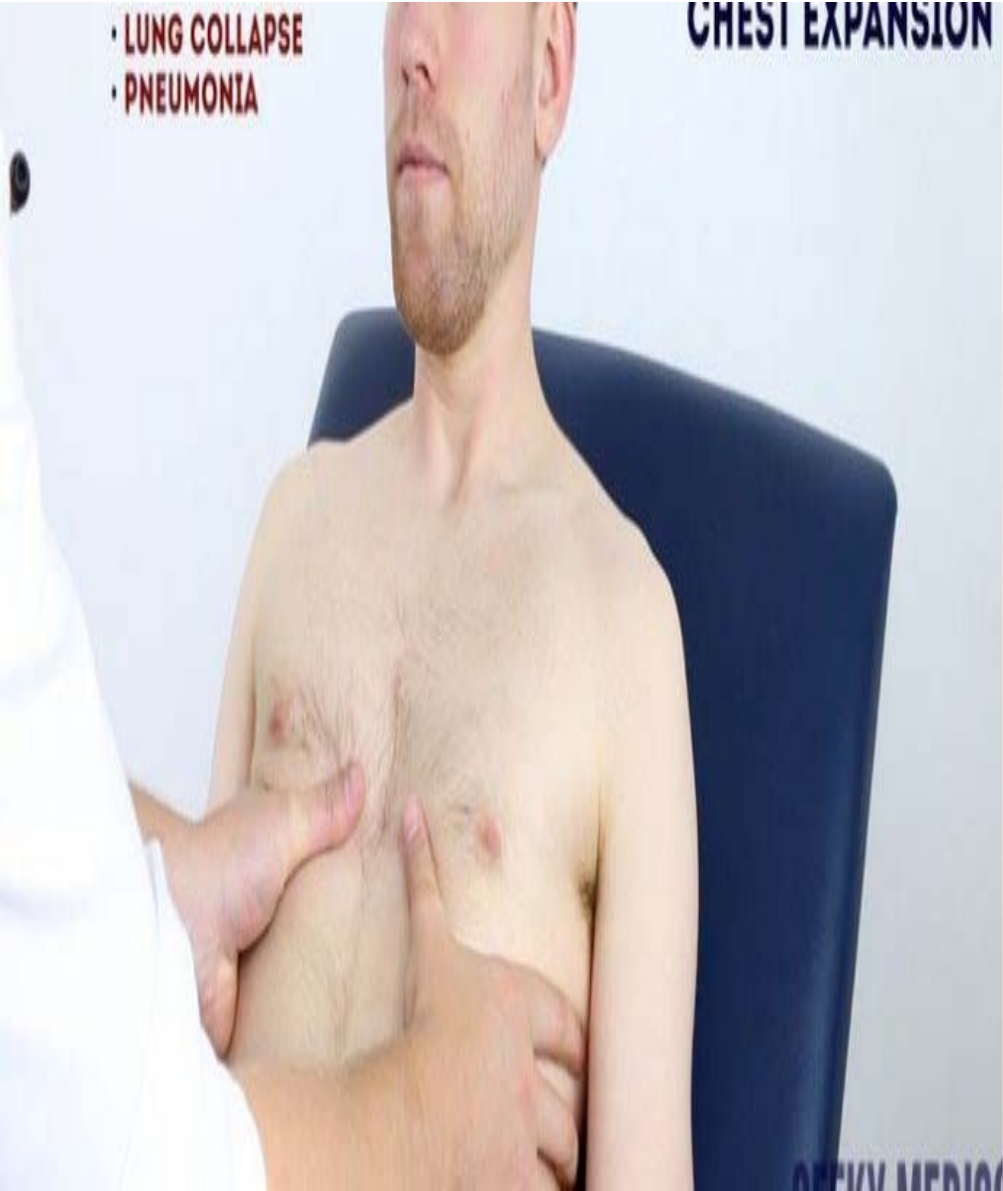

Fig. 7.16 Assessing chest expansion from the front. (A) Expiration. (B) Inspiration.



- LUNG COLLAPSE
- PNEUMONIA

CHEST EXPANSION



Back : Lower chest



Percussion

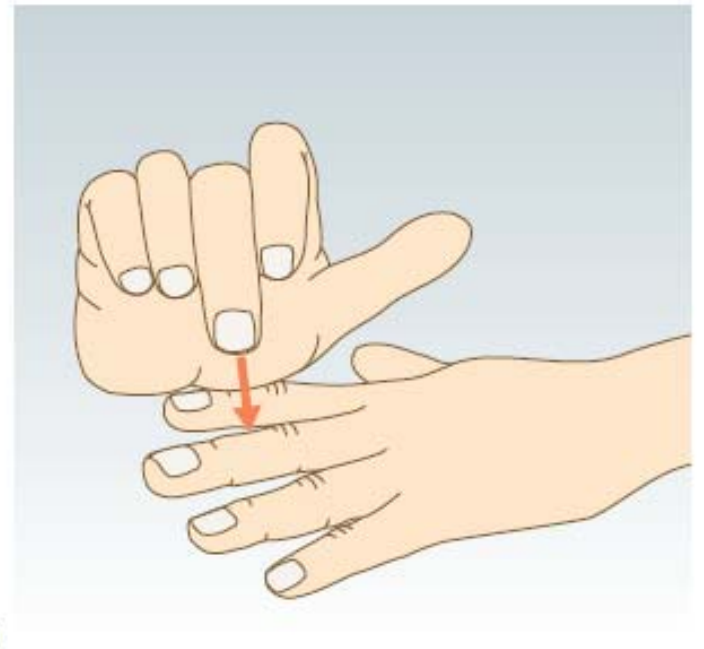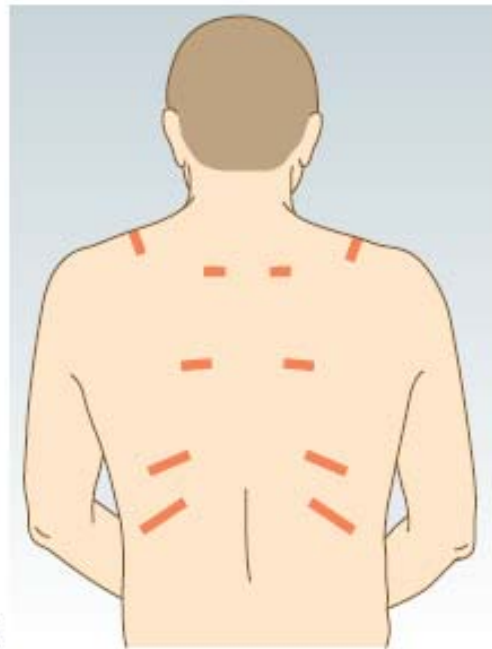
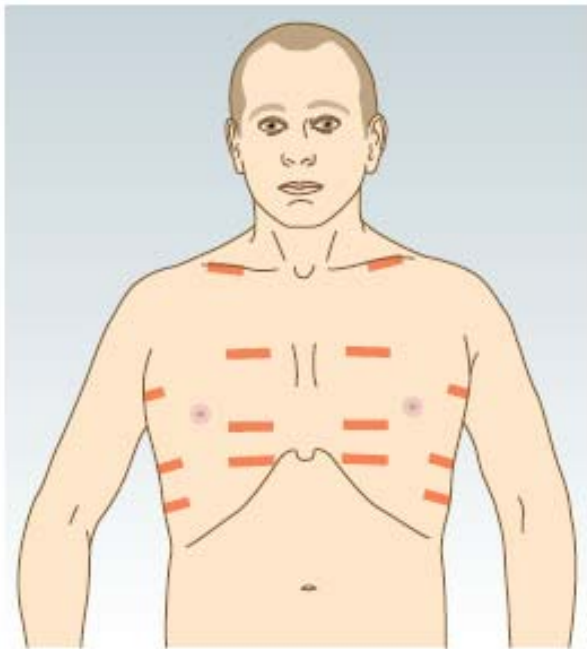
- ❖ Tapping on a surface to determine the underlying structure, it allows to listen for the pitch and loudness of the percussed note.
- ❖ The palm of the left hand is placed on chest and finger separated, the middle finger of the left hand is pressed firmly aligned with the underlying ribs
- ❖ Strike the centre of the middle phalanx of the left middle finger with the tip of the right middle finger



Percussion

- ❖ Percuss in sequence, comparing areas on the right with corresponding areas on the left before moving to the next level.
 - ❖ Posteriorly; the scapular and spinal muscles obstruct percussion. Don't percuss near the midline, percuss few cm lateral to the spinal muscles.
-
- Direct percussion on clavicle
 - Move your wrist not your elbow
 - Don't forget to percuss over the Trapezius muscle in anterior and posterior chest exam because it represents lung apex





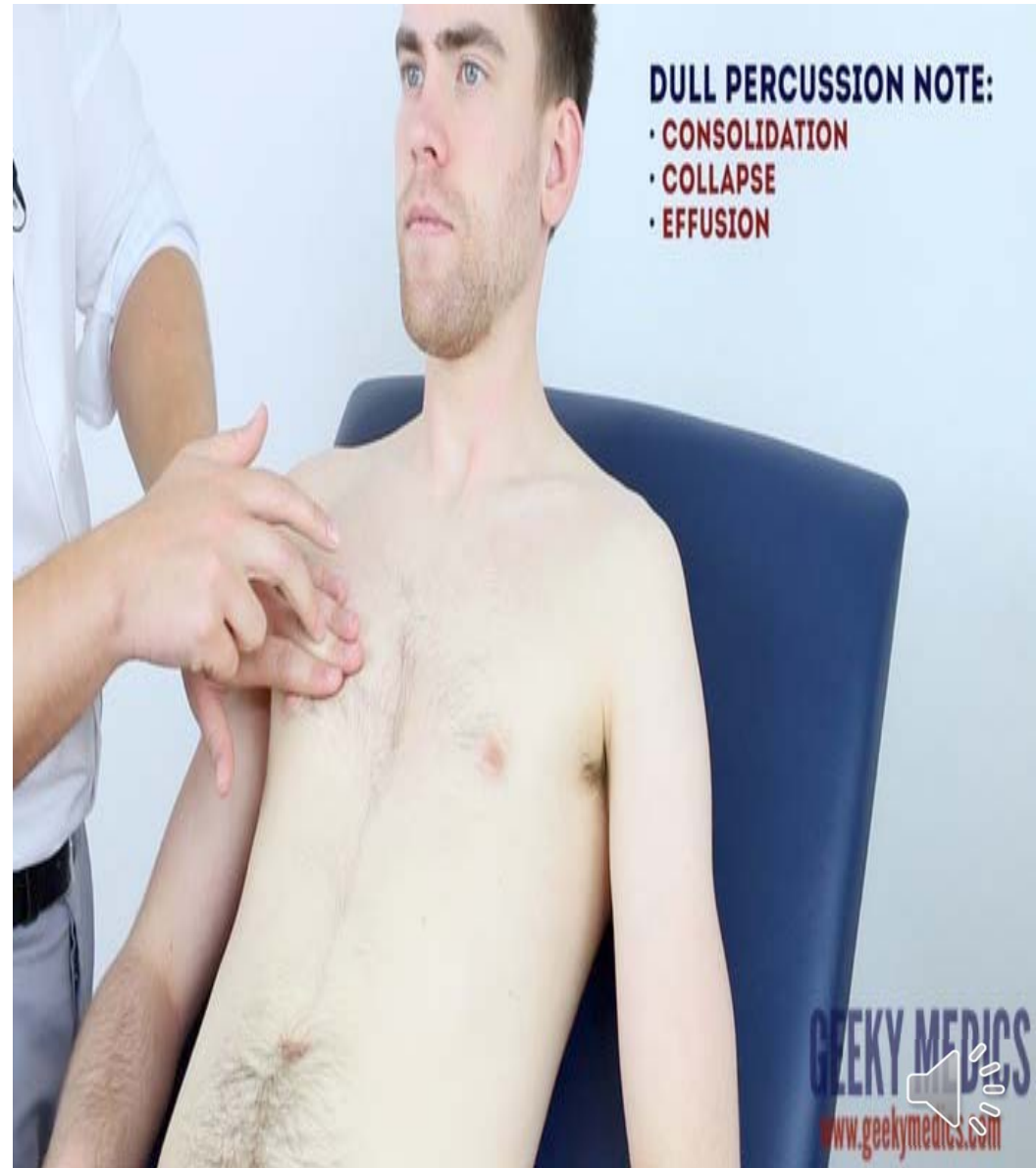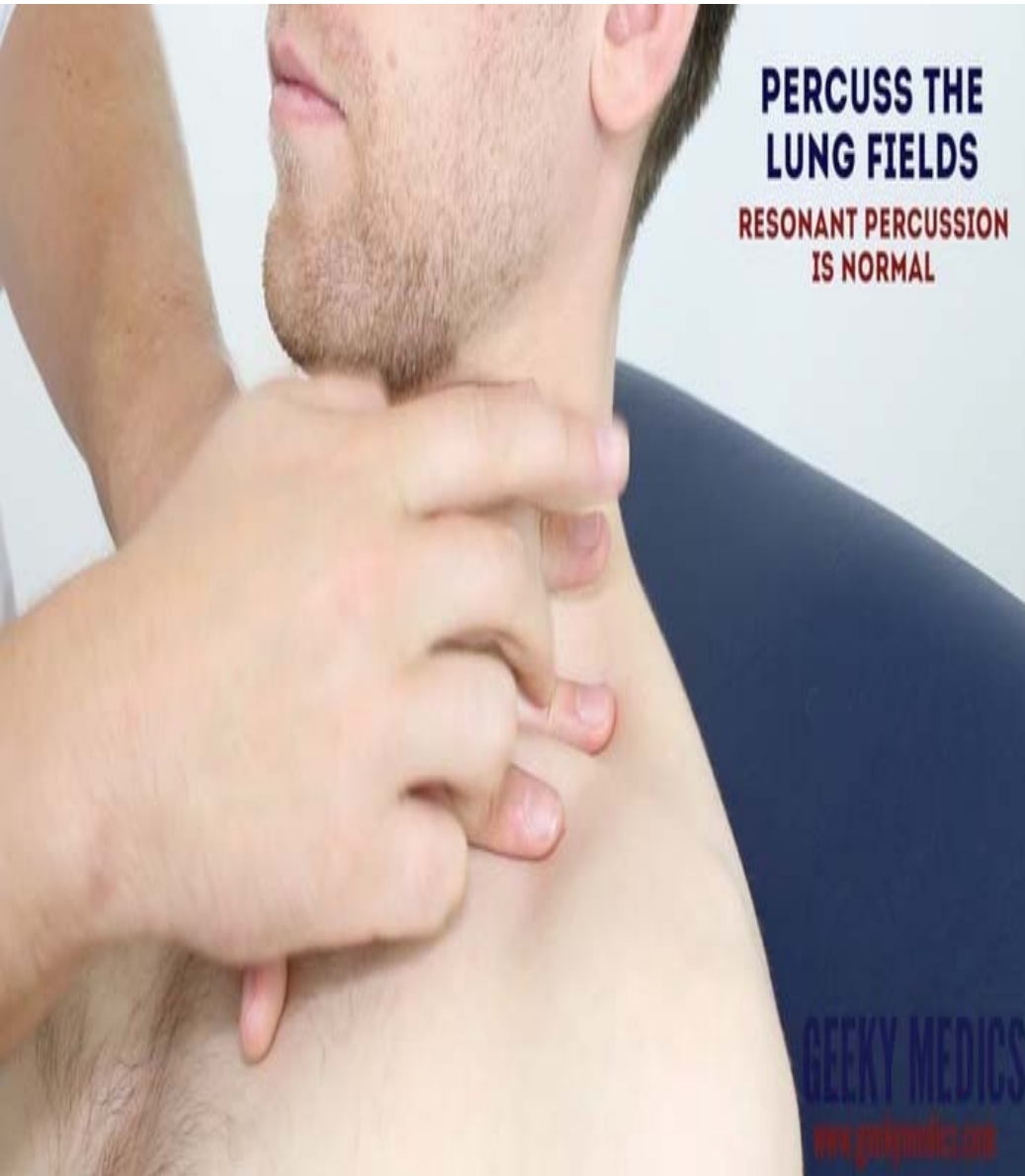
A

B

C

Fig. 7.18 Sites for percussion. (A) Anterior and lateral chest wall. (B) Posterior chest wall. (C) Technique of percussion.





Percussion note

Resonant

- Normal lung

Hyperresonant

- Pneumothorax

Dull

- Pulmonary consolidation
- Pulmonary collapse
- Severe pulmonary fibrosis

Stony dull

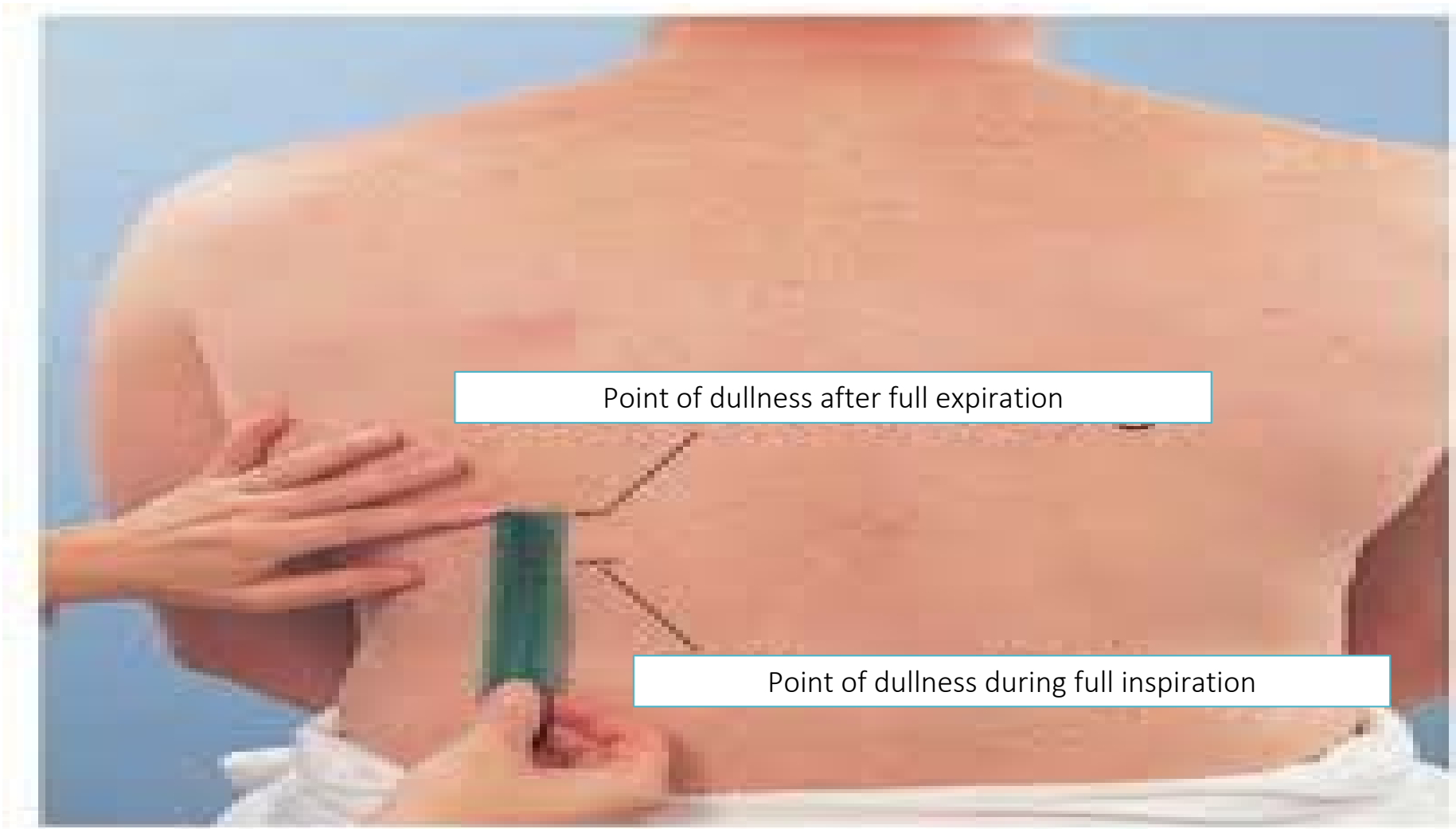
- Pleural effusion
- Haemothorax



Diaphragmatic excursion

- ❖ Assess the movement of the thoracic diaphragm during breathing.
- ❖ The provider percusses down the back of the patient in the intercostal margins, starting below the scapula, after deep expiration, until sounds change from resonant to dull. Then the patient takes a deep breath in and holds it as the provider percusses down again, marking the spot where the sound changes from resonant to dull again. Then the provider will measure the distance between the two spots.
- ❖ Repeat on the other side, is usually higher up on the right side.
- ❖ Normal diaphragmatic excursion should be 5-8 cm. If it is less then the patient may have pneumonia or pneumothorax.





Point of dullness after full expiration

Point of dullness during full inspiration



Auscultation

- ❖ Breath sounds
- ❖ Added sounds
- ❖ Vocal resonance
- ❖ Whispering pectoriloquy
- ❖ Aegophony



Auscultation

Listen with the patient relaxed and breathing deeply through his open mouth. Avoid asking him to breathe deeply for prolonged periods, as this causes giddiness and even tetany.

Auscultate each side alternately, comparing findings over a large number of equivalent positions to ensure that you do not miss localized abnormalities.

Listen [using the diaphragm of the stethoscope](#):

- anteriorly from above the clavicle down to the sixth rib
- laterally from the axilla to the eighth rib
- posteriorly down to the level of the 11th rib.
- Assess the quality and amplitude of the breath sounds.



Auscultation

Identify any gap between inspiration and expiration, and listen for added sounds. Avoid auscultation within 3 cm of the midline anteriorly or posteriorly, as these areas may transmit sounds directly from the trachea or main bronchi.

You should comment on:

Determine whether you hear Bronchial or vesicular breathing

If there is good bilateral air entry or reduced air entry

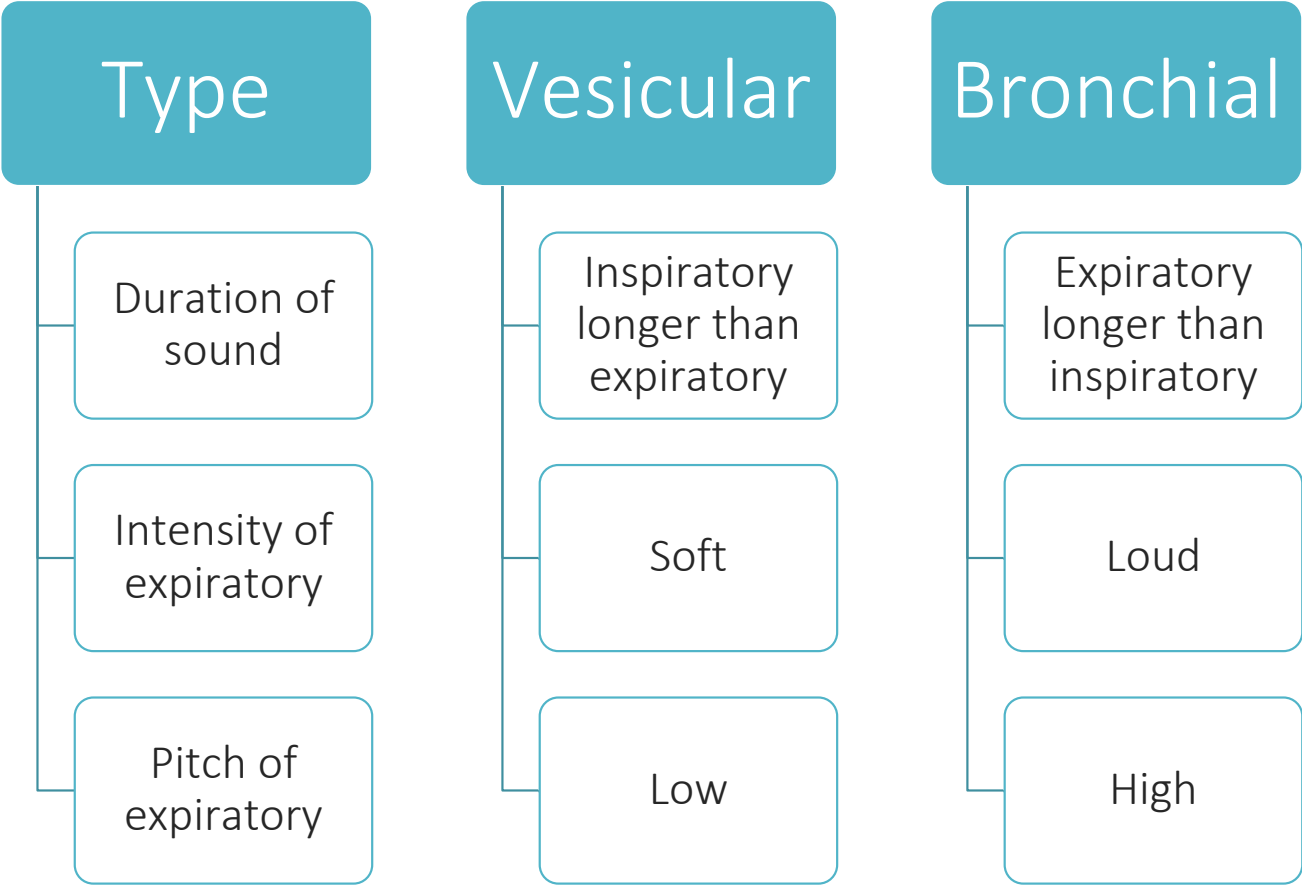
If the air entry is symmetrical or not

If there is prolonged expiration

If you hear Added sounds



Breathing sounds



Breathing sounds

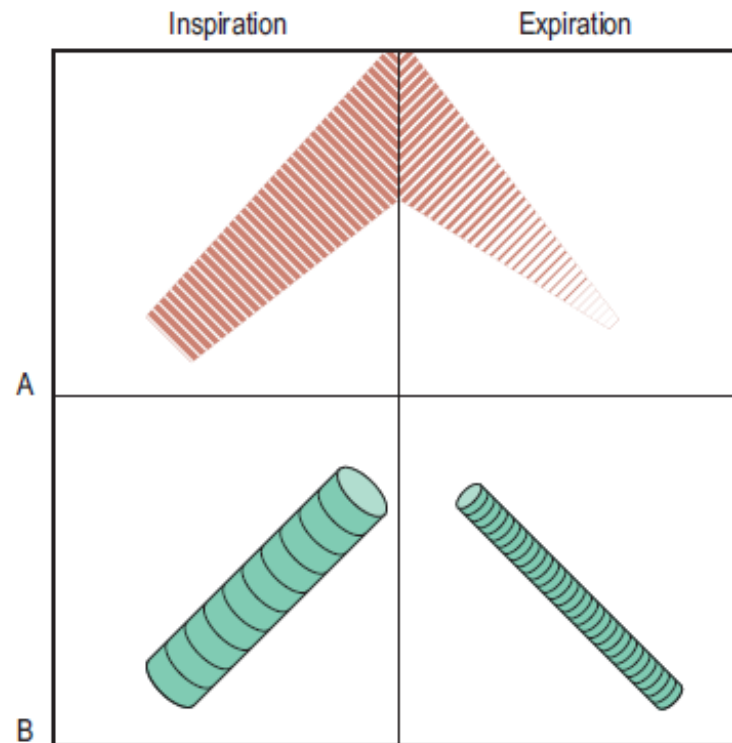


Fig. 7.19 Diagrammatic representation of breath sounds.

(A) Vesicular. **(B)** Bronchial. Note the gap between inspiration and expiration and change in pitch and the blowing, tubular quality of bronchial breath sounds.



Causes of diminished vesicular breathing

Reduced conduction

Reduced flow

Pneumothorax

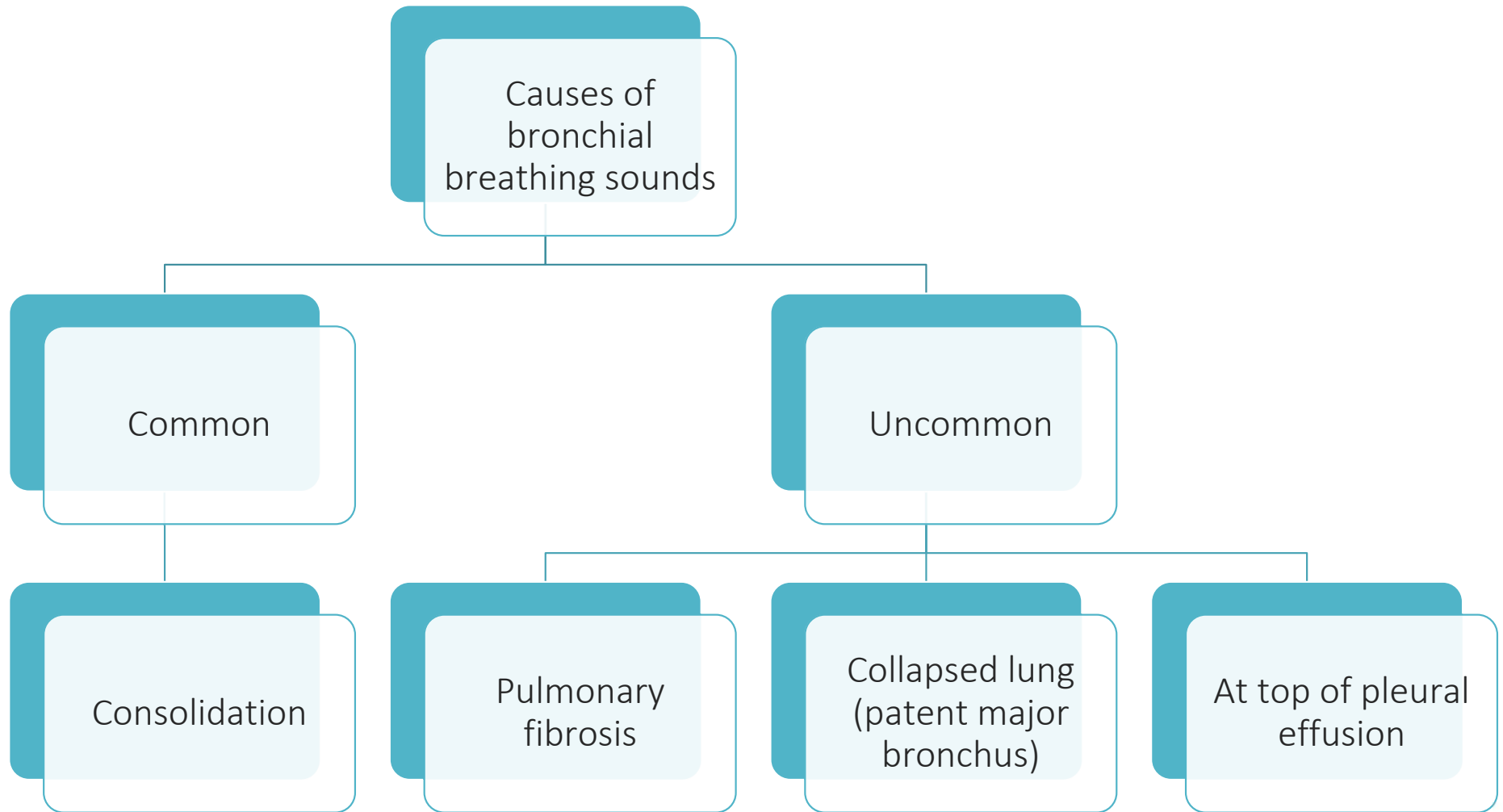
Pleural effusion

Obesity/ thick chest wall

Generalized: COPD

Localized: collapsed lung due to lung cancer occluding major bronchus





Added sounds

Wheezes

Crackles

Rubs



Wheezes

- ❖ Musical whistling sound accompanying airflow and usually originates in narrowed small airways.
- ❖ Most commonly expiratory due to dynamic airway narrowing.
- ❖ Polyphonic vs. monophonic.



Crackles

- ❖ Sudden opening of small airways but may indicate secretions in the airways or fibrosis
- ❖ crackles are graded into Fine (soft multiple crackles) to coarse (loud and scanty)

Phase of inspiration	Cause
Early	Small airways disease, as in bronchiolitis
Middle	Pulmonary oedema
Late	Pulmonary fibrosis (fine) Pulmonary oedema (medium) Bronchial secretions in COPD, pneumonia, lung abscess, tubercular lung cavities (coarse)
Biphasic	Bronchiectasis (coarse)



Pleural rub

- ❖ Rasping grating sound with each breath.
- ❖ Indicates pleural inflammation, usually due to infection and often accompanied by Pleuritic chest pain.



Vocal resonance, whispering pectoriloquy, Aegophony

- ❖ Ask the patient to say “one, one, one” while you auscultate to assess the quality and amplitude of vocal resonance.

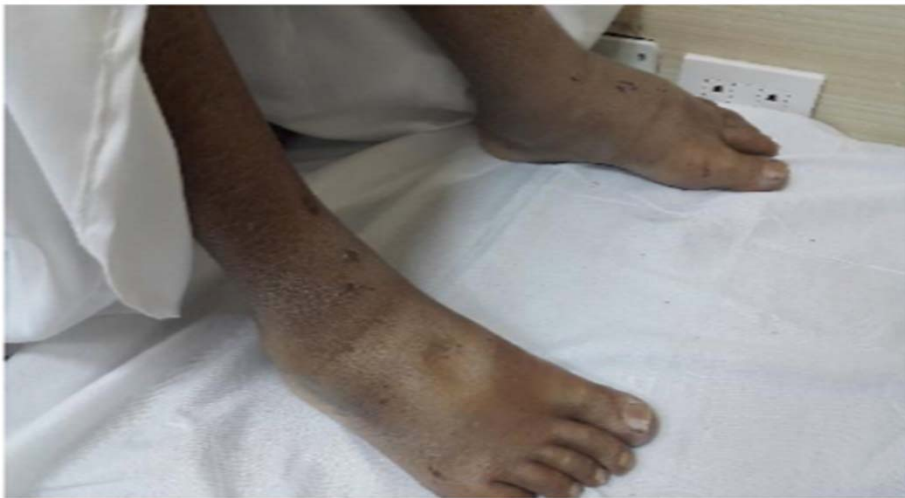In healthy the sound will be muffled but over consolidation or fibrosis it will be heard loudly and clearly.

- ❖ Ask the patient to whisper “one,one,one” while you continue to listen.
- ❖ Ask the patient to say (E) if heard as (A) then this is Aegophony which indicates consolidation.

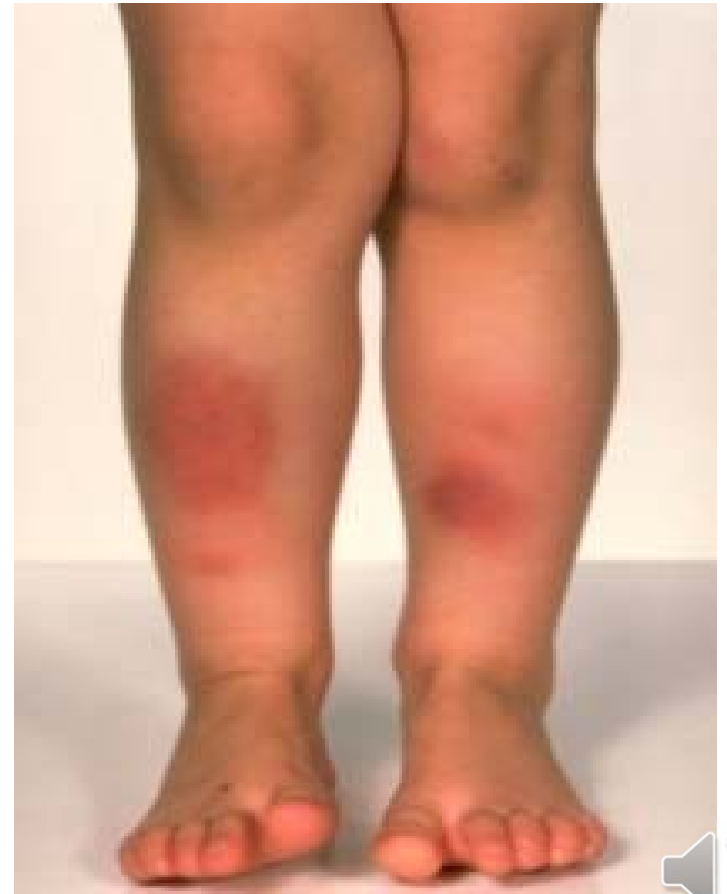

Don't forget to examine;

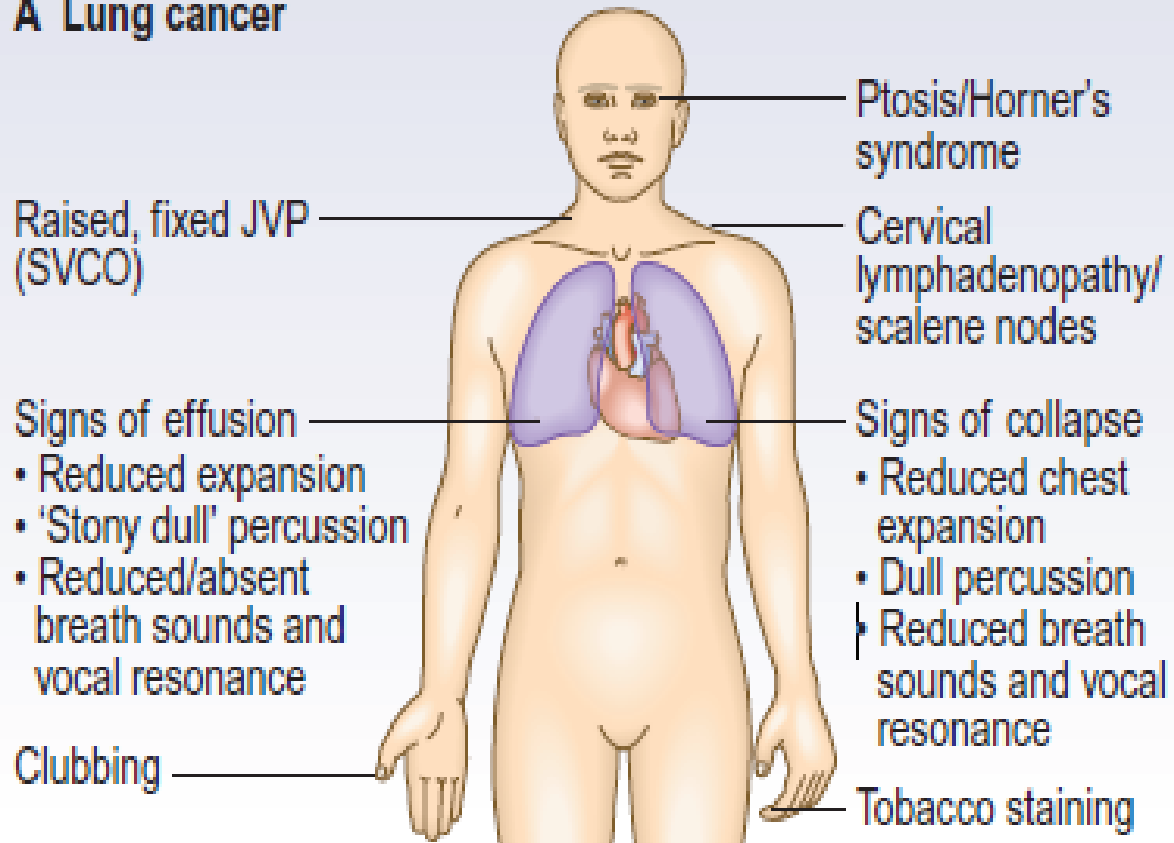
- Pitting edema over the sacrum and lumbar spine
 - Lower limbs for signs of DVT and erythema nodosum
-



Pitting oedema



A Lung cancer



B Asthma

Agitation or drowsiness
(in 'severe asthma')

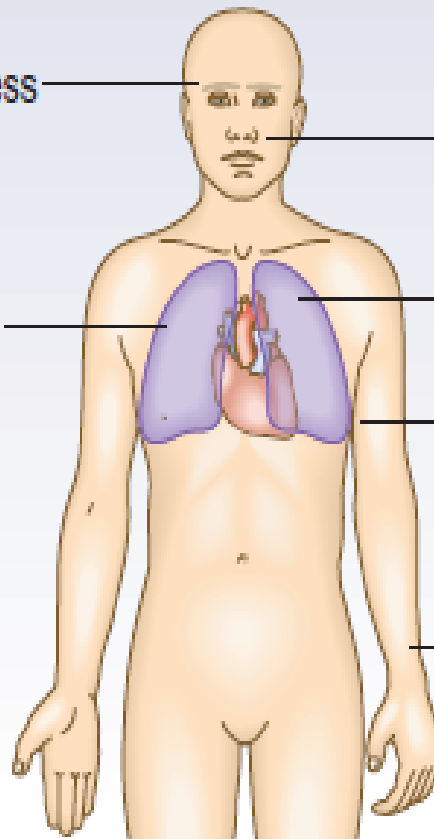
Central cyanosis,
(in 'severe asthma')

Intercostal indrawing
(children)

Wheeze (silent chest
in 'severe asthma')

Hyperinflated chest

Rapid pulse (slow in
'severe asthma')

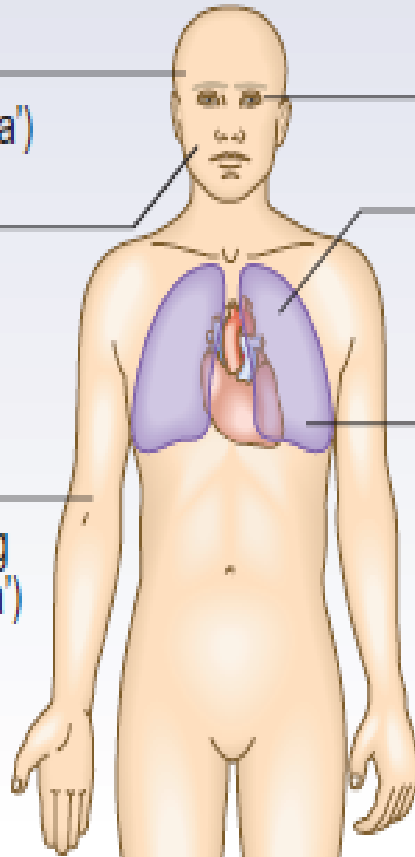


C Pneumonia

Confusion
(in 'severe pneumonia')

Central cyanosis

Hypotension
(diastolic ≤ 60 mmHg
in 'severe pneumonia')



Fever (rigors)

Respiratory rate >30
(in 'severe pneumonia')

Signs of consolidation

- Reduced chest expansion
- Dull percussion
- Bronchial breath sounds \pm pleural rub
- Increased vocal resonance



D Idiopathic pulmonary fibrosis (fibrosing alveolitis)

Central cyanosis

Reduced chest expansion

Fine late inspiratory crackles

Clubbing

Ankle swelling in late stages

Findings in Lung Fibrosis



E Chronic obstructive pulmonary disease

Plethoric (secondary polycythaemia)

Using accessory muscles

Wheeze

Tobacco staining

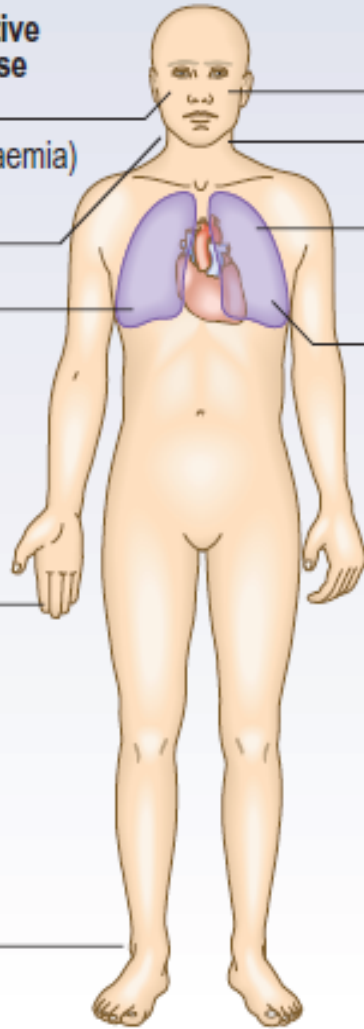
Ankle swelling (cor pulmonale)

Central cyanosis

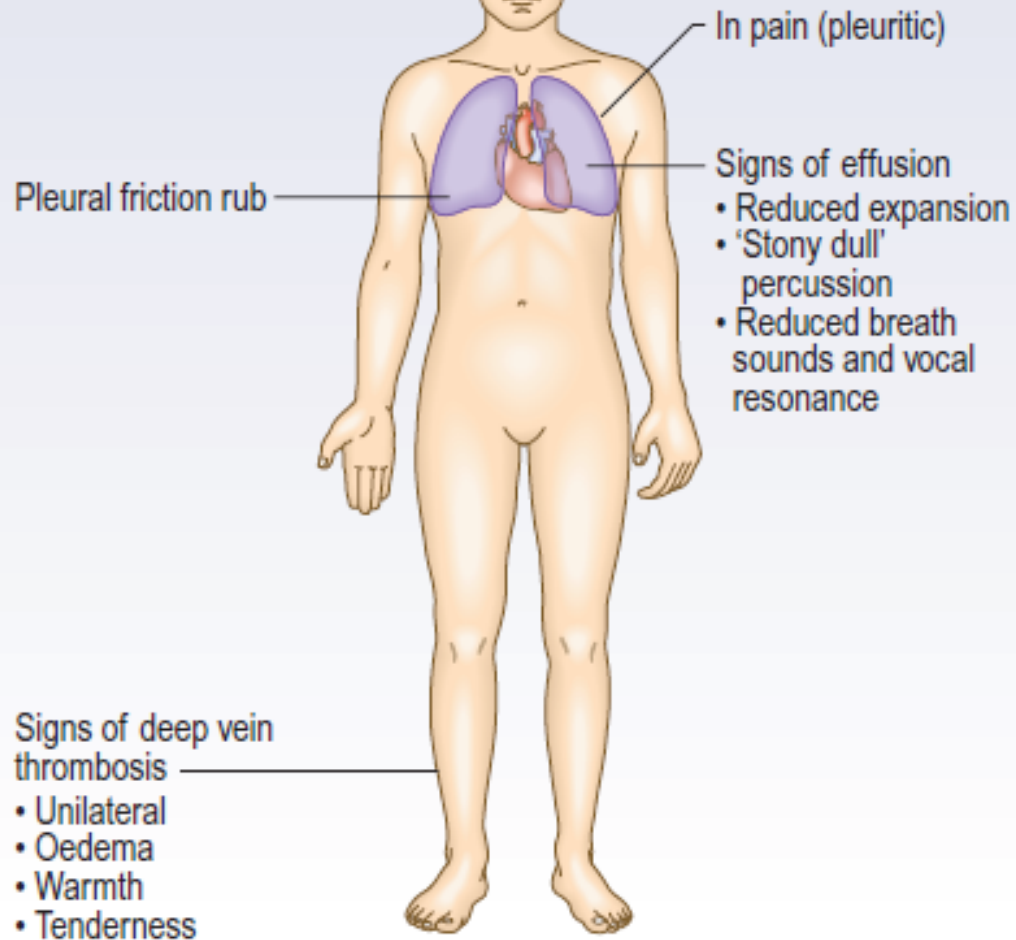
Raised JVP (cor pulmonale)

Hyperinflated 'barrel-shaped' chest

Reduced air entry



F Pulmonary thromboembolism



Thank you

